



IMAGES IN INTENSIVE MEDICINE

Endobronchial actinomycosis

Chih-Jung Chang^{a,b}, Yi-Han Hsiao^{a,b,*}

^a Department of Chest Medicine, Taipei Veterans General Hospital, Taipei, Taiwan

^b School of Medicine, National Yang Ming Chiao Tung University, Taipei, Taiwan

Available online 2 June 2025

A 63-year-old man with bronchiectasis suffered from respiratory failure status post tracheostomy. He experienced sudden massive hemoptysis requiring an emergent bronchoscopy during admission. After removing a bronchial cast formed by coagulated blood (Fig. 1) in bronchi, no active bleeder was found, and vital signs became stable. However, multiple endobronchial necrotic-like masses containing sulfur granules were found in bilateral sub-branches in the lower bronchi (Fig. 2). The pathological report revealed bacterial colonies with Gram-positive filamentous bacilli and cocci (Fig. 3), suggesting a diagnosis of actinomycosis. Surgical intervention was not recommended after multidisciplinary expert discussion due to poor pulmonary function. The patient received prolonged antibiotic treatment and was successfully weaned from the ventilator.

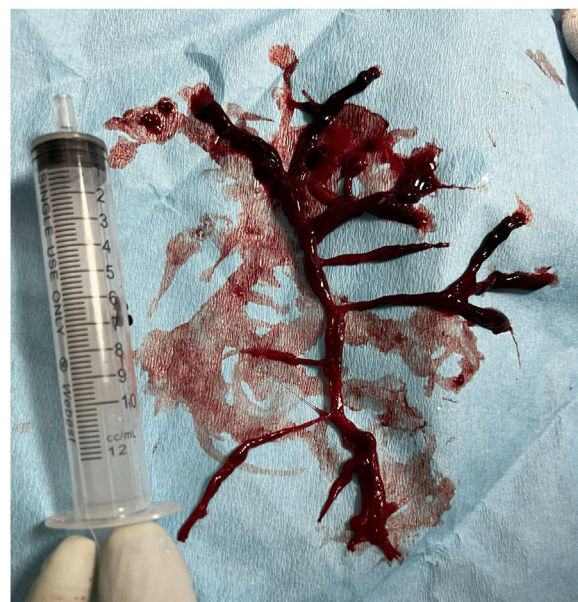

Figure 1

* Corresponding author.

E-mail address: yihanhsiao@gmail.com (Y.-H. Hsiao).

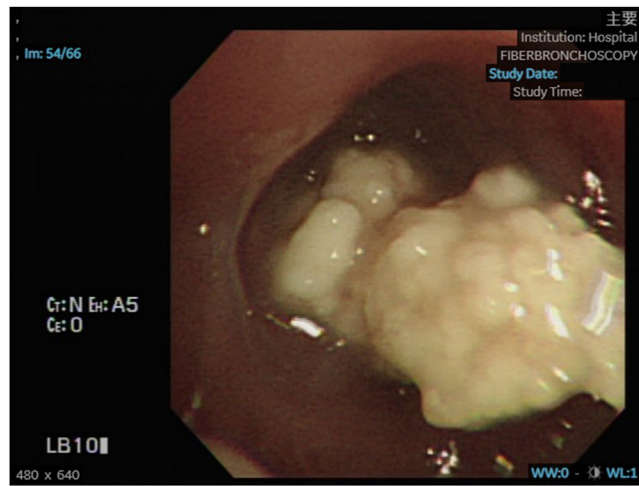


Figure 2

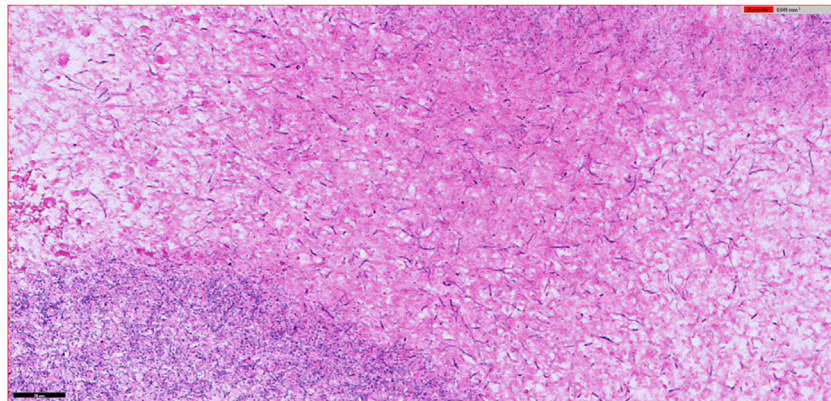


Figure 3

Funding

None.

Declaration of competing interest

None.