

de soporte agresivo, teniendo presente la frecuente reversibilidad de la afectación miocárdica en casos fulminantes, incluyendo las miocarditis asociadas a influenza<sup>2,6,8</sup>.

## Financiación

No hay fuente de financiación para el presente trabajo.

## Conflicto de intereses

Los autores no tienen conflicto de interés en relación con este trabajo.

## Bibliografía

1. Estabragh ZR, Mamas MA. The cardiovascular manifestations of influenza: A systematic review. *Int J Cardiol.* 2013;167:2397–403.
2. Ukimura A, Satomi H, Ooi Y, Kanzaki Y. Myocarditis associated with influenza A H1N1pdm2009. *Influenza Res Treat.* 2012;2012:351979.
3. Ukimura A, Izume T, Matsomuri A. A national survey on myocarditis associated with the 2009 influenza a (H1N1) pandemic in Japan. *Circ J.* 2010;74:2193–9.
4. Felker GM, Boehmer JP, Hruban RH, Hutchins GM, Kasper EK, Baughman KL, et al. Echocardiographic findings in fulminant myocarditis. *J Am Coll Cardiol.* 2000;36:227–32.
5. Muthuri SG, Myles PR, Venkatesan S, Leonardi-Bee J, Nguyen-Van-Tam JS. Impact of neuraminidase inhibitor treatment on

- outcomes of public health importance during the 2009-2010 influenza A(H1N1) pandemic: A systematic review and meta-analysis in hospitalized patients. *J Infect Dis.* 2013;207:553–63.
6. McCarthy RE, Boehmer JP, Hruban RH, Hutchins GM, Kasper EK, Hare JM, et al. Long-term outcome of fulminant myocarditis as compared with acute (nonfulminant) myocarditis. *N Engl J Med.* 2000;342:690–5.
  7. Friedrich MG1, Sechtem U, Schulz-Menger J, Holmvang G, Alakija P, Cooper LT, et al., International Consensus Group on Cardiovascular Magnetic Resonance in Myocarditis. Cardiovascular magnetic resonance in myocarditis: A JACC White Paper. *J Am Coll Cardiol.* 2009;53:1475–87.
  8. Atluri P, Ullery BW, MacArthur JW, Goldstone AB, Fairman AS, Hiesinger W, et al. Rapid onset of fulminant myocarditis portends a favourable prognosis and the ability to bridge mechanical circulatory support to recovery. *Eur J Cardiothorac Surg.* 2013;43:379–82.

R. Martín-Bermúdez\*, A. Martínez-Roldán, J. Jiménez-Jiménez, R. Dusseck-Brutus, M. Porrás-López y J.B. Pérez-Bernal

*Unidad de Gestión Clínica de Cuidados Críticos y Urgencias, Hospital Universitario Virgen del Rocío, Sevilla, España*

\* Autor para correspondencia.

Correo electrónico: [rmartinbermudez@gmail.com](mailto:rmartinbermudez@gmail.com) (R. Martín-Bermúdez).

<http://dx.doi.org/10.1016/j.medin.2014.07.005>

## Cardiac arrest every other day



## Parada cardíaca cada dos días

### Introduction

Right atrial thrombus is well-documented life-threatening complications associated with central venous catheters,<sup>1,2</sup> yet unrecognized due to underreporting in asymptomatic patients and difficult diagnosis. The catheter induced right atrium thrombus has a reported risk of 40% for pulmonary thromboembolism and associated mortality rate as high as 28–31%.<sup>3</sup> Although difficult to diagnose, right atrial thrombus is a complication with deadly consequences, like pulmonary embolus and right heart obstruction, that must be prevented by proper approach and management of the catheter, early clinical suspicion, diagnosis and appropriate intervention.<sup>1</sup> Authors describe management of a 64-year-old man with hemodialysis catheter induced right atrial thrombus, conditioning cardiac arrest and a review of the existing literature.

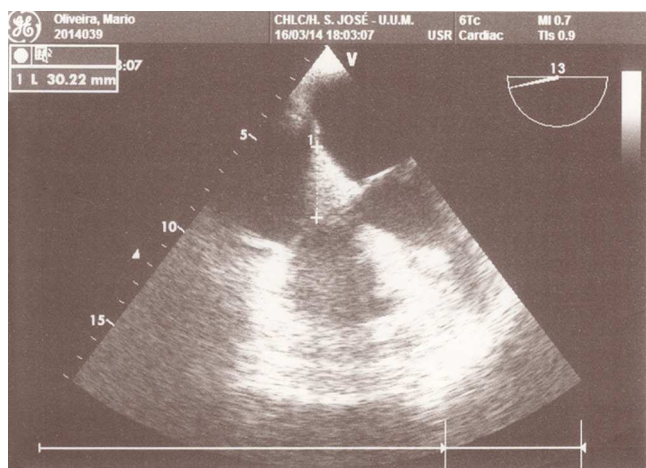
### Case report

A 64-year-old man was admitted to the Emergency Room (ER) in coma with acute respiratory failure. Family described cough and mucous expectoration from a week, without fever. The patient had past medical history of essential

arterial hypertension, type 2 diabetes mellitus, chronic obstructive pulmonary disease (COPD), hypothyroidism, benign prostatic hyperplasia (BPH), lower limbs lymphedema and chronic constipation. Chronic medicated with Perindopril, Furosemide, Metformin, Silodosin, Levothyroxine and Alprazolam.

On hospital admission, patient had Glasgow Score of 8, was immediately intubated and mechanical ventilated. He was hemodynamically stable and pulmonary auscultation had diminished breath sounds on right hemithorax. Arterial blood gas analysis revealed respiratory acidosis (pH 7.28, pO<sub>2</sub> 112 mmHg, pCO<sub>2</sub> 60 mmHg, HCO<sub>3</sub><sup>-</sup> 27.8, lactates 1.11). Laboratory evaluation showed hemoglobin 12.2 g/dl, leukocytes 6.10 × 10<sup>9</sup>/L, neutrophils 67.41%, C-reactive protein (CRP) 165.6 mg/L, D-dimer 2511 mcg/L, platelets 230 × 10<sup>9</sup>/L, INR 1.22, urea 63 mg/dL, creatinine 1.83 mg/dL, potassium 6.6 mEq/L, troponin 0.49 ng/ml, myoglobin 673.8 ng/mL, CK 403 U/L, AST 111 U/L, ALT 35 U/L, LDH 483 U/L. Normal thyroid function. Chest radiograph showed opacity of the right hemithorax. Blunt brain Computerized tomography (CT) – scan. A Chest Angio-CT was performed excluding pulmonary thromboembolism.

Patient was started on empirical antibiotherapy with Amoxicillin and Clavulanic acid for the hypothesis of aspiration pneumonia. He was also started on Acetylsalicylic acid 250 mg 1id, Clopidogrel 75 mg 1id and Enoxaparin 100 mg 2id due to the diagnostic hypothesis of acute coronary syndrome. There was not indication for emergency coronary angiography. Condition progressed to refractory shock with



**Figure 1** Image of the clot in the right atrium seen by transesophageal echocardiography.

development of acute renal failure with oliguria and maintenance of acute respiratory failure. Patient was admitted in an Intensive Care Unit. Resuscitation with aggressive fluid resuscitation and vasopressor support with norepinephrine were started with hemodynamic response. H<sub>2</sub>N<sub>3</sub> virus was isolated and 10 days of treatment with Oseltamivir 150 mg 2id were completed. There were not other isolated agents.

Progressive worsening of the renal function was observed and renal replacement therapy (hemodialysis – HD) started at 14th day. First HD catheter was placed in the right femoral vein and then changed to left femoral vein for infection suspicion. At 27th day of internment a deep venous thrombosis of the left femoral vein involving the HD catheter extremity and of the right femoro-popliteus system was documented and managed with continuous perfusion of unfractionated heparin (UFH), controlled by a PTT monitoring.

Other central venous HD catheter was placed in the right subclavian vein and catheterization progressed uneventfully. At 2nd day of this catheter, 15 min after the initiation of renal replacement technique, patient developed desaturation, hypotension and bradycardia with evolution to cardiac arrest in asystolia, recovered after 2 cycles of advanced life support (ALS). Chest Angio-TC excluded pulmonary thromboembolism. At 3rd day patient was hemodynamically stable under continuous perfusion of norepinephrine but developed supraventricular tachycardia with hemodynamic instability after renal replacement technique was started, which converted to sinus rhythm after synchronized cardioversion (100J). The transthoracic echocardiogram performed did not show any changes. At 4th day, 20 min after the beginning of the renal replacement technique, new cardiac arrest in pulseless electrical activity. A transesophageal echocardiogram (TEE) was performed under ALS and clot in the right atrium (RA) with 30 mm diameter adjacent to the hemodialysis catheter was documented (Fig. 1). It prolapsed into the tricuspid valve, causing obstruction of blood flow to the right ventricle and causing the cardiac arrest.

Fibrinolytic therapy was performed with Alteplase 100 mg and continuous anticoagulation with UFH was maintained. Complete resolution of the clot was documented by TEE at 48 h. After clot resolution, renal replacement therapy resumed on alternate days without complications.

## Discussion

Central venous catheters for renal replacement therapy are widely used in ICU. They have as known complication thrombus formation in right atrium.<sup>4</sup> But it is a rare complication and the literature is scarce for this subject. The reported incidence for catheter-related right atrial thrombosis varies from 2% to 29%.<sup>5</sup> Thrombus formation pathogenesis includes constant motion of the catheter tip, due to the movement of the heart, with friction of the distal catheter end to the endocardium and consequent irritation and damage of the atrial wall, resulting in mural thrombus formation at the contact point.<sup>2,6</sup> In this particular patient with left femoral vein and right femoro-popliteus system thrombosis already documented, clot embolization with starting point in the lower limb venous system is other possible etiology.

Thrombus at the right atrium may cause obstruction to blood flow during renal replacement therapy that can complicate with cardiac arrest, as described in this case report. Immediate TEE performance allowed early diagnosis and timely treatment with resolution of the thrombus. TEE has better sensitivity and specificity when compared to TTE.<sup>7</sup> Diagnosis was achieved only after performing the TEE, even after performing transthoracic echocardiography in the two previous days. Diagnosis confirmation could be made by Cardiac-MRI which allows tissue characterization. It wasn't done in this case by the risk of nephrogenic systemic fibrosis.<sup>7</sup>

A review of literature revealed lack of uniformity in the treatments adopted. Removal of the catheter is the first recommendation but reduction of the risk of serious complications has not been proven.<sup>1</sup> In this particular case, patient had no other available vascular access and the catheter removal could mean the loss of any venous access. Furthermore, Alteplase fibrinolytic therapy was effective in resolving the thrombus but prevented catheter removal, for the hemorrhagic risk. So immediate withdrawal of the catheter was not done. Patient started HD two days after fibrinolysis without complications.

Some authors suggest performing routine transthoracic echocardiography in case of having a hemodialysis catheter for long than 2 weeks, to avoid further lethal complications.<sup>6</sup> However, as already mentioned, the imaging test with higher sensitivity and specificity is transesophageal echocardiography,<sup>7</sup> with the possibility of false negatives in the implementation of transthoracic echocardiography.

## Conflict of interest

The authors declare no conflict of interest.

## Bibliografía

1. Lalor PF, Sutter F. Surgical management of a hemodialysis catheter-induced right atrial thrombus. *Curr Surg.* 2006;63:186–9.
2. Coan KE, O'Donnell ME, Fankhauser GT, Bodnar Z, Chandrasekaran K, Stone WM. Bilateral pulmonary emboli secondary to indwelling hemodialysis reliable outflow catheter. *Vasc Endovascular Surg.* 2013;47:317–9.

3. Ram R, Swarnalatha G, Rakesh Y, Jyostna M, Prasad N, Dakshinamurthy KV. Right atrial thrombus due to internal jugular vein catheter. *Hemodial Int.* 2009;13: 261–5.
  4. Hussain N, Shattuck PE, Senussi MH, Kho EV, Mohammedabdul M, Sanghavi DK, et al. Large right atrial thrombus associated with central venous catheter requiring open heart surgery. *Case Rep Med.* 2012;2012:4. Article ID 501303.
  5. Shah A, Murray M, Nzerue C. Right atrial thrombi complicating use of central venous catheters in hemodialysis. *Int J Artif Organs.* 2004;27:772–8.
  6. Bayón J, Martín M, García-Ruiz JM, Rodríguez C. “We have a tenant” a right atrial thrombus related to a central catheter. *Int J Cardiovasc Imaging.* 2011;27: 5–6.
  7. Lee CU, Wood CM, Hesley GK, Leung N, Bridges MD, Lund JT, et al. Large sample of nephrogenic systemic fibrosis cases from a single institution. *Arch Dermatol.* 2009;145: 1095–102.
- M.S.B. Adriano<sup>a,\*</sup>, V. Mondim<sup>a</sup>, R. Cavaco<sup>b</sup>, N. Germano<sup>b</sup>, Jorge Nunes<sup>b</sup>, L. Bento<sup>b</sup>
- <sup>a</sup> *Centro Hospitalar Lisboa Central, Department of Anaesthesiology, Lisbon, Portugal*  
<sup>b</sup> *Centro Hospitalar Lisboa Central; Department of Intensive Care Medicine – Unidade de Urgência Médica, Lisbon, Portugal*
- \* Corresponding author.  
*E-mail addresses:* [martadriano@hotmail.com](mailto:martadriano@hotmail.com) (M.S.B. Adriano), [vmondim@gmail.com](mailto:vmondim@gmail.com) (V. Mondim), [avelascavaco@gmail.com](mailto:avelascavaco@gmail.com) (R. Cavaco), [nuno.m.germano@gmail.com](mailto:nuno.m.germano@gmail.com) (N. Germano), [jorepo2@gmail.com](mailto:jorepo2@gmail.com) (J. Nunes), [1970bento@gmail.com](mailto:1970bento@gmail.com) (L. Bento).
- <http://dx.doi.org/10.1016/j.medin.2014.08.001>