



SCIENTIFIC LETTERS

Three-stage treatment of late mediastinitis after implantation of left ventricular assist device



Tratamiento en tres fases de mediastinitis retardada después de implantación de un dispositivo para asistencia del ventrículo izquierdo

Dear Editor,

Left ventricular assist device (LVAD) infection is a major cause of re-admission during long-term follow-up and is associated with very high morbidity and mortality. The VAD-related mediastinitis mortality rate is up to 70%.^{1–3} We describe successful three-stage treatment: 1st stage, explantation of the infected device and implantation of peripheral extracorporeal life support (ECLS), followed by surgical toilet of the infected mediastinum employing jet lavage and vacuum drainage; 2nd stage, mobilization of the great omentum and wrapping around the heart including apex; and 3rd stage, implantation of a new LVAD outside of mediastinum and explantation of ECLS (Fig. 1).

A 42-year-old man (175 cm and 110 kg-BSA 2.24m²) with ischemic cardiomyopathy, type 2 diabetes mellitus, arterial hypertension, chronic renal failure (stage III), and paroxysmal atrial fibrillation was supported with Heart Mate III LVAD (Thoratec Corp, Pleasanton, CA) at Deutsches Herzzentrum Berlin.

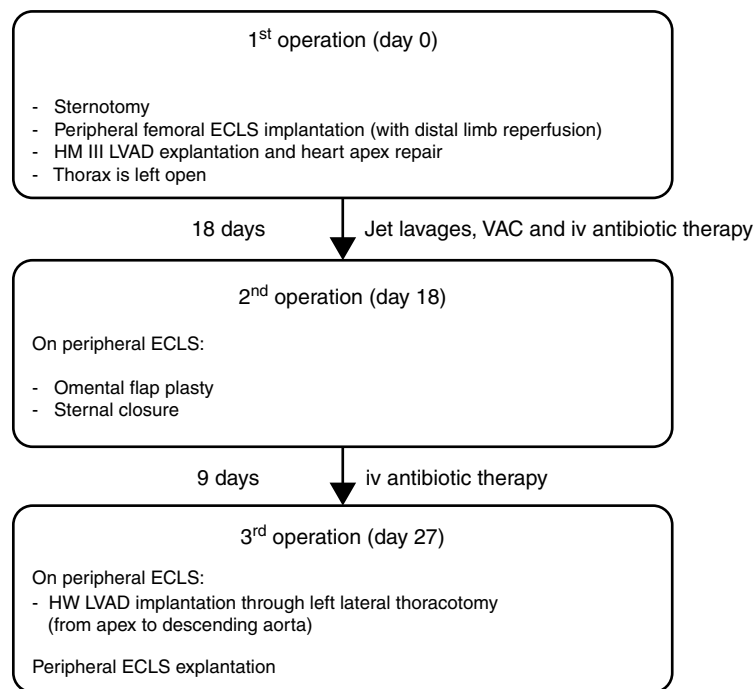
Six months after hospital discharge, the patient presented with a subxyphoidal abscess and signs of systemic infection (white blood cells $12.6 \times 10^9/L$, C reactive protein 24 mg/dl, procalcitonin 23.1 micrograms/L, and body temperature 38.9°C). The exit site of the driveline was completely healed and free of infection. The thoracic CT scan revealed presternal collection of fluid with no evidence of intrathoracic involvement. Over 300 ml of purulence was evacuated during surgical drainage. The cable was involved in the abscess. Additionally, jet lavage was performed with 3 liters of warm 0.9% NaCl solution and a vacuum assisted closure (VAC) system was applied. Systemic antibiotics (fosfomicin and rifampicin) were administered to address methicillin-sensitive *Staphylococcus aureus* (MSSA) isolated from purulent drainage and blood samples obtained at hospital admission. The patient was extubated and orally

fed. The dosage of the antimicrobial therapy was the maximal dose recommended according to the organ function throughout the whole clinical course.

The patient showed clinical improvement with reduction of infection markers and no fever, but, during 3rd VAC exchange, he presented continuous bleeding from the wound originating from the proximal part of the cable exiting. Loosening of the apical fixation ring connection was suspected. Ten days after hospital admission, re-sternotomy was performed. The apical cuff of the device was found to be partially detached from the apex causing bleeding. Macroscopic evidence of infection was found. Peripheral ECLS was implanted, including distal leg perfusion, and all the components of the LVAD were explanted. The apex of the heart was repaired with prolene sutures and a pericardial patch. In order to achieve full sterilization of the thorax, the sternum was left open and treated with repeated jet lavage and VAC. Systemic multidrug intravenous antibiotic therapy, including gentamicin, flucloxacillin, and linezolid, was administered for several weeks. Fourteen days after surgery limb ischemia occurred and required surgical treatment including thrombectomy and cannulation of the contralateral femoral artery. Already after few days after the first operation the wound samples were sterile in the absence of bacteremia, therefore, after 18 days of ECLS, omental flap plasty and sternal closure were performed.

One week later and 27 days after removal of infected LVAD, with the patient breathing spontaneously on ECLS and without signs of systemic infection (white blood cells $7 \times 10^9/L$, C reactive protein 16.6 mg/dl, procalcitonin 0.31 micrograms/L, and body temperature 37.3°C) he underwent re-implantation of an LVAD (HVAD HeartWare International, Inc., Framingham, MA) from apex to descending aorta through left lateral thoracotomy, as described previously.^{4,5} The new driveline course does not intersect with the previous one and has a new exit site; in the same session the ECLS was explanted.

The postoperative course was complicated by pump thrombosis on day 7 with subsequent pump exchange as described,⁶ and by groin infection treated with surgical revision and VAC therapy. The patient was stable, without signs of systemic infection and partially rehabilitated. Antibiotic therapy continued although blood cultures were negative, while intraoperative samples from the left groin identified *Candida glabrata* and *Klebsiella pneumoniae*. According to the antibiogram, rifampicin and flucloxacillin



HM III – HeartMate III (Thoratec corp, Pleasanton, CA); LVAD – left ventricular assist device; VA ECMO – venoarterial ECMO; VAC – vacuum assisted closure; HW – HeartWare HeartWare International, Inc., Framingham, MA; iv – intravenous

Figure 1 Outline of the three-stage treatment.

were discontinued (total duration of therapy was 43 and 36 days, respectively), and caspofungin and ceftazidime were started. Unfortunately, after further 35 days of hospitalization the patient died due to sudden intracerebral bleeding.

If the pump is infected, surgical cleaning of the mediastinum, debridement and vacuum treatment and, finally, transposition of the great omentum with wrapping around the pump have been successfully used in our institution and also described by other authors.⁷⁻¹⁰ Retention of potentially infected inflow or outflow cuffs could contribute to infection recurrence, and apex involvement with loosening of the fixation ring is still an unsolved problem. Severe pump infection may be controlled by device explantation if the cardiac function has fully recovered,^{11,12} wrapping with the great omentum⁷⁻¹⁰ or by pump exchange.¹³ However, in a devastating case of apex infection with bleeding, switching the inflow cannula from apex to left atrium is an option. In our case temporary implantation of the Berlin Heart Excor (Berlin Heart AG, Berlin, Germany) or Levitronix Centrimag (Levitronix, Framingham, MA) from left atrium to ascending aorta¹⁴ would bring foreign material into the infected mediastinum. Connection to the descending aorta may lead to infection of the left pleural space precluding the implantation of the long-term pump through a left lateral thoracotomy. Therefore we decided to use peripheral ECLS to avoid opening the pleural space or introducing any additional cannula in or close to the infected situs. The thorax was free from any MCS components and the choice to leave it open allowed application of all topical treatments in addition to iv antimicrobial drugs.

For ECLS, cannulation of the subclavian artery and jugular vein to allow better mobilization of the patient would also have been an option.

It is important that the new pump does not come into contact with the previously infected tissue – in the present case the new pump was implanted, with new access to the thorax, 9 days after the omentum was wrapped around the sterile apex acting as a biological barrier to infection.

In conclusion, pump infection with apex involvement is rare but can be disastrous. A staged surgical approach including complete removal of infected foreign material, sterilization of the wound by surgical debridement and VAC, closure of the wound with the highly immune competent great omentum and, finally, re-implantation of an LVAD outside the infected field may be effective.

Conflicts of interests and source of funding

No conflicts of interest. The work was supported by departmental funds

References

- Hannan MM, Husain S, Mattner F, Danziger-Isakov L, Drew RJ, Corey GR. International Society for Heart and Lung Transplantation. Working formulation for the standardization of definitions of infections in patients using ventricular assist devices. *J Heart Lung Transplant.* 2011;30:375–84.
- Zierer A, Melby SJ, Voeller RK, Guthrie TJ, Ewald GA, Shelton K, et al. Late-onset driveline infections: the Achilles' heel of prolonged left ventricular assist device support. *Ann Thorac Surg.* 2007;84:515–20.

3. Jorde UP, Kushwaha SS, Tatooles AJ, Naka Y, Bhat G, Long JW, et al. Clinical Investigators. Results of the destination therapy post-food and drug administration approval study with a continuous flow left ventricular assist device: a prospective study using the INTERMACS registry (Interagency Registry for Mechanically Assisted Circulatory Support). *J Am Coll Cardiol*. 2014;63:1751-7.
4. Krabatsch T, Drews T, Potapov E, Weng Y, Pasic M, Hetzer R. Different surgical strategies for implantation of continuous-flow VADs-Experience from Deutsches Herzzentrum Berlin. *Ann Cardiothorac Surg*. 2014;3:472-4.
5. Jurmann MJ, Weng Y, Drews T, Pasic M, Henning E, Hetzer R. Permanent mechanical circulatory support in patients of advance age. *Eur J Cardiothorac Surg*. 2004;25:610-8.
6. Potapov EV, Stepanenko A, Kaufmann F, Henning E, Vierecke J, Lehmkuhl E, et al. Thrombosis and cable damage in the HeartWare pump: clinical decisions and surgical technique. *ASAIO J*. 2013;59:37-40.
7. Vierecke J, Stepanenko A, Potapov E, Krabatsch T, Hetzer R. Successful treatment of deep sternal wound infection after permanent LVAD implantation using omental flap transposition. *Thorac Cardiovasc Surg*. 2010;58:MP6.
8. Krabatsch T, Hetzer R. Poststernotomy mediastinitis treated by transposition of the greater omentum. *J Card Surg*. 1995;10:637-43.
9. Rodriguez LE, Bruckner BA, Loebe M. Omental flap for treatment of mediastinitis post-left ventricular assist device implantation. *Artif Org*. 2013;37:1081-2.
10. Nelson JA, Shaked O, Fischer JP, Mirzabeigi MN, Jandali S, Kovach SJ, et al. Complex wound management in ventricular assist device (VAD) patients: the role of aggressive debridement and vascularized soft tissue coverage. *Ann Plast Surg*. 2014;73 Suppl. 2:S165-70.
11. Pan S, Aksut B, Wever-Pinzon OE, Rao SD, Levin AP, Garan AR, et al. Incidence and predictors of myocardial recovery on long-term left ventricular assist device support: Results from the united network for organ sharing database. *J Heart Lung Transplant*. 2015;34:1624-9, pii: S1053-2498(15)01379-0.
12. Koborzan MR, Rodríguez-Castro D, Carrió ML, Torrado H, Farrero E, Ventura JL. First case in Spain of a permanent ventricular assist device: control in the intensive care unit. *Med Intensiva*. 2013;37:618-9.
13. Levy DT, Guo Y, Simkins J, Puius YA, Muggia VA, Goldstein DJ. Left ventricular assist device exchange for persistent infection: a case series and review of the literature. *Transpl Infect Dis*. 2014;16:453-60.
14. Gregoric ID. Exchange techniques for implantable ventricular assist devices. *ASAIO J* 2008. 2008;54:14-9.

A.M. Scandroglio^a, E. Potapov^b, M. Pieri^{a,*}, G. Arlt^b, V. Falk^b, T. Krabatsch^b

^a Department of Anesthesia and Intensive Care, IRCCS San Raffaele Scientific Institute, Via Olgettina 60, 20132 Milan, Italy

^b Department for Cardiothoracic and Vascular Surgery, Deutsches Herzzentrum Berlin, Augustenburger Platz 1, D-13353 Berlin, Germany

* Corresponding author.

E-mail address: pieri.marina@hsr.it (M. Pieri).

<http://dx.doi.org/10.1016/j.medin.2016.01.005>

Primer caso de shock séptico por *Streptococcus suis* de posible etiología alimentaria en España



First case in Spain of septic shock by *Streptococcus suis* possible food-borne

Sr. Director:

Streptococcus suis (*S. suis*) es un patógeno humano, emergente, considerado una zoonosis por exposición a cerdos, siendo la meningitis su principal manifestación. Es la causa más prevalente de meningitis en Vietnam, la segunda en Tailandia y la tercera en Hong Kong¹⁻³. Puede causar sepsis y shock tóxico estreptocócico (SST)⁴.

En Europa supone el 8,5% de los casos presentados a nivel mundial⁵. En España no es una enfermedad declarable. Hay casos esporádicos y el primero data de Madrid en 1994, presentándose como bacteriemia y sacroileitis; 30 años después del primer caso mundial. Desde entonces se han descrito 19 casos sin seguir ninguna distribución geográfica ni climatológica que sí aparece en otros estudios^{3,6}.

En humanos, el serotipo 2 es el más frecuente seguido del 14. En España, el serotipo predominante en los cerdos es el 9, seguido del 2, 7, 8 y 3, aunque en las infecciones solo se ha demostrado el serotipo 2⁷.

Nuestro caso trata de un varón de 53 años, ex-fumador, ex-adicto a drogas por vía parenteral, ex-alcohólico, con infección pasada por hepatitis B y C, VIH negativo, esófago de Barret y esplenectomizado. Criador de cerdos. Ingresó en urgencias por cuadro clínico de 2 h de evolución caracterizado por mareos, epigastralgia y deposiciones diarreicas. A su llegada TA: 89/68 mmHg, FC: 126 lpm, T.^a: 38,9 °C, saturación de O₂: 94%, APACHE II: 33. Al examen físico, está obnubilado, con signos de hipoperfusión periférica, sin apreciarse lesiones dérmicas. Se inicia tratamiento con sueroterapia, se extraen hemocultivos, y se pauta piperacilina/tazobactam empírico. Ingresó en unidad de cuidados intensivos (UCI) en estado de shock. Se inicia resucitación con fluidoterapia y noradrenalina a dosis medias (hasta 1,5 µg/kg/min). Se cateteriza vía venosa central, y se coloca catéter PICCO para monitorización hemodinámica. Análiticamente: Hb: 13,3 g/dl, leucopenia (1.720 leucocitos/µl) y trombocitopenia (24.000/µl), glucosa: 91 mg/dl, urea: 51 mg/dl, creatinina: 1,57 mg/dl, PCR: 4,5 mg/l, procalcitonina: 13,52 ng/ml y lactato: 5,6 mmol/l. Actividad de protrombina: 17%, T cefalina > 3 s, INR 4,7. Fibrinógeno < 4. Ante su empeoramiento se amplía cobertura antibiótica con meropenem + vancomicina + amikacina y caspofungina. Se realiza TC abdomino-pélvico encontrando imagen sugestiva de ileocolitis inflamatoria/infecciosa. En horas posteriores al ingreso inicia paraparesia con sensibilidad conservada de predominio proximal y reflejos osteotendinosos abolidos. Se realiza TC craneal donde se objetivan focos hemorrágicos