

aparecer y ocasionalmente revertir a ritmo sinusal de forma espontánea, por lo que existe la posibilidad de que, coincidentemente a la administración de propofol, la arritmia hubiese finalizado de manera fortuita. Por último, la administración previa de amiodarona en los casos de FA podría haber influido en la reversión tras la administración de propofol, si bien inicialmente (tras la dosis total de 1.200 mg de amiodarona en 24 h) no logró el objetivo del control del ritmo.

A modo de conclusión, y en base a la evidencia disponible, los autores creemos que deberían plantearse estudios prospectivos y comparativos que evalúen la eficacia real del fármaco en contexto de taquiarritmias supra-ventriculares estables que no responden a otras medidas farmacológicas.

Conflicto de intereses

Los autores declaran que no existe ningún conflicto de intereses ni fuentes de financiación provenientes de entidades públicas o privadas, de investigación o fundaciones.

Bibliografía

1. Reves JG, Glass PSA, Lubarsky DA, McEvoy MD, Martinez-Ruiz R. Intravenous Anesthetics. En: Miller RD, editor. *Miller's Anesthesia*. 7.^a edición Elsevier España; 2009. p. 719–68.
2. Vasileiou I, Xanthos T, Koudouna E, Perrea D, Klonaris C, Katsargyris A, et al. Propofol: A review of its non-anaesthetic effects. *Eur J Pharmacol*. 2009;605:1–8.
3. Warpechowski P, dos Santos AT, Pereira PJ, de Lima GG. Effects of propofol on the cardiac conduction system. *Rev Bras Anesthesiol*. 2010;60:438–44.

4. Yang L, Liu H, Sun HY, Li GR. Intravenous anesthetic propofol inhibits multiple human cardiac potassium channels. *Anesthesiology*. 2015;122:571–84.
5. Cervigoín R, Moreno J, Pérez-Villacastín J, Castells F. Profound sedation with propofol modifies atrial fibrillation dynamics. *Pacing Clin Electrophysiol*. 2013;36:1176–88.
6. Kannan S, Sherwood N. Termination of supraventricular tachycardia by propofol. *Br J Anaesth*. 2002;88:874–5.
7. Magaldi M, Fontanals J, Pérez J. Sinusal reversion of atrial flutter after intravenous propofol administration. *Med Intensiva*. 2014;38:127–8.
8. Choi EK, Jee DL. Conversion of supraventricular arrhythmia to normal rhythm by propofol and remifentanyl: Three cases report. *Korean J Anesthesiol*. 2014;66:244–7.
9. Miró O, de la Red G, Fontanals J. Cessation of paroxysmal atrial fibrillation during acute intravenous propofol administration. *Anesthesiology*. 2000;92:910.
10. Win NN, Fukayama H, Kohase H, Umino M. The different effects of intravenous propofol and midazolam sedation on hemodynamic and heart rate variability. *Anesth Analg*. 2005;101:97–102.

J. Montero-Tinnirello*, M. Magaldi, J. Fontanals, P. Masgoret y J.C. Bravo

Servicio de Anestesiología, Reanimación y Tratamiento del Dolor, Hospital Clínic, Barcelona, España

* Autor para correspondencia.

Correo electrónico: jamontero@clinic.cat (J. Montero-Tinnirello).

<http://dx.doi.org/10.1016/j.medin.2016.10.002>
0210-5691/

© 2016 Elsevier España, S.L.U. y SEMICYUC. Todos los derechos reservados.

Effect of single-dose of tolvaptan in neurocritical patients with hyponatremia due to syndrome of inappropriate antidiuretic hormone secretion



Efecto de una dosis única de tolvaptán en pacientes neurocríticos con hiponatremia debido a SIADH

Dear Editor,

Hyponatremia constitutes the most common electrolyte abnormality found in patients with acquired brain injury,^{1,2} being present in up to 20% of patients with traumatic brain injury (TBI) and 50% of patients with subarachnoid hemorrhage (SAH).¹

In most cases, the underlying cause of euvoletic hyponatremia in brain injured patients is the syndrome of inappropriate secretion of antidiuretic hormone (SIADH).³ In this syndrome, an abnormal water/sodium handling is associated with an osmotic gradient that promotes the

shift of water into brain cells, thereby worsening cerebral edema and resulting in deteriorating neurological condition with seizures, coma, increased intracranial pressure and eventually death.^{1,2,4} An appropriate correction of hyponatremia was associated with increased survival.⁵

In the recent years, tolvaptan, an orally active, selective, nonpeptide antagonist that blocks arginine vasopressin from binding to V2 receptors of the distal nephron inducing the excretion of electrolyte-free water (the so-called "aquaretic effect") showed its effectiveness in the treatment of hyponatremia in randomized controlled trials,⁶ but its use in neurocritically ill patients remains limited.² Concerns with the potential risk of overcorrection and secondary osmotic demyelinating syndrome (ODS) arose, although the incidence of overcorrection can be even higher when using the commonly accepted 3% hypertonic saline.⁷ When tolvaptan is used, initial doses of 7.5 or 15 mg are recommended.⁸ Some authors recommend its use as a treatment of SIADH induced hyponatremia when first line therapies including fluid restriction have failed.⁹

In this report, we studied the effects of a single dose of tolvaptan in hyponatremic neurocritically ill patients.

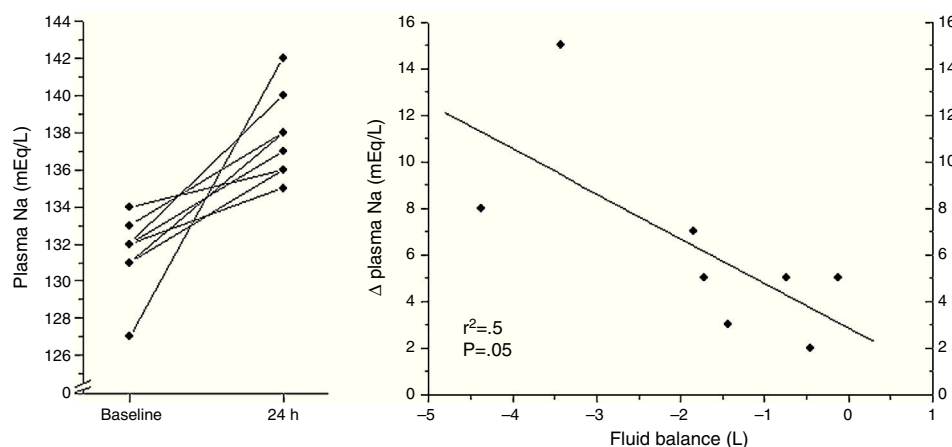


Figure 1 Linear regression analysis of 24h fluid balance and Δ natremia after the first dose of tolvaptan.

The study was approved by our Hospital Research Committee. The need of informed consent was waived due to the descriptive and retrospective nature of the study.

All patients fulfilled the following definition of SIADH¹:

- Plasma sodium < 135 mEq/L
- Plasma osmolality < 280 mOsm/kg of water
- Urine osmolality > 100 mOsm/kg of water
- Urine sodium > 40 mmol/L
- Normal thyroid and adrenal function
- Clinical euvolemia or hypervolemia
- Absence of recent diuretics use

Overcorrection was defined when the Δ natremia was >8 mEq/L/24h.¹

We retrospectively analyzed the effect on the sodium levels and fluid balance in the first 24h after tolvaptan was given. Quantitative data were reported as median (Interquartile Range (IQR) 25–75) and categorical data as number and percentage. Differences between natremia were compared using Mann–Whitney–Wilcoxon test and the association between 24h fluid balance and Δ natremia using linear regression. A value of $p < 0.05$ was considered significant. Statistical analysis was performed with SPSS® 20 (IBM Corporation 2011).

Eight neurocritically ill patients admitted to our ICU fulfilled the above mentioned criteria of SIADH. During their ICU stay, all patients developed hyponatremia and were unsuccessfully treated with oral sodium chloride and 3% hypertonic saline. In such cases, an initial dose of 7.5 mg tolvaptan was given in the morning shift (in one patient 15 mg were administered). Of note, all patients increased their sodium levels and even in 3 patients (37.5%) no additional doses were deemed necessary. Only one patient (12.5%) presented overcorrection requiring treatment with intravenous dextrose and parenteral desmopressin. This patient received a 15 mg initial dose and had risk factors for ODS such as advanced liver disease and alcoholism. No clinical features of ODS were observed in the follow up.

Baseline and clinical data in response to the administration of tolvaptan in the eight patients analyzed

are shown (Table 1). A moderate association between Δ Natremia and 24h fluid balance was found ($p = 0.05$) (Fig. 1).

Our results showed that a single 7.5 mg dose of tolvaptan was effective and safe in the treatment of hyponatremia due to SIADH in neurocritically ill patients. Some issues must be taking into consideration when evaluating our results:

Tolvaptan resulted in an increase of sodium levels in all patients. The effect of a single dose of tolvaptan was enough to solve the hyponatremia in some cases, therefore minimizing the cost of the therapy. Follow up doses were used in 5 patients, when natremia decreased after the initial 48 h. An initial increase lasting 48 h has been previously described.²

Due to the etiology of severe injury, our patients had limited access to water. Unlimited access to water was deemed mandatory to avoid secondary hypovolemia.¹⁰ We believe that in the ICU setting and with close monitoring of fluid balance and sodium levels, such requirement should not be considered necessary.

Tolvaptan was safe at the 7.5 mg dose in all cases. The only episode of overcorrection occurred with a 15 mg dose in a patient with additional risk factors for overcorrection and ODS.¹¹ Related factors include advanced liver disease, malnourishment, hypophosphatemia, hypokalemia, etc.¹¹ We would recommend using the 7.5 mg dose for initiating tolvaptan in neurocritically ill patients. As stated, median Δ Natremia was 5 (4–8) mEq/24h in our sample. Moreover, we defined overcorrection as Δ natremia > 8 mEq/L/24h, but some authors would even accept Δ natremia 12 mEq/L/24h safe in this setting.

The main limitation of this preliminary study is the retrospective and observational design. In addition, the limited number of patients generates weakness in the linear regression analysis due to extreme values and precludes more complex analysis.

In conclusion, in neurocritically ill patients, a low dose of 7.5 mg of tolvaptan was effective and safe in the treatment of hyponatremia due to SIADH. Future studies will determine its exact role in the management of hyponatremia in the whole ICU population. A prospective comparison with 3% hypertonic saline is necessary.

Table 1 Baseline and clinical data of the eight patients studied.

Patient number	Diagnosis	Gender	Age (years)	Day	Natremia before tolvaptan	Natremia 24 h after tolvaptan	Δ Natremia 24 h	Natremia 48 h after tolvaptan	24 h fluid balance (ml)	Follow up doses
1	ICH	Male	45	15	132	135	3	135	-1440	Yes
2*	ICH	Female	55	11	127	142	15	139	-3425	No
3	TBI	Female	45	12	131	137	7	137	-1850	Yes
4	SAH	Male	48	21	132	138	5	136	-122	Yes
5	SAH	Female	57	8	133	138	5	136	-744	Yes
6	Cerebral abscess	Male	28	30	132	140	8	140	-4372	No
7	SAH	Male	50	19	131	136	5	137	-1726	No
8	TBI	Male	29	25	134	136	2	136	-456	Yes
Median (IQR)			46 (33-54)	17 (11-24)	132 (131-133)	138 (136-140)	5 (4-8)	136 (136-138)	-1600 (-3000 to -500)	

ICH: intracerebral hemorrhage; TBI: traumatic brain injury; SAH: subarachnoid hemorrhage.
* Means that this patient received a single 15 mg-dose.

Conflict of interest

Dr. Llopart-Pou declares having received honoraria from Otsuka for participating in a consensus document in the management of hyponatremia in critically ill patients.

Dr. Pérez-Bárcena, Novo and Raurich declare no financial disclosure.

Bibliografía

1. Kleindienst A, Hannon MJ, Buchfelder M, Verbalis JG. Hyponatremia in neurotrauma: the role of vasopressin. *J Neurotrauma*. 2016;33:615-24.
2. Jeon SB, Choi HA, Lesch C, Kim MC, Badjatia N, Claassen J, et al. Use of oral vasopressin V2 receptor antagonist for hyponatremia in acute brain injury. *Eur Neurol*. 2013;70:142-8.
3. Hannon MJ, Finucane FM, Sherlock M, Agha A, Thompson CJ. Clinical review: disorders of water homeostasis in neurosurgical patients. *J Clin Endocrinol Metab*. 2012;97:1423-33.
4. Giuliani C, Peri A. Effects of hyponatremia on the brain. *J Clin Med*. 2014;3:1163-77.
5. Corona G, Giuliani C, Verbalis JG, Forti G, Maggi M, Peri A. Hyponatremia improvement is associated with a reduced risk of mortality: evidence from a meta-analysis. *PLOS ONE*. 2015;10:e0124105.
6. Schrier RW, Gross P, Gheorghide M, Berl T, Verbalis JG, Czerwiec FS, et al., SALT Investigators. Tolvaptan, a selective oral vasopressin V2-receptor antagonist, for hyponatremia. *N Engl J Med*. 2006;355:2099-112.
7. Verbalis JG, Greenberg A, Burst V, Haymann JP, Johansson G, Peri A, et al. Diagnosing and treating the syndrome of inappropriate antidiuretic hormone secretion. *Am J Med*. 2016;129:537.e9-23.
8. Verbalis JG, Goldsmith SR, Greenberg A, Korzelius C, Schrier RW, Sterns RH, et al. Diagnosis, evaluation, and treatment of hyponatremia: expert panel recommendations. *Am J Med*. 2013;126 10 Suppl. 1:S1-42.
9. Runkle I, Villabona C, Navarro A, Pose A, Formiga F, Tejedor A, et al., European Hyponatremia Network. The treatment of hyponatremia secondary to the syndrome of inappropriate antidiuretic hormone secretion. *Med Clin (Barc)*. 2013;141:507.e1-10.
10. http://www.ema.europa.eu/docs/es_ES/document_library/EPAR_-_Product_Information/human/000980/WC500048716.pdf [accessed 14.10.16].
11. Kleinschmidt-Demasters BK, Rojiani AM, Filley CM. Central and extrapontine myelinolysis: then...and now. *J Neuropathol Exp Neurol*. 2006;65:1-11.

J.A. Llopart-Pou^{a,b,*}, J. Pérez-Bárcena^{a,b}, M. Novo^a, J.M. Raurich^a

^a Servei de Medicina Intensiva, Hospital Universitari Son Espases, Palma de Mallorca, Spain

^b Instituto de Investigación Sanitaria de Palma (IdISPa), Palma de Mallorca, Spain

* Corresponding author.

E-mail address: juanantonio.llopart@ssib.es (J.A. Llopart-Pou).

<http://dx.doi.org/10.1016/j.medin.2016.11.007>
0210-5691/

© 2016 Elsevier España, S.L.U. y SEMICYUC. All rights reserved.