

muestran la eficacia del tratamiento esteroideo sistémico o inhalado⁸, siendo preciso ocasionalmente recurrir a técnicas broncoscópicas para mantener la permeabilidad de la vía aérea^{9,10}.

El caso que presentamos resulta insólito por la presentación clínica tan dramática, por lo excepcional que resulta que la OVAC sea el inicio de la EII, y por la oportunidad de aplicar ECMO, permitiendo el rescate terapéutico en un caso que en otras circunstancias habría tenido un final dramático. Es el primer caso comunicado de rescate con ECMO³ sin diagnóstico previo, con imposibilidad para la ventilación y shock obstructivo con parada cardíaca.

Bibliografía

1. Al-Qadi MO, Artenstein AW, Braman SS. The "forgotten zone": Acquired disorders of the trachea in adults. *Respir Med.* 2013;107:1301–13.
2. Miller RD, Hyatt RE. Obstructing lesions of the larynx and trachea: Clinical and physiologic characteristics. *Mayo Clinic Proc.* 1969;44:145–61.
3. Willms DC, Mendez R, Norman V, Chammans JH. Emergency bedside extracorporeal membrane oxygenation for rescue of acute tracheal obstruction. *Respir Care.* 2012;57:646–9.
4. Kraft SC, Earle RH, Roesler M, Esterly JR. Unexplained bronchopulmonary disease with inflammatory bowel disease. *Arch Intern Med.* 1976;136:454–9.
5. Vennera MC, Picado C. Manifestaciones pulmonares de las enfermedades inflamatorias intestinales. *Arch Bronconeumol.* 2005;41:93–8.
6. Higenbottam T, Cochrane GM, Clark TJ, Turner D, Millis R, Seymour W. Bronchial disease in ulcerative colitis. *Thorax.* 1980;35:581–5.

7. Papanikolaou I, Kagouridis K, Papiris SA. Patterns of airway involvement in inflammatory bowel diseases. *World J Gastrointest Pathophysiol.* 2014;5:560–9.
8. Park S, Park J, Kim H-K, Kim JY, Hur SC, Lee JH, et al. Tracheal involvement in Crohn disease: The first case in Korea. *Clin Endosc.* 2016;49:202–6.
9. Wilcox P, Miller R, Miller G, Heath J, Nelems B, Muller N, et al. Airway involvement in ulcerative colitis. *Chest.* 1987;92:18–22.
10. Plataki M, Tzortzaki E, Lambiri I, Giannakaki E, Ernst A, Siafakas NM. Severe airway stenosis associated with Crohn's disease: Case report. *BMC Pulm Med.* 2006;6:7.

M. Ramírez-Romero^{a,*}, B. Hernández-Alonso^a,
C. García-Polo^b, A.J. Abalde-Bechiarelli^c,
A. Garrino-Fernández^a y A. Gordillo-Brenes^a

^a Servicio de Medicina Intensiva, Hospital Universitario Puerta del Mar, Cádiz, España

^b Servicio de Neumología, Hospital Universitario Puerta del Mar, Cádiz, España

^c Servicio de Aparato Digestivo, Hospital Universitario Puerta del Mar, Cádiz, España

* Autor para correspondencia.

Correo electrónico:

miguel.ramirez.romero.1979@gmail.com

(M. Ramírez-Romero).

<https://doi.org/10.1016/j.medin.2017.04.008>
0210-5691/

© 2017 Elsevier España, S.L.U. y SEMICYUC. Todos los derechos reservados.

Near fatal bronchospasm and bradycardia after carbetocin administration



Broncoespasmo y bradicardia grave posterior a la administración de carbetocina

Dear Editor,

Uterotonics are widely used as prophylactic and therapeutic drugs for uterine atony, the major cause of direct maternal mortality due to postpartum hemorrhage.^{1,2} Carbetocin [1-deamino-1-carba-2-tyrosine-(0-methyl)-oxytocin], a synthetic oxytocin analogue effective for treating and preventing post-partum hemorrhage, increases intracellular calcium, stimulates myosin phosphorylation and contraction in uterine smooth muscle cells; has an onset of action of 2 min and a plasma half-life six to seven times longer than oxytocin. It can be administered by intravenous (IV) and intramuscular route. Despite its safety profile, chest tightness, palpitations and breathing discomfort are frequently reported after its administration,^{3,4,5} therefore prescription information and some reviews recommend caution when it is administered to patients with asthma or cardiovascular

disease. Herein we report a case of near fatal bronchospasm and bradycardia after carbetocin administration.

A 22 years-old pregnant female, with a past history of a ruptured ectopic tubal pregnancy two years earlier and asthma diagnosed during the first trimester of her current pregnancy, was admitted with at 39-week pregnancy to the obstetric ward for an elective Cesarean-section, current medication were two puffs of dose metered inhaled albuterol on a per needed basis. Surgery was performed under regional anesthesia. Due to uterine hemorrhage after birth, a bolus of 100 mcg of intravenous carbetocine was administered by intravenous infusion over 60 s, 2 min later, she presented sudden onset of dyspnea, wheezing, disseminated rash, hypotension and severe bradycardia – irresponsive to 1 mg of intravenous atropine – that progressed to a complete cardiac arrest; four minutes of advanced cardiopulmonary resuscitation which included 1 mg epinephrine was needed to restore pulse. After tracheal intubation severe wheezing and hypotension persisted, a single dose of 1.5 mg/kg IV methylprednisolone and a norepinephrine drip were initiated. Bleeding stopped, so surgery was finished and the patient was transferred to the Intensive Care Unit (ICU).

She was admitted to the ICU on mechanical ventilation, pulmonary mechanics reported high intrathoracic pressures with an auto-PEEP of 12 cm H₂O and a peak inspiratory

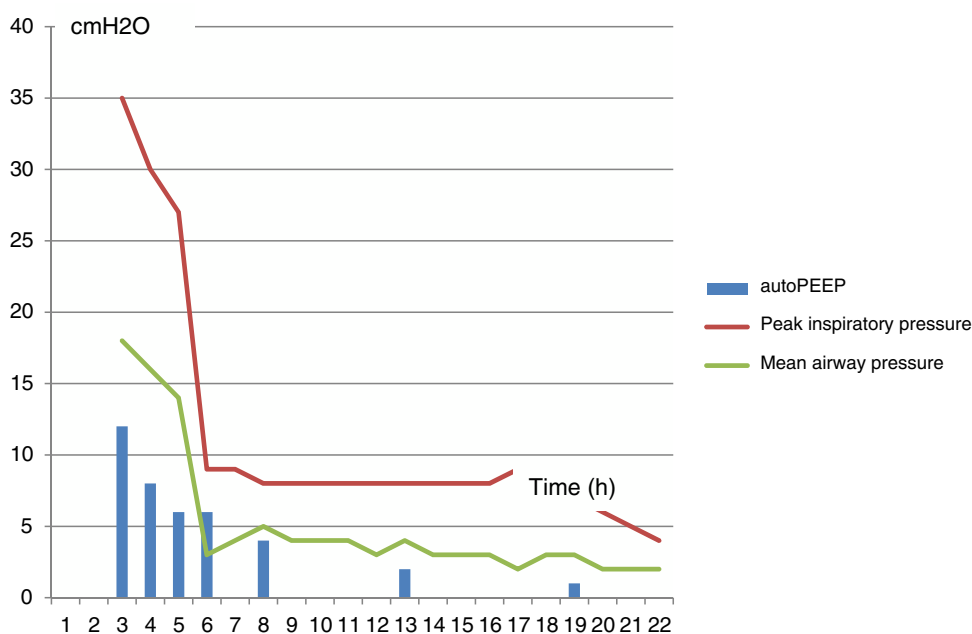


Figure 1 Pulmonary mechanics.

pressure of 35 cm H₂O. Arterial blood gases reported: PCO₂ 91 mmHg, PaO₂ 224 mm Hg, pH 6.99, HCO₃ 19 meq/L, SaO₂ 93. An ECG was obtained in sinus rhythm, with a heart rate of 95 min without conduction abnormalities. The chest X-ray ruled out pneumothorax or hyperinflation. After analgesia, sedation, and paralysis with vecuronium, under controlled mechanical ventilation, ventilator settings were modified to reduce respiratory rate and increase expiratory time, which gradually lowered intrathoracic pressures and allowed us to stop vasopressors. Albuterol 2.5 mg and ipratropium bromide 500 mcg were nebulized every 20 min, hydrocortisone and a single dose of 2 g of intravenous magnesium sulphate were also needed to finally totally overcome bronchospasm 3 h after ICU admission. Sedation was stopped, the patient regained consciousness, and 20 h after admission she was extubated and then discharged from the ICU (Fig. 1).

Asthma is estimated to occur in approximately 4% of pregnancies, frequently as a pre-existing disease, although sometimes – like in this case –, asthma may initially present during pregnancy. Prospective studies show that about 28% of pregnant asthmatics improve, 33% remain unchanged and nearly 35% deteriorate usually between 24 and 36 weeks of gestation. During labor and delivery only 10% of asthmatics report symptoms and less than 5% require treatment.⁶⁻⁸ Arrhythmias are an infrequent adverse event; however, alterations such as QT interval prolongation have been reported. These electrocardiographic alterations appear to be time and dose dependent.⁹

Pulmonary mechanics at admission to the ICU and without neuromuscular blockade did not correlate with the severity of the clinical presentation, which could be related to the way we perform clinical measurements of gas trapping, which rely in the assumption that through all expiration, all of the airways remain in communication with the proximal airway; but frequently in severe bronchoconstriction, all of them may not be in communication with

the proximal airway due to heterogeneous distribution of bronchial edema, secretions and mucus plugging; therefore, flow, pressure or gas volume cannot be accurately measured from a noncommunicating airway. In addition, expiratory muscle contraction can elevate auto-PEEP without adding to dynamic hyperinflation, therefore for accurate measurements of auto-PEEP the patient should be relaxed.^{10,11}

Although we did not find severe bronchospasm reported after carbetocin administration in our medical literature search; profound reversible intraoperative bradycardia during cesarean section has been reported recently as a novel occurrence associated with the use of carbetocin.⁵

Carbetocin prescription should have a clear indication and should be carefully individualized, based on individual medical and obstetric risk factors like prolonged labor, previous oxytocin administration, multiparity, multiple pregnancies, macrosomy, general anesthesia, and any condition that overdistends the uterus or interfere with effective uterine contraction.

Clinical medicine is full of uncertainties, ambiguous data, unusual presentations, and atypical therapeutic responses as this case, until we gather more data, and based on the approximately 4% prevalence of asthma during pregnancy, it seems wise to avoid carbetocin in asthmatic pregnant women, as well as in those with a past medical history that suggest bronchial hyperreactivity.

Financing

No funding was received for this paper.

Conflict of interest

No conflict of interest for disclosure.

Acknowledgments

None.

Bibliografía

1. Alkema L, Chou D, Hogan D, Zhang S, Moller AB, Gemmill A, et al. Global, regional, and national levels and trends in maternal mortality between 1990 and 2015, with scenario-based projections to 2030: a systematic analysis by the UN Maternal Mortality Estimation Inter-Agency Group. *Lancet*. 2016;387(10017):462–74.
2. Castañón-Castellanos A, Wulfovich-Bialostosky M, Castañón-González JA. Valoración de la compresión uterina bimanual en la hemorragia postparto. *Ginec Obst Mex*. 1984;52: 183–6.
3. Rosseland LA, Hauge TH, Grindheim G, Stubhaug A, Langesaeter E. Changes in blood pressure and cardiac output during cesarean delivery; the effects of oxytocin and carbocetin compared with placebo. *Anesthesiology*. 2013;119:541–51.
4. Vercauteren M, Palit S, Soetens F, Jacquemyn Y, Alahuhta S. Anaesthesiological considerations on tocolytic and uterotonic therapy in obstetrics. *Acta Anaesthesiol Scand*. 2009;53: 701–9.
5. Nguyen-Lu N, Almeida Carvalho JC, Farine D, Seaward G, Ye XY, Marinalini B. Carbetocin at cesarean delivery for labour arrest: a sequential allocation trial to determine the effective dose. *Can J Anesth*. 2015;62:866–74.
6. Blaiss MS. Management of rhinitis and asthma in pregnancy. *Ann Allergy Asthma Immunol*. 2003;90:16–22.
7. Schatz M, Harden K, Forsythe A. The course of asthma during pregnancy, post partum and with successive pregnancies: a prospective analysis. *J Allergy Clin Immunol*. 1988;81:509–17.
8. Wankhede U, Wadate A. Bronchial asthma in pregnancy. In: Gandhi, et al., editors. *Principles of critical care in obstetrics*, vol. II. India: Springer; 2016., http://dx.doi.org/10.1007/978-81-322-2686-4_1.
9. Bruyere M, Ait Hamou N, Benhamou D, Chousterman B, Boulard V, Charbit B. QT interval prolongation following carbetocin in prevention of post-cesarean delivery hemorrhage. *Int J Obstet Anesth*. 2014;23:88–9.
10. Stather DR, Stewart ET. Clinical review mechanical ventilation in severe asthma. *Crit Care*. 2005;9:581–7.
11. Leatherman JW, Ravenscraft SA. Low measured auto-positive end-expiratory pressure during mechanical ventilation of patients with severe asthma: hidden auto-positive end – expiratory pressure. *Crit Care Med*. 1996;24:541–6.

O.R. Pérez-Nieto, J.A. Castañón-González*,
I.M. Lima-Lucero, L.A. Gorordo Delsol

Unidad de Cuidados Intensivos y Medicina Crítica, Hospital Juárez de México, México City, Mexico

*Corresponding author.

E-mail address: jorge.castanong@gmail.com
(J.A. Castañón-González).

<https://doi.org/10.1016/j.j.medin.2017.04.005>
0210-5691/

© 2017 Elsevier España, S.L.U. y SEMICYUC. All rights reserved.