



## IMAGES IN INTENSIVE MEDICINE

### Lung ultrasound in hypoxic patient with veno-arterial ECMO



### Ecografía pulmonar en el paciente con ECMO venoarterial hipóxico

L. Martin-Villen\*, E. Jimenez-Martinez, R. Martin-Bermudez

UGC Medicina Intensiva, Hospital Universitario Virgen del Rocío, Seville, Spain

Available online 28 August 2018

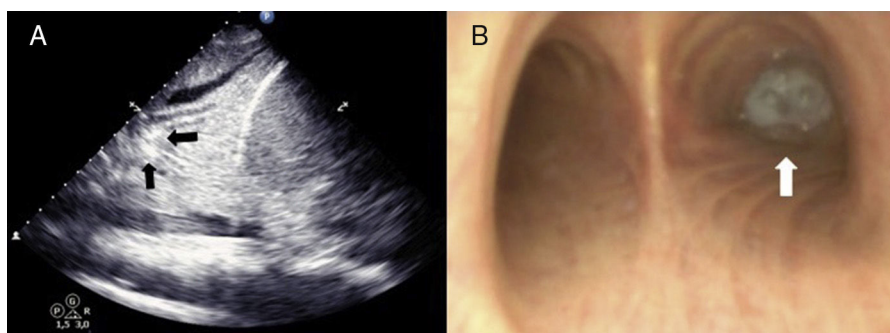


Figure 1

A 56-year-old patient admitted due to cardiogenic shock following an acute myocardial infarction. Peripheral veno-arterial extracorporeal oxygenation membrane (VA ECMO) was implanted as a bridge to decision. Five days later, patient developed differential hypoxemia between upper (SO<sub>2</sub> 77%) and lower body (SO<sub>2</sub> 100%). An echocardiogram showed left ventricular ejection fraction improvement from 10% to 30% and pulmonary ultrasound revealed a mild pleural effusion and a bilateral image of pulmonary consolidation with dynamic air bronchogram. Inside the bronchus, vermiform mobile hyperechoic images (black arrows, figure 1A) appeared synchronized with breathing (video 1). Simultaneous bronchoscopy showed purulent secretions (white arrow, figure 1B) going in and out of the bronchial tree (video 2). In patients with VA ECMO, beyond the echocardiogram, pulmonary ultrasound is essential to see lung patterns that could explain hypoxic and even to guide therapeutic attitudes.

#### Conflict of Interest

The authors declare no conflicts of interest.

#### Appendix A. Supplementary data

Supplementary data associated with this article can be found, in the online version, at [doi:10.1016/j.medin.2018.07.010](https://doi.org/10.1016/j.medin.2018.07.010).

\* Corresponding author.

E-mail address: [luis.martin.exts@juntadeandalucia.es](mailto:luis.martin.exts@juntadeandalucia.es) (L. Martin-Villen).

<https://doi.org/10.1016/j.medin.2018.07.010>

0210-5691/© 2018 Elsevier España, S.L.U. y SEMICYUC. All rights reserved.