



IMAGES IN INTENSIVE MEDICINE

Agitated saline echo testing: Two useful indications in critical care patients ☆



Ecocardiograma con solución salina agitada: dos indicaciones útiles en pacientes críticos

P. Blanco^{a,*}, G. Bello^b

^a Intensive Care Unit, Clínica Cruz Azul, Argentina

^b Intensive Care Unit, "Hospital Central de las FF.AA. (DNSFFAA)", Montevideo, Uruguay

Available online 11 November 2018

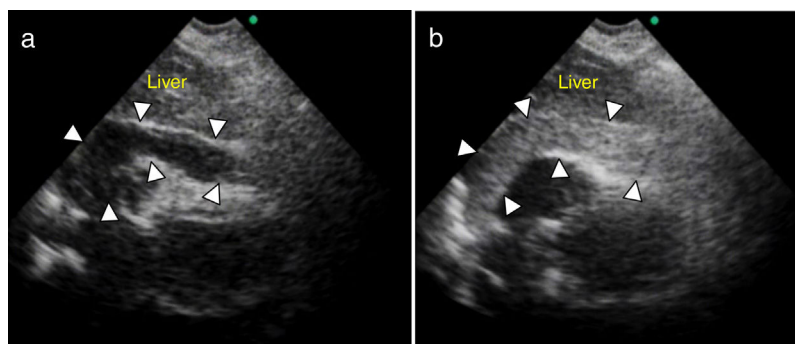


Figure 1

Agitated saline (bubble) transthoracic contrast echocardiography is a technique classically performed in diagnosing intracardiac and intrapulmonary shunts. However, there are other useful indications in critically ill patients. Typical preparation of the bubbles is shown in Video 1. One indication is in pericardiocentesis, proving the needle is in the pericardium and not in a cardiac chamber, after injecting the solution through the needle and observing the bubbles in the pericardial

☆ This work has not been presented at any conferences.

* Corresponding author.

E-mail address: ohsusabes@gmail.com (P. Blanco).

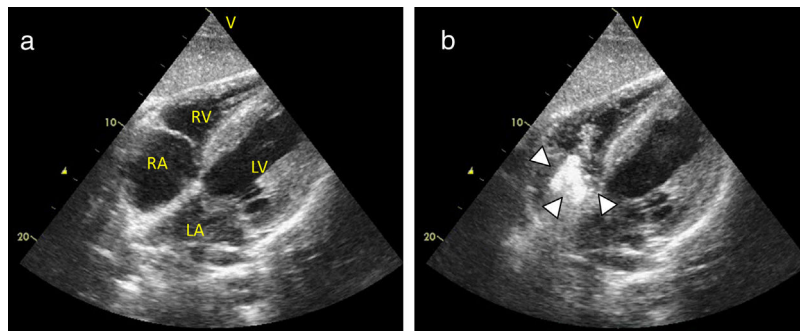


Figure 2

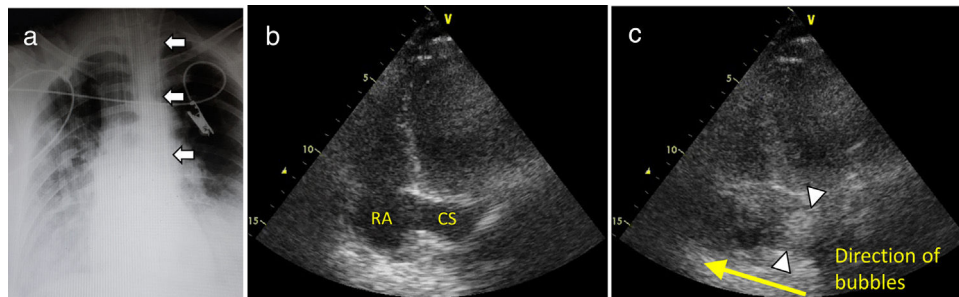


Figure 3

fluid (arrowheads, Fig. 1a, without bubbles in the pericardial fluid and b, with bubbles. Video 2; RA: right atrium; RV: right ventricle; LA: left atrium; LV: left ventricle). The second indication is for checking the adequate position of the central venous catheters when the rapid filling of the RA is observed (RA, Fig. 2a, before; and b, after injecting agitated saline through the catheter, arrowheads, and Video 3), and especially in left central venous catheters that descend through the left mediastinal border (Fig. 3a, arrows), allowing detecting that the catheter is in a persistent left superior vena cava emptying in the coronary sinus (CS), observing the filling of the CS (arrowheads) before the RA after injecting agitated saline through the catheter (Fig. 3b, before, and c; after injecting the agitated saline; Video 4), and thus ruling out an aberrant insertion (e.g. left internal mammary vein) and avoiding the unnecessary removal of the catheter and even the need of more sophisticated imaging techniques.

Funding

This work has not been supported by any grants.

Conflicts of interest

Authors have no conflicts of interest related to this submission.

Appendix A. Supplementary data

Supplementary data associated with this article can be found, in the online version, at [doi:10.1016/j.medin.2018.09.016](https://doi.org/10.1016/j.medin.2018.09.016)