

ventricle through balloon atrial septostomy or left ventricular venting. This strategy avoids the myocardial ischemia due to left-ventricular high end-diastolic pressures and also ameliorates the pulmonary edema secondary to left-atrial hypertension. In our sample, one patient did not require septostomy due to a patent foramen ovale. Left-to-right shunt might have helped to decrease end-diastolic pressure, favouring recovery and minimizing the pulmonary edema. Also appropriate afterload reduction with the use of inodilators such as milrinone and levosimendan is key to improving left ventricular stroke volume and promoting effective decompression.

In previous studies<sup>8</sup> in which ECMO was used in neonatal EV myocarditis patients, the average duration was 7 days; in our experience it was 9 and 10 days, with a complete recovery in both and 100% survival. If ECMO support had not been initiated in the situation of hemodynamic refractoriness to conventional treatment, we expected a higher mortality rate. Inwald et al. in 2004<sup>3</sup> reported 7 patients with EV myocarditis: three did not receive support with ECMO, and all survived; the 4 who required ECMO, the mortality rate was 75%. However, the small sample of both studies precludes us from being emphatic in our conclusions.

We believe that more studies about ECMO in EV myocarditis are required to draw stronger conclusions about ECMO viability. However, we believe that our data are encouraging, since the reported mortality of these patients without ECMO. Our results reveal that survival can be achieved without neurological damage. As ECMO support is improving, complications, although they may be severe, are becoming less frequent.

## References

1. Esteva C, Esteban E, Noguera A, García JJ, Muñoz-Almagro C. Severe enterovirus disease in febrile neonates. *Enferm Infecc Microbiol Clin.* 2009;27:399–402.
2. Madden K, Thiagarajan RR, Rycus PT, Rajagopal SK. Survival of neonates with enteroviral myocarditis requiring extracorporeal membrane oxygenation. *Pediatr Crit Care Med.* 2011;12:314–8.
3. Inwald D, Franklin O, Cubitt D, Peters M, Goldman A, Burch M. Enterovirus myocarditis as a cause of neonatal collapse. *Arch Dis Child Fetal Neonatal Ed.* 2004;89:461–2.
4. Freund MW, Kleinvelde G, Krediet TG, Van Loon AM, Verboon-Macielek MA. Prognosis for neonates with enterovirus myocarditis. *Arch Dis Child Fetal Neonatal Ed.* 2010;95:206–12.

5. Conrad S, Bridges B, Kalra Y, Pietsch JB, Smith AH. Extracorporeal cardiopulmonary resuscitation among patients with structurally normal hearts. *ASIAO.* 2017;63:781–6.
6. Schlapbach LJ, Ersch J, Balmer C, Prete R, Tomaske M, Caduff R, et al. Enteroviral myocarditis in neonates. *J Paediatr Child Health.* 2013;49:451–4.
7. Cortina G, Best D, Deisenberg M, Chiletto R, Butt W. Extracorporeal membrane oxygenation for neonatal collapse caused by enterovirus myocarditis. *Arch Dis Child – Fetal Neonatal Ed.* 2018;103:370–6.
8. Casadonte JR, Mazwi ML, Gambetta KE, Palac HL, McBride ME, Eltayeb OM, et al. Risk factors for cardiac arrest or mechanical circulatory support in children with fulminant myocarditis. *Pediatr Cardiol.* 2017;38:128–34.
9. Pinto VL, Pruthi S, Westrick AC, Shannon CN, Bridges BC, Le TM. Brain MRI findings in pediatric patients post ECMO. *ASAIO.* 2017;63:810–4.
10. Distelmaier K, Wiedemann D, Binder C, Haberl T, Zimpfer D, Heinz G, et al. Duration of extracorporeal membrane oxygenation support and survival in cardiovascular surgery patients. *J Thoracic Cardiovasc Surg.* 2018;155:2471–6.

S. Bobillo-Perez<sup>a</sup>, J. Sanchez-de-Toledo<sup>b,c</sup>, S.S. Matute<sup>d</sup>, M. Balaguer<sup>d</sup>, I. Jordan<sup>e,\*</sup>, J. Rodriguez-Fanjul<sup>f</sup>

<sup>a</sup> Pediatric Intensive Care Unit Service, Critical patient Research Group, Institut Recerca Hospital Sant Joan de Déu, Hospital Sant Joan de Déu, Barcelona, Spain

<sup>b</sup> Pediatric Cardiology Service, Hospital Sant Joan de Déu and University of Barcelona, Barcelona, Spain

<sup>c</sup> Critical Care Medicine Department, University of Pittsburgh, Pittsburgh, PA, United States

<sup>d</sup> Pediatric Intensive Care Unit Service, Hospital Sant Joan de Déu and University of Barcelona, Barcelona, Spain

<sup>e</sup> Pediatric Intensive Care Unit, Paediatric Infectious Diseases Research Group, Institut Recerca Hospital Sant Joan de Déu, Hospital Sant Joan de Déu, CIBERESP, Barcelona, Spain

<sup>f</sup> Pediatric Intensive Care Unit, Pediatric Service, Hospital Joan XXIII, Tarragona, Spain

\* Corresponding author.

E-mail address: [ijordan@sjdhospitalbarcelona.org](mailto:ijordan@sjdhospitalbarcelona.org) (I. Jordan).

<https://doi.org/10.1016/j.medin.2019.03.006>  
0210-5691/ © 2019 Elsevier España, S.L.U. y SEMICYUC. All rights reserved.

## ECMO in severe trauma patient with intracranial bleeding requiring surgery



### ECMO en trauma grave con sangrado intracraneal amenazante que requiere cirugía

Dear Editor:

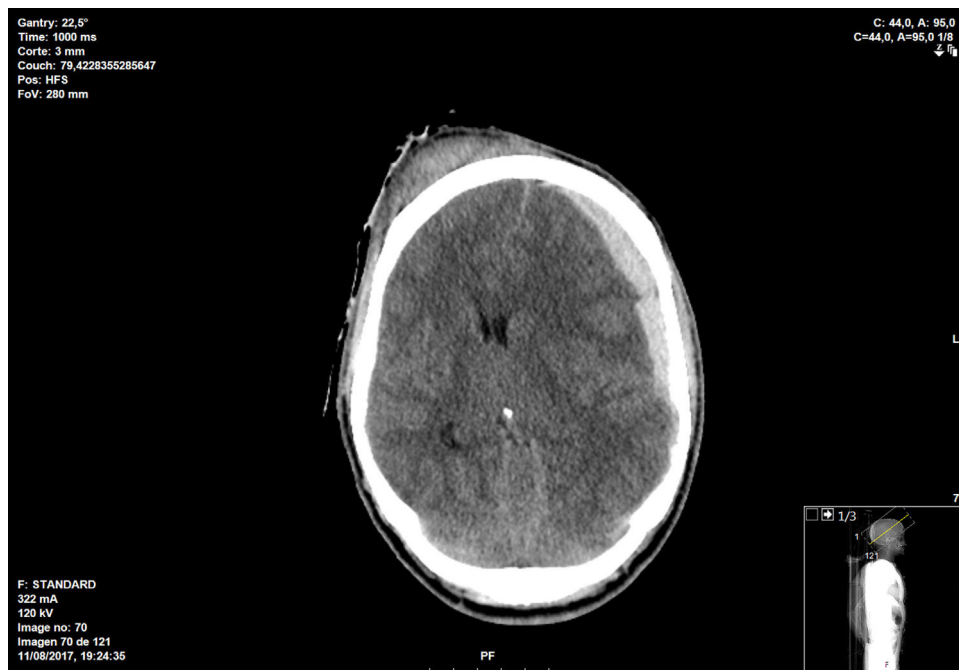
Brain Trauma incidence is about 235/100 000 inhabitants/year in Europe, frequently co-existing with thoracic trauma (35%).<sup>1</sup> Avoiding hypoxic brain damage is crucial but difficult to achieve in case of respiratory failure, given

the potential harmful effect of ventilatory strategies (prone positioning, alveolar recruitment) on intracranial hypertension (ICH).

ECMO is a lifesaving technique, assisting the failing heart or lungs, but circuit anticoagulation is required, which could increase the risk of bleeding. Consequently, trauma bleeding, and especially brain trauma are still formal contraindications for ECMO.<sup>2</sup>

We present the case of a severe BTI with intracranial bleeding requiring surgical drainage and VV ECMO for severe respiratory failure.

26 years old male suffered a motorbike crash accident. Initially presenting with GCS 4 on the scene, bilateral non-reactive pupils; BP 110/60 mmHg. Injury severity score (ISS)



**Figure 1** CT scan showing hemispheric subdural hematoma with middle line shift.

25. He was intubated and transferred to our hospital; initial CT scan showed temporal bone fracture and hemispheric subdural hematoma with middle line shift (12 mm) and signs of uncal herniation (Fig. 1).

Multiple rib fractures and right lung consolidation (lung contusion vs. aspiration pneumonitis).

He was immediately transferred to the operating theater; left frontoparietal craniotomy and hematoma drainage was performed. Direct visualization detected loss of pulsatility in frontal and parietal lobes. Parenchymal intracranial pressure (ICP) monitoring (Integra Neurosciences, San Diego) after drainage showed ICP of 25 mmHg, needing deep sedation, neuromuscular blocking, and osmotherapy. Post-operative CT scan showed correct drainage with diffuse brain edema.

The patient develops severe ARDS on day 2. Despite lung protective ventilation, bilateral pneumothorax occurs, requiring chest tube placement.

Open lung strategies such as recruitment maneuvers were not implemented due to the presence of pneumothorax, and prone positioning was tried but unfeasible due to rise in ICP (Fig. 2).

Given the refractory hypoxemia and its impact on secondary brain damage, we decided to put the patient on ECMO (Cardiohelp-Maquet-Getinge group, Rastatt, Germany).

Pre-ECMO respiratory setting:  $\text{FiO}_2$  1; PEEP 10  $\text{cmH}_2\text{O}$ ; P/F ratio 90; compliance 20  $\text{ml cm H}_2\text{O}^{-1}$  Plateau pressure 33  $\text{cm H}_2\text{O}$ ; dP 14. Murray score 3.

We utilized 23 Fr femoral drainage and 19 Fr jugular return Maquet HLS cannulae. A bolus of UFH (70 IU/kg) was administered during cannulation. We decided no anticoagulation thereafter.

Initial ECMO settings: 4.2 lpm, gas flow 5 lpm,  $\text{FiO}_2$  1. Ventilator settings after ECMO: VCV  $\text{FiO}_2$  0.4; tidal volume 3  $\text{cc/kg}$ ; RR 10 bpm PEEP 10  $\text{cmH}_2\text{O}$ .

Given the still uncontrolled ICH, cannulation was performed under deep sedation, paralysis, and osmotherapy.

Percutaneous tracheostomy was performed on day fifteen, and the last chest tube removed on day twenty.

ECMO system was closely monitored according to our protocol. Oxygenator was replaced on day seven due to an increase in LDH and reticulocyte count and a decrease in haptoglobin levels.

A decision to stop ECMO was made after ECMO time of fifteen days given respiratory improvement, correct weaning parameters, and labs showing incipient coagulopathy (slight increase in PT and aPTT ratio, and slightly decreasing platelets and fibrinogen). Having started decannulation procedure, the patient experience sudden airway bleeding. ECMO was immediately stopped and the patient decannulated, after which bleeding was controlled. 1 g fibrinogen and 600 IU of Human Prothrombin Complex were administered. Bronchoscopy was performed immediately afterward for airway clearance.

On day thirty the patient is awake, obeying commands, no motor deficit but with severe ICU acquired weakness. He was discharged after 50 days to the neurosurgery ward. Discharged home after four months with full neurological and functional recovery.

Multiple trauma is still a formal contra-indication for ECMO, given the increased risk of bleeding.<sup>2</sup>

ECMO circuit needs anticoagulation, which could be avoided in particular circumstances. But ECMO also exposes the blood to a foreign surface, triggering inflammation and coagulation, which can lead to a DIC-like consumptive coagulopathy.<sup>3</sup> Although biocompatible coatings may decrease activation of coagulation, it has not solved the issue. Therefore, running ECMO without anticoagulation does not prevent the occurrence of bleeding diathesis.

These factors, in the context of co-existing severe BTI, could lead to catastrophic intracranial bleeding. Therefore, evidence of ECMO in this scenario is anecdotic.

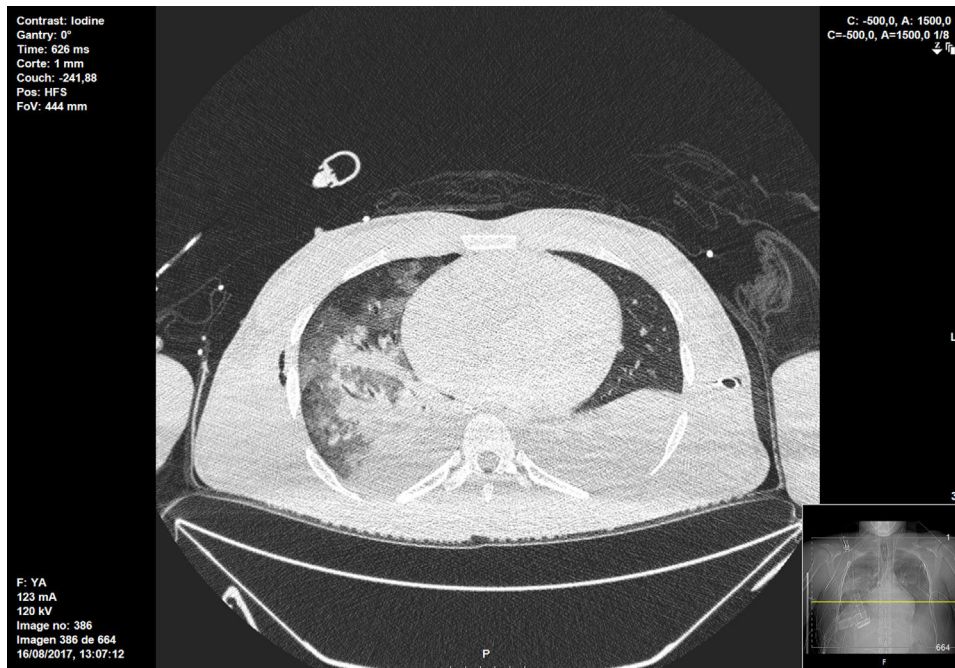

Figure 2 Thorax CT scan on day 2 showing severe lung infiltrates and atelectasis.

Biscotti<sup>4</sup> described two patients with severe BTI and intracranial bleeding who needed ECMO for ARDS. The circuit was anticoagulated with UFH with an aPTT target of 40–60 s. However, no patient experienced ICH or underwent surgery.

Muellenbach<sup>5</sup> published three trauma patients suffering BTI, none of them requiring surgery. The circuit was not anticoagulated, but ECMO time was short (maximum five days).

Friesenecker<sup>6</sup> described the first case of severe BTI requiring craniotomy who underwent ECMO for ARF for 17 days. Initially presenting with CT scan showing brain edema, ECMO was started due to severe ARDS under anticoagulation with UFH targeted to ACT of 150 s, but CT scan revealed large brain hematoma on day two, potentially influenced by anticoagulation. There are no further similar cases published to our knowledge.

In our case, ECMO was run for 15 days without anticoagulation. It was started shortly after surgery in a patient with severe intracranial bleeding and ICH aggravated by severe ARDS, with a good outcome.

Thorough system monitoring allowed safe management of a non-anticoagulated circuit, and early detection and control of complications. On the other hand, no ICP deterioration during ECMO time was detected.

This case suggests that ECMO can be implemented safely without anticoagulation, and should not be withheld from the therapeutic armamentarium in case of a severe brain trauma bleeding. Appropriate protocol implementation and close monitoring are paramount in this scenario.

## References

1. Menut R, Larrieu N, Conil J, Georges B, Fourcade O, Geeraerts T. Utilisation d'un ECMO dans un cas d'hypoxemie refractaire

associee a un traumatisme cranien grave. *Ann Franc d'Anesth et Reanim.* 2013;32:701–3.

2. Della Torre V, Badenes R, Corradi F, Racca F, Lavinio A, Matta B, et al. Acute respiratory distress syndrome in traumatic brain injury: how do we manage it? *J Thorac Dis.* 2017;9: 5368–81.
3. Mulder M, Fawzy I, Lancé M. ECMO and anticoagulation: a comprehensive review. *Neth J Crit Care.* 2018;26.
4. Biscotti M, Gannon WD, Abrams D, Agerstrand C, Claassen J, Brodie D, et al. Extracorporeal membrane oxygenation use in patients with traumatic brain injury. *Perfusion.* 2015;30: 407–9.
5. Muellenbach R, Kredel M, Kunze E, Kranke P, Kuestermann J, Brack A, et al. Prolonged heparin-free extracorporeal membrane oxygenation in multiple injured acute respiratory distress syndrome patients with traumatic brain injury. *J Trauma.* 2011;72:1444–7.
6. Friesenecker B, Peer J, Rieder J, Lirk P, Knotzer H, Hasibeder W, et al. Craniotomy during ECMO in a severely traumatized patient. *Acta Neurochir (Wien).* 2005;147:993–6.

J.I. Chico Carballas<sup>a,\*</sup>, S. Freita Ramos<sup>a</sup>,  
D. Mosquera Rodriguez<sup>a</sup>, E.M. Menor Fernandez<sup>a</sup>,  
M. Piñon Esteban<sup>b</sup>, R. Casais Pampin<sup>b</sup>

<sup>a</sup> Servicio Medicina Intensiva, Hospital Alvaro Cunqueiro, Vigo, Spain

<sup>b</sup> Servicio Cirugía Cardíaca, Hospital Alvaro Cunqueiro, Vigo, Spain

\* Corresponding author.

E-mail address: [ji\\_chico@hotmail.com](mailto:ji_chico@hotmail.com) (J.I. Chico Carballas).

<https://doi.org/10.1016/j.medin.2018.10.002>

0210-5691/ © 2018 Elsevier España, S.L.U. y SEMICYUC. All rights reserved.