

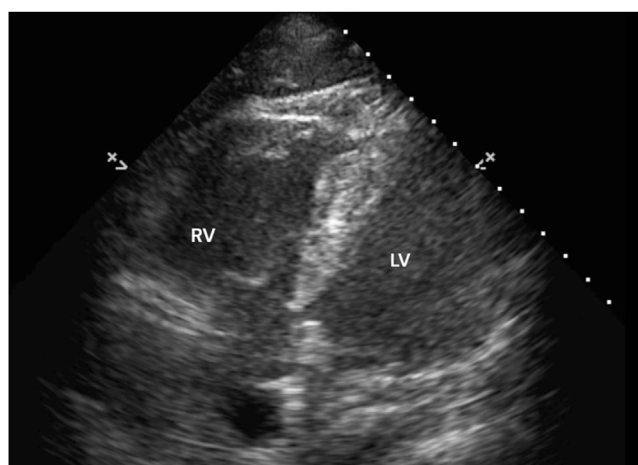


IMAGES IN INTENSIVE MEDICINE

McConnell's sign in fat embolism syndrome**Signo de McConnell en el síndrome de embolia grasa****Ripenmeet Salhotra***Amrita Institute of Medical Sciences, Faridabad, India*

Received 2 January 2024; accepted 10 January 2024

An 88-year-old male developed hypoxia, tachycardia, mild fever, agitation and confusion few hours after undergoing hip joint hemiarthroplasty. Bedside point of care ultrasound revealed dilated right atrium and right ventricle (RV) but normal dimensions and function of left ventricle (LV). RV free wall was severely hypokinetic except for the RV apex which was hyperkinetic (Fig. 1, Video 1: apical 4 chamber view). This preserved apical contractility of RV with severe hypokinesia of rest of the RV free wall is known as McConnell's sign (Video 2: RV apex in red circle), commonly observed in patients

**Figure 1** Apical 4-chamber view, dilated RV.*E-mail address:* ripenmeet.salhotra@fbd.amrita.edu<https://doi.org/10.1016/j.medin.2024.01.003>

0210-5691/© 2024 Elsevier España, S.L.U. and SEMICYUC. All rights reserved.

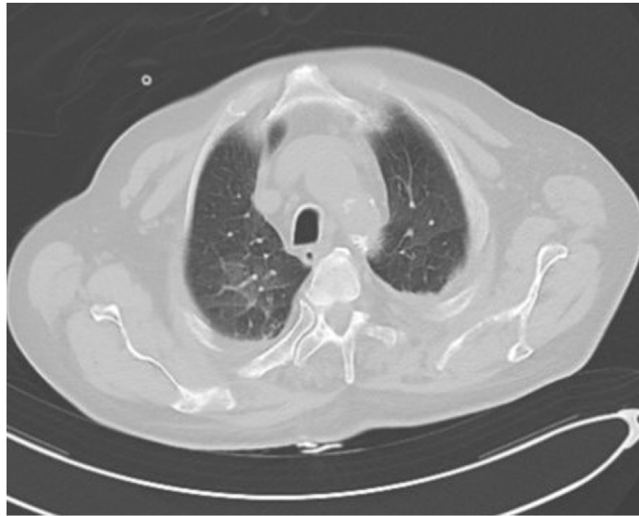


Figure 2 CT of Chest, Ground glass opacities and septal thickening.

with acute pulmonary thromboembolism (PTE). In contrast, global hypokinesia is observed in chronic RV dysfunction. No evidence of PTE but bilateral subtle ground glass opacities and interstitial septal thickening was seen on CT of chest (Fig. 2). A diagnosis of Fat Embolism Syndrome (FES) was made and patient recovered with supportive care.

Funding

Nil.

Conflict of Interest

None.

Appendix A Supplementary data

Supplementary material related to this article can be found, in the online version, at doi:<https://doi.org/10.1016/j.medin.2024.01.003>.