



IMAGES IN INTENSIVE MEDICINE

Subcutaneous emphysema everywhere!

Neumotórax subcutáneo en todas partes!

Francisca Silva Cardoso*, Rita Morais Passos

Critical Care Department, Unidade Local de Saúde Alto Minho (ULSAM), Viana do Castelo, Portugal



After a tractor accident resulting in significant thoracic trauma, a 79-year-old man was brought to the emergency room. The patient, with a history of atrial fibrillation and anticoagulation, also had obstructive lung disease and lung emphysema. Primary evaluation revealed exuberant cervical, thoracic, and abdominal emphysema. A CT scan

was performed that documented the massive subcutaneous emphysema and pneumothorax at the right hemithorax. A right-sided chest tube was inserted, and orotracheal intubation was carried out due to respiratory failure. The patient was subsequently admitted in the intensive care unit.

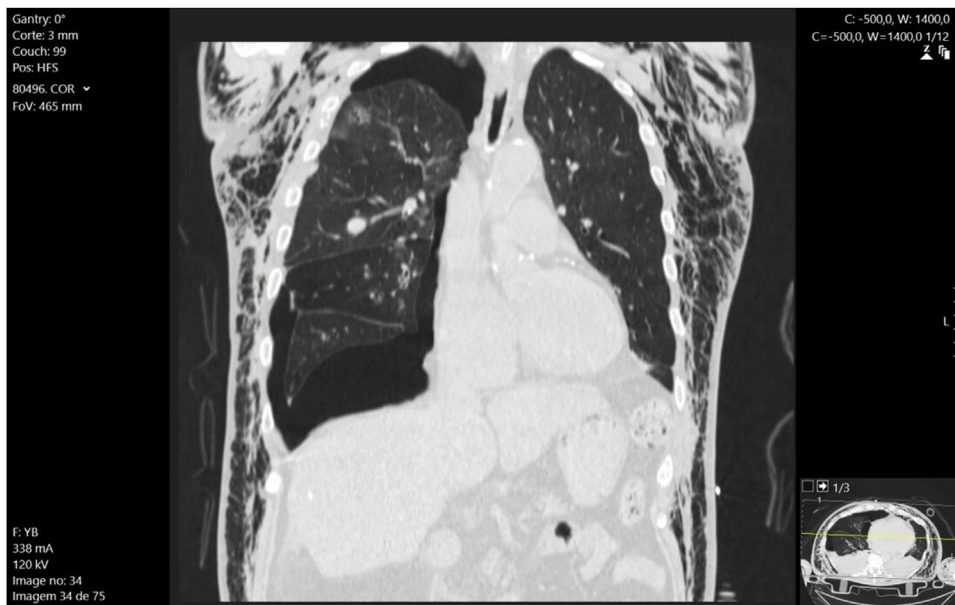


Figure 1

* Corresponding author.

E-mail address: 4384@ulsam.min-saude.pt (F.S. Cardoso).

Conflict of interest

We have no conflicts of interest to disclose.

Funding sources

This study did not require any funding.

Appendix A Supplementary data

Supplementary material related to this article can be found, in the online version, at doi:<https://doi.org/10.1016/j.medin.2024.01.007>.