



## IMAGES IN INTENSIVE MEDICINE

**Ultrasound artifacts “shred sign” and “pseudo-B lines” in the liver: What is the culprit?****Artefactos de ultrasonido “shred sign” y “pseudolíneas B” en el hígado: ¿cuál es el culpable?**

Xiaoyang Zhou, Yuyi Sha, Bixin Chen\*

Department of Intensive Care Medicine, Ningbo No.2 Hospital, Ningbo 315000, Zhejiang, China

During hospitalization, a 79-year-old male suddenly suffered abdominal pain, nausea, vomiting, and cold sweating after using the toilet on the 5th day after lumbar disc surgery. A point-of-care ultrasound displayed a “shred sign” and “pseudo-B lines” within the liver (Video 1 in Supplementary material), which was analogous to the echo profile of lung consolidation, indicating suspected intrahepatic gas. Subsequently, an abdominal computed tomographic angiography confirmed extensive gas accumulation in the portal vein (Fig. 1a–c red arrow), multiple intestinal gases, retroperitoneal effusion, and normal mesenteric artery imaging. The patient received an emergency laparotomy, during which retroperitoneal effusion was drained. Afterward, circulatory shock was quickly corrected, and the portal vein gas accumulation disappeared 48 h later (Fig. 1d).

**Author’s contribution**

Zhou X, Sha Y, and Chen B participated in the care of the patient, drafted the manuscript and revised the manuscript. All authors read and approved the final manuscript.

**Funding**

This work was supported by the grants from Zhejiang Medicine and Health Science and Technology Project (No. 2023KY1084) and the Project of NINGBO Leading Medical & Health Discipline (No. 2022-F16). The funders had no role in the study design, data collection, and analysis, decision to publish, or preparation of the manuscript.

\* Corresponding author.

E-mail address: [nbsdeyyicu@163.com](mailto:nbsdeyyicu@163.com) (C. Bixin).

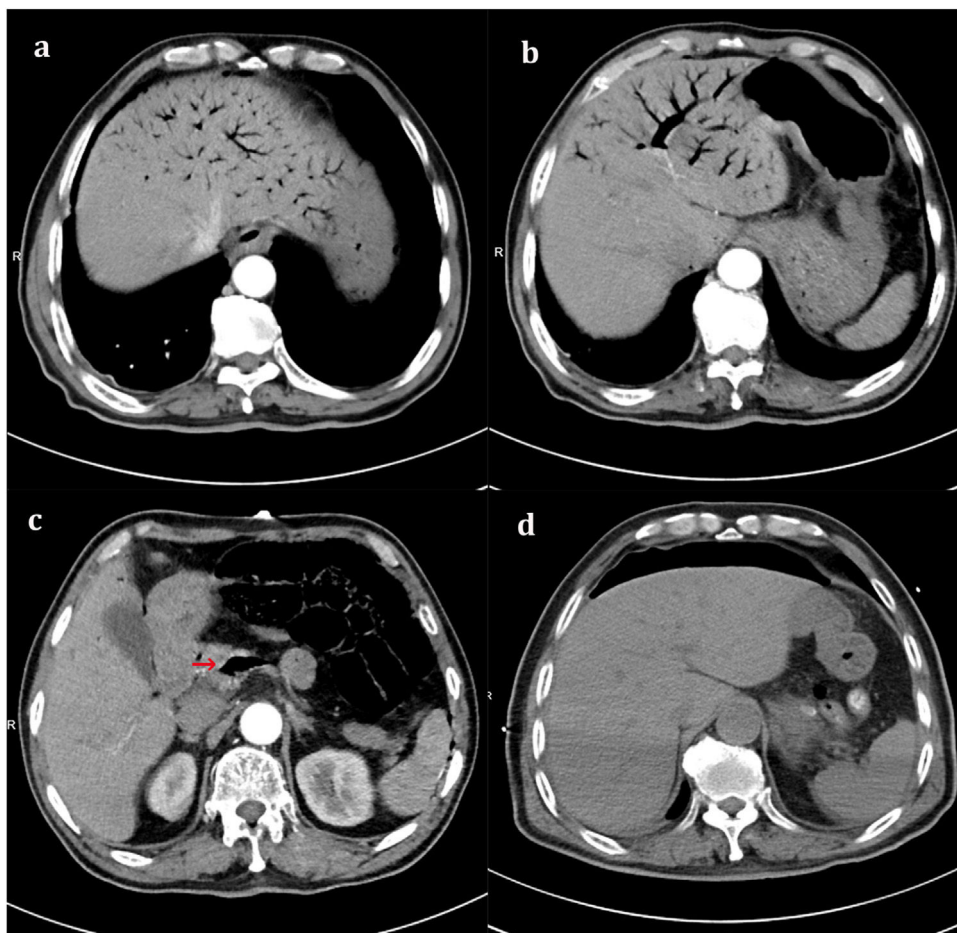


Figure 1 .

### Conflicts of interest

The authors declare that they have no potential conflict of interest.

### Consent for publication

Written informed consent was obtained from the patient for publication of this article and any accompanying images.

### Acknowledgements

None.

### Appendix A. Supplementary data

Supplementary material related to this article can be found, in the online version, at doi:<https://doi.org/10.1016/j.medin.2024.03.013>.