



ORIGINAL

Utility of diffusion-weighted magnetic resonance imaging in severe focal traumatic brain injuries[☆]

F. Prieto-Valderrey^{a,*}, J.R. Muñiz-Montes^b, J.A. López-García^b,
J. Villegas-del Ojo^a, J. Málaga-Gil^c, R. Galván-García^c

^a Servicio de Medicina Intensiva, Hospital Santa Bárbara, Puertollano, Ciudad Real, Spain

^b Departamento de Radiología, Unidad de Resonancia Magnética, Hospital Universitario de Canarias, La Laguna, Tenerife, Spain

^c Servicio de Medicina Intensiva, Hospital Universitario de Canarias, La Laguna, Tenerife, Spain

Received 29 September 2011; accepted 14 July 2012

Available online 6 October 2013

KEYWORDS

Diffusion-weighted magnetic resonance imaging;
Apparent diffusion coefficient;
Echo-planar imaging;
Brain injuries;
Vasogenic brain edema;
Cytotoxic brain edema;
Glasgow Outcome Scale

Abstract

Objective: To describe the apparent diffusion coefficient (ADC) in a series of severe traumatic brain injuries, their clinical and outcome features, and possible implications.

Design: A descriptive, observational case-series study was carried out.

Patients and interventions: Patients with severe traumatic brain injuries (TBIs) admitted to the ICU were subjected to MRI study using a 1.5 T scanner. Diffusion-weighted images (DWMR) were obtained using the following echo-planar pulse sequence: TR 10,000 ms, TE 126.9 ms, with b values 1000 s/mm² in the three spatial dimensions. Combining the three sets of images, an isotropic image conforming a map of the mean ADCs was obtained.

Results: DWMR was performed in 23 patients with severe TBI admitted to the ICU between 2001 and 2004. In the MR images we selected 26 regions of interest (ROIs) where ADC was recorded. We observed a clear increase in diffusion in non-treated space-occupying lesions versus other types of injuries and the normal values. A poorer outcome was recorded in patients with lower ADC values.

Conclusions: Mean ADC in the lesions was greater than the normal values and greater in contusions than in other types of injuries, as an expression of extracellular edema. ADCs were decreased in patients with a poor outcome, suggesting an association between ischemia and the patient prognosis.

© 2011 Elsevier España, S.L. and SEMICYUC. All rights reserved.

[☆] Please cite this article as: Prieto-Valderrey F, Muñiz-Montes JR, López-García JA, Villegas-del Ojo J, Málaga-Gil J, Galván-García R. Utilidad de la resonancia magnética potenciada en difusión en pacientes con lesiones focales por traumatismo craneoencefálico grave. Med Intensiva. 2013;37:375–382.

* Corresponding author.

E-mail address: fprietom@sescam.jccm.es (F. Prieto-Valderrey).

PALABRAS CLAVE

Resonancia magnética de difusión;
 Coeficiente de difusión aparente;
 Imagen eco-planar;
 Lesiones cerebrales;
 Edema cerebral vasogénico;
 Edema cerebral citotóxico;
 Escala de resultados de Glasgow

Utilidad de la resonancia magnética potenciada en difusión en pacientes con lesiones focales por traumatismo craneoencefálico grave

Resumen

Objetivo: Describir el coeficiente de difusión aparente (CDA) medido mediante resonancia magnética potenciada en difusión (RMD) en una serie de pacientes con traumatismo craneoencefálico (TCE) grave, sus aspectos clínicos y pronósticos y sus posibles implicaciones.

Diseño: Estudio observacional, descriptivo de serie de casos.

Pacientes e intervenciones: Pacientes con TCE grave, ingresados en UCI que no presentan contraindicaciones para traslado y realización de resonancia magnética (RM). Se realizó RM usando un scanner de 1.5 Tesla. Las imágenes potenciadas en difusión se obtuvieron usando una secuencia de pulso eco-planar con las siguientes características: TR 10.000 ms, TE 126,9 ms, valores b 1.000 s/mm² en las tres direcciones del espacio. Combinando los tres sets de imágenes se obtuvo una imagen isotrópica que constituyó el mapa de los CDA medios.

Resultados: RMD se realizó en 23 pacientes con TCE grave ingresados en UCI entre 2001 y 2004. Se seleccionaron para su análisis 26 regiones de interés y se recogió el CDA en cada una de ellas. Se observó un incremento en la difusión en las lesiones ocupantes de espacio no evacuadas respecto a otros tipos de lesión y a valores normales. El pronóstico, según la escala de resultados de Glasgow, fue peor en los pacientes con valores de CDA más bajos.

Conclusiones: Los CDA medios fueron mayores que los valores normales y mayores en las contusiones que en otros tipos de lesión, como expresión de edema extracelular. Los CDA estaban disminuidos en pacientes con mal pronóstico sugiriendo una asociación entre isquemia y pronóstico.

© 2011 Elsevier España, S.L. y SEMICYUC. Todos los derechos reservados.

Introduction

The mortality statistics of severe traumatic brain injury (TBI) have changed very little in the last 20 years. The principal mechanism leading to death is uncontrolled intracranial hypertension and the ischemic brain damage it produces.¹ The cause of such intracranial hypertension is the increase in brain volume triggered by different mechanisms, including vasogenic or extracellular brain edema secondary to rupture of the blood-brain barrier (BBB) and cytotoxic or intracellular edema, associated to ischemia. Intracellular edema is considered to be the main contributor to brain swelling after closed trauma.²⁻⁴

Diffusion-weighted magnetic resonance imaging (DWMR) produces a signal with an intensity proportional to the diffusion of water molecules in the tissues. The signal depends on the diffusion capacity of the molecules, on the interactions among them, and on the obstacles facing molecular movement. The intensity of the signal can be quantified by the apparent diffusion coefficient (ADC), which is calculated by means of the following formula: $ADC = (1/b) \log(S1/S0)$, where "b" is a factor that depends on the strength and duration of the pulses applied to increase diffusion, "S1" is the intensity of the diffusion-weighted signal, and "S0" is the intensity of the non-diffusion-weighted signal. If this formula is applied to each voxel (three-dimensional graphic element), the end result is a map or image in which the intensity of the signal is proportional to the ADC of each region or tissue examined.⁵⁻⁸

Conventional magnetic resonance imaging (MRI) is unable to distinguish between types of edema based on the intensity of the signal; both types of edema, cytotoxic and vasogenic, produce a hyperintense signal in T2-weighted sequences.

In contrast, DWMR differentiates cytotoxic edema, which is characterized by an increase in intracellular fluid uptake, resulting in low ADC values. The ADC is reduced as a consequence of restricted water molecule diffusion produced by the membranes and organelles within the cell, and by the increase in viscosity.

In contrast, in vasogenic edema, the fluid displaces from the vessels to the extracellular compartment, which therefore increases in size and allows the molecules to move more freely. This produces different effects in the magnetic resonance image: either high signal intensity in the ADC and DWMR maps or, less frequently, high signal intensity in the ADC map and low signal intensity in the DWMR image (facilitated diffusion). These changes in signal intensity are generally located around a focal parenchymal lesion, for example, a hematoma, since the blood clot exerts an osmotic effect upon the surrounding brain tissues.^{4,9}

To date, the main application of DWMR has been the detection of acute cerebral infarction. In this context, it is able to detect stroke earlier than any other technique, thanks to its high sensitivity, and DWMR is moreover able to predict the infarct size and assess the patient prognosis.¹⁰⁻¹³

DWMR has been used in patients with TBI to evaluate diffuse axonal injury (DAI), in view of its greater sensitivity compared with other conventional techniques (T2 and FLAIR sequencing) in the acute phase after trauma.^{14,15} In addition, the volume of the lesion detected with this technique is correlated to clinical outcome.

Since DWMR is able to distinguish between extracellular and intracellular edema, it could be used to evaluate the contribution of both types of edema to the damage observed in patients with severe TBI.¹⁶ Furthermore, the early detection of secondary ischemic lesions in severe TBI would be

Table 1 Epidemiological and clinical data.

Epidemiological data	No.	Mean \pm SD/(%)
Age	23	37.0 \pm 18.8
APACHE II	22	15.5 \pm 4.8
Male sex	15	65%
Traffic accident	15	65%
Glasgow coma score 3–5	9	39%
Glasgow coma score 6–8	10	43%

APACHE: acute physiology and chronic health evaluation; SD: standard deviation.

of great importance, given their impact upon morbidity-mortality.

The present study analyzes the ADC values in a series of patients with focal trauma and their correlation to initial clinical severity and ultimate patient prognosis or outcome.

Methods

Design

A descriptive, observational case series is presented.

Patients and clinical data

The study involved patients with severe TBI, defined by a Glasgow coma score of fewer than 9 without sedation in the first 24 h after injury,¹⁷ admitted to the Intensive Care Unit (ICU) of Canarias University Hospital (Spain), and with no contraindications to transfer or MRI study.

The traumatisms were categorized according to the initial computed tomography (CT) scan, based on the Marshall classification¹⁸ (Table 1).

All patients were subjected to early surgical evacuation of space-occupying lesions, with hemodynamic, respiratory and intracranial pressure monitoring. Intracranial hypertension was managed using osmotherapy, optimized hyperventilation, and occasionally barbiturates. The outcome data were evaluated based on the Glasgow Outcome Score (GOS) at discharge from the ICU and after 6 months.¹⁹

Imaging techniques and analysis

The MRI studies were made using a 1.5 Tesla system (General Electric). The imaging protocol comprised the following sequences: a T1-weighted sagittal sequence, a T1-weighted axial sequence, a T2-weighted axial sequence, and a fluid attenuated inversion recovery (FLAIR) sequence. The diffusion-weighted images were obtained using an echo-planar pulse sequence with the following characteristics: TR 10,000 ms, TE 126.9 ms, *b* values 1000 s/mm² in the three spatial dimensions. By combining the three sets of images we obtained an isotropic image conforming a map of the mean ADC values. Image processing for calculation of ADC was made using Functool 2000[®] software.

In order to analyze the image, we established a measurement zone in each lesion, selecting the section where the diffusion-weighted image presented a greater signal intensity, and within this image we selected a bidimensional

region of interest (ROI) where ADC was measured. The core of the hemorrhagic lesions was excluded from the calculation. In the diffuse lesions we measured ADC in one or both hemispheres.

The normal reference values for the mean ADC were those obtained by Helenius et al.,²⁰ who measured the values of 18 neuroanatomical regions in 18 healthy volunteers. The values are the following: (890 \pm 40) $\times 10^{-6}$ mm²/s in the cortical gray matter (range 780–1090 $\times 10^{-6}$ mm²/s), (700 \pm 30) $\times 10^{-6}$ mm²/s in the white matter (range 620–790 $\times 10^{-6}$ mm²/s), (750 \pm 30) $\times 10^{-6}$ mm²/s in the basal ganglia (range 640–830 $\times 10^{-6}$ mm²/s), and (730 \pm 30) $\times 10^{-6}$ mm²/s in the thalamus (range 670–820 $\times 10^{-6}$ mm²/s).

Statistical analysis

Continuous variables are reported as the mean and standard deviation, while discrete variables are reported as absolute and relative frequencies.

Results

We recorded 71 patients with severe TBI admitted to the ICU between November 2001 and October 2004. DWMR was performed in 23 of them.

Tables 1 and 2 show the epidemiological and clinical data.

Regarding the types of injuries, surgically evacuated space-occupying lesions were the most frequent presentation, followed by type II lesions. There were no type III diffuse lesions in our series. Seven lesions were defined as diffuse axonal injury (DAI) on the basis of their magnetic resonance location in the subcortical white matter, corpus callosum or brainstem, together with persistent coma (Glasgow coma score < 9).

Regarding outcome as determined by the GOS, 70% of the patients had died or were in a vegetative state or seriously disabled (poor prognosis) at discharge from the ICU, versus 43% after 6 months. These results are reported in Table 3.

Imaging data

Attempts were made to perform MRI as soon as possible after admission, though in only four patients was the exploration made within the first 24 h, while 12 patients (14 lesions) were subjected to MRI evaluation within the first 48 h. In the rest of the cases the timing of the study was highly varied due to different reasons—fundamentally patient instability and the distance to the MRI unit, which according to the physician in charge questioned the usefulness of the study. In any case, we finally decided to analyze all the studies, even if performed over a broad interval of time. Globally, MRI was performed at an average of 101.39 \pm 111.80 h (range 10–360) after trauma.

We selected 26 ROIs for analysis in the images of the 23 patients, and documented the ADC in each of them. Table 4 shows the mean values globally and according to the type of lesion. An increase in diffusion in the non-evacuated space-occupying lesions was observed when compared with the rest of the types of injuries and with the normal values.

Table 2 Types of injuries according to the Marshall classification.

Types of injuries	No.	(%)
Initial CAT: injury type II ^a	9	39
Initial CAT: injury type III	0	
Initial CAT: injury type IV	1	4
Initial CAT: injury type V	9	39
Initial CAT: injury type VI	4	17

Category	Definition
Type I diffuse lesion (no visible alterations)	No intracranial alterations visible in CAT
Type II diffuse lesion	Permeable basal cisterns. Midline deviation is <5 mm. No high-density lesions or mixed-density lesions larger than 25 ml. Possible bone fragments or foreign bodies
Type III diffuse lesion (swelling)	Compressed or absent cisterns. Midline deviation is <5 mm. No high-density lesions or mixed-density lesions larger than 25 ml
Type IV diffuse lesion	Midline deviation is >5 mm. No high-density lesions or mixed-density lesions larger than 25 ml
Evacuated mass-type lesion	Any surgically evacuated lesion
Non-evacuated mass-type lesion	High-density lesions or mixed-density lesions larger than 25 ml, not surgically evacuated

^a Marshall classification of injuries in the Initial CAT scan.^{1,18}

Table 3 Glasgow outcome score.

Glasgow outcome score	Discharge from ICU	6 months
Death	3	3
Vegetative state	5	0
Severe disability	8	7
Poor prognosis	16	10
Moderate disability	5	9
Minimal or no disability	2	4
Good prognosis	7	13
Total	23	23

The ADC values showed a progressive increase with the time from trauma–ADC in the first 48 h being lower than the values recorded later in time ($898.7 \pm 205.3/1026.6 \pm 164$).

The prognosis (outcome) was considered poor if the patient had died after 6 months or was in a vegetative state or seriously disabled, and good in the case of patients with moderate or slight disability, or no disability. As can be seen in Table 5, the patients with a poor prognosis had lower ADC values than those with a good prognosis. Fig. 1 shows the outcomes according to the ADC findings at the three measurement timepoints. It should be noted that both in the global results and on considering only the measurements

Table 4 Apparent diffusion coefficient, global and according to type of injury.

Type of injury	No.	ADC ^a	Normal mean ADC
<i>Global</i>	No. = 26	957.80 ± 194.88^b	
<i>Space-occupying lesions</i>	No. = 16	985.3 ± 197.7	890 ± 40 (780–1090) in the cortical gray matter
Untreated hemispheric hematoma or contusion	No. = 12	1029.91 ± 127.39	
Surgically evacuated hemispheric hematoma or contusion	No. = 4	851.75 ± 322.76	
<i>Unilateral diffuse injury</i>	No. = 3	876 ± 250.21	890 ± 40 (780–1090) in the cortical gray matter
<i>Diffuse axonal injury or brainstem contusion</i>	No. = 7	929.85 ± 182.70	700 ± 30 (620–790) in the white matter 730 ± 30 (670–820) in the thalamus

^a ADC: apparent diffusion coefficient.

^b ADC units: $\text{mm}^2/\text{s} \times 10^{-6}$. The table reports the mean \pm standard deviation.

Table 5 Mean ADC value in relation to patient outcome.

GOS 6 months	ADC: mean ± SD (95%CI)		No. lesions
	Poor outcome	Good outcome	
All injuries	901.3 ± 231.9 (753.9–1048.6)	1006.2 ± 148.5 (920.4–1.091.9)	26
Diffuse axonal injury	916.6 ± 191.4 (441.0–1392.2)	939.7 ± 204.9 (613.5–1.265.9)	7
Hemispheric injuries	896.2 ± 254.2 (700.7–1091.6)	1032.8 ± 122.9 (944.8–1.120.7)	19
Total	12	14	

95%CI: 95% confidence interval of the mean; SD: standard deviation. Nonsignificant (Mann–Whitney *U*-test). ADC units: mm²/s × 10⁻⁶.

made in the first 24h and those made in the first 72 h, the ADC values were always lower in the patients with a poor prognosis—though the sample size was too small to allow the drawing of firm conclusions.

Summary of results

The ADC values were higher in patients with contusions than in those with other types of injuries. In patients with a poor prognosis, the ADC values were lower.

Discussion

1. The diffusion of water in the brain tissues, measured by MRI techniques, was greater in contusions than in other types of injuries, which could be an expression of vasogenic edema.

Findings of other studies: regarding the changes in ADC after traumatism, experimental studies in animals have yielded contradictory results, as can be seen in Table 6, where some authors have reported an increase in diffusion as a result of vasogenic edema²¹ while others describe a two-phase response²² or even significantly diminished diffusion values.²³ Some studies only report changes when secondary damage is added, with diffusion decreasing as a result of cytotoxic edema.^{24–29}

The apparently conflicting results of these studies could be attributed to the diversity of lesion models

used, the different MRI techniques employed for measurement, and the lack of distinction between cortical lesions and diffuse axonal injury, which could involve different mechanisms and evolutive patterns. In animal studies, the ADC values are generally measured in the first minutes or hours after injury, while in humans ADC is measured from hours to days after trauma in many cases. This could explain the different ADC variation profiles observed.

Human studies have focused on three aspects: the identification of diffuse axonal injury and its diffusion characteristics; analysis of the type of edema in the brain lesions; and evaluation of the usefulness of DWMR in predicting the clinical outcome. Many authors agree that DWMR is more sensitive than other conventional MRI techniques in detecting DAI,^{30–32} but the observed diffusion changes vary. In a study of 116 patients with DAI, 64% of the lesions had diminished ADC values while 34% presented increased values.³¹ Liu reported decreased diffusion values in 9 patients with DAI. In these patients, the ADC values decreased significantly in typical DAI observed in conventional MRI images, from as early as one day after injury, and this decrease persisted for up to 18 days.³³ On the other hand, the significance of these changes is also controversial. In this context, some authors consider that lesions with low ADC values are indicative of severe brain damage and could predict the long-term outcome.^{30,32} Schaefer et al.³² studied 26 patients with DAI using DWMR. They observed a strong correlation between the volume of the signal intensity alteration in the diffusion-weighted images and initial clinical severity, but this correlation did not improve on only considering lesions with decreased ADC values. Hou et al.³⁴ in turn analyzed the changes in diffusion in 37 adults with brain injuries. Patients with more serious injuries were found to have ADC values significantly different from those of the controls, and patients with an unfavorable prognosis presented significantly higher ADC values than individuals with a favorable prognosis or the controls.

In our series we identified 7 cases of DAI, with mean ADC values above normal. After 6 months, three of these patients had a poor prognosis.

Regarding the type of edema, some authors consider that the distinction between intra- and extracellular edema is of key prognostic and therapeutic importance.^{35–37} In a series of patients with traumatism in which the fluid content and ADC were measured using MRI, the authors observed an increase in tissue fluid

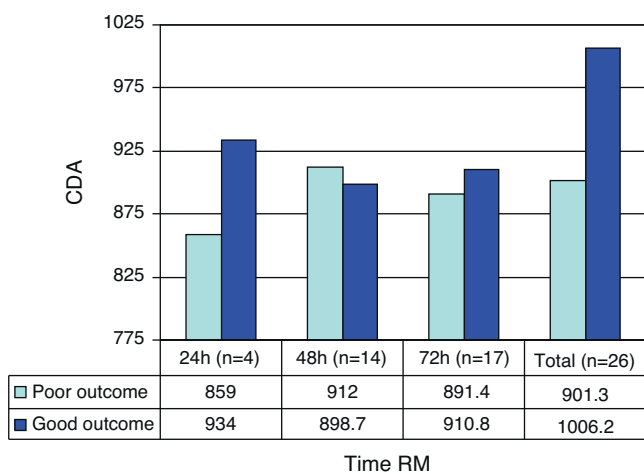


Figure 1 Patient outcome according to the ADC findings, globally and corresponding to the three measurement timepoints.

Table 6 Studies in animal models of brain injury.

Author/year	Model of brain injury	Experimental protocol	Results
Hanstock (1994) ²¹	Percussion	18 rats: 9 in the trauma group, 3 in the unilateral carotid ligation group, and 6 controls. The images were obtained 1, 2 and 4 h after ischemia or trauma, and the ADC values were calculated	A significant increase in ADC was observed in the damaged cortical gray matter, 60 min after trauma. In rats with ischemia, ADC was significantly decreased at this timepoint
Alsop (1996) ²³	Percussion	10 rats: 6 in the trauma group and 4 controls DWMR after injury	The ADC values decreased in the first 45 min
Ito (1996) ²⁴	Impact-acceleration	36 rats in 4 groups: control, trauma alone, hypoxia and hypotension, and trauma with hypoxia and hypotension (THH) DWMR at intervals of 1 h after injury	ADC in the THH group decreased quickly to a minimum 3 h after injury. In trauma alone, ADC did not decrease significantly
Barzo 1997 ²²	Impact-acceleration	36 rats: 30 in the trauma group and 6 controls ADC and brain water content were measured immediately after injury and on days 1, 3, 7, 14, using spin-echo or SVS ^a diffusion-weighted imaging	ADC increased in the first hour and then decreased, reaching a minimum on day 7
Barzo (1997) ²⁸	Impact-acceleration	50 rats (42 trauma and 8 controls). ADC and brain water content were measured immediately after injury and on days 1, 3, 7, 14, using spin-echo or SVS ^a diffusion-weighted imaging	ADC increased in the first hour and then decreased, reaching a minimum on day 7
Beaumont (2000) ²⁶	Impact-acceleration	44 rats: Group 1; trauma with hypoxia and hypotension. Group 2; trauma alone Effect of the addition of dopamine Measurement of ADC at baseline and after 4 h	Dopamine worsened swelling
Portella (2000) ²⁵	Impact-acceleration + secondary injury	Groups of rats: controls, moderate trauma with/without hypoxia and hypotension, severe trauma with/without hypoxia and hypotension, hypoxia, and hypotension alone Spin-echo or SVS ^a diffusion-weighted imaging	Increased cortical water content was observed 4 h after injury, inversely related to the change in ADC Secondary injuries act synergically with trauma, increasing intracellular water
Van Putten (2005) ²⁹	Percussion + secondary injury	4 groups: controls, hypoxia alone, trauma alone, and hypoxia and trauma ADC mapping 2, 4, 24 h and 1 week after injury	Early decrease in ADC, followed by an increase after one week. No changes related to hypoxia were observed. Good correlation to histopathological changes

^a SVS: single voxel spectroscopy.

associated with a decrease in ADC—thus suggesting predominant intracellular edema,³⁵ though in this study the type of lesion and the time elapsed between trauma and MRI were not specified. In a later study, the same group³⁶ used MRI techniques to identify the type of edema that developed in 44 patients with serious brain injuries. The patients with brain swelling showed an increased brain water content and low ADC values, compared with the healthy volunteers. The authors concluded that

traumatic brain swelling appears to be predominantly cellular, as suggested by the low ADC values and the high tissue water content.

Our patients predominantly presented mass-type lesions, and the latter (12 non-evacuated, mixed-density contusions) showed an increase in diffusion that could be an expression of vasogenic edematization, even when only considering the images obtained in the first 48 h after injury. Such lesions would correspond to type

I injuries according to the classification proposed by Gasparetto,⁴ referred to traumatic brain injury patterns in DWMR/ADC imaging. According to this classification, type I injuries consist of hyperintense images in diffusion-weighted imaging with an increase in ADC, representing vasogenic edema. Type II injuries in turn comprise hyperintense lesions in diffusion but with a decrease in ADC, indicating cytotoxic edema, while type III injuries correspond to central hemorrhagic lesions surrounded by a hyperintense area in the diffusion image and an increase in ADC. It is important to note that in diffusion imaging of hemorrhagic lesions it is not clear whether low ADC values correspond to cytotoxic edema or to artifacts produced by extravasated blood.

- Our patients with a poor outcome had lower ADC values than those with a good outcome. Many studies have described different ADC values in patients with a poor prognosis compared with controls or patients with a good prognosis, but there is little consensus regarding the pattern of change, as reflected by the abovementioned studies.^{31,32,34,36-39}
- Study limitations.

Of all the severe brain injury patients admitted to the ICU, we were only able to use DWMR in 23 cases, due to problems related to critical patient transfer, which make it difficult to perform early and repeated MRI scans. As a result, our sample size was small and scanning covered a broad time interval.

In addition, we had no cases of diffuse swelling for comparison with other types of injuries; as a result, our study fundamentally centers on focal injuries.

Another recognized limitation is the use of reference values cited in the literature, instead of values referred to contemporaneous controls.

Conclusions

The mean ADC values in the lesions were greater than the normal values and greater in contusions than in other types of injuries, thus indicating that extracellular edema probably plays a dominant role in these lesions.

The ADC values were decreased in patients with a poor prognosis, suggesting an association between ischemia and patient outcome.

Conflicts of interest

The authors declare that they have no conflicts of interest.

References

- Marmarou A, Anderson RL, Ward JD, Choi SC, Young HF, Eisenberg HM, et al. Impact of ICP instability and hypotension on outcome in patients with severe head trauma. *J Neurosurg.* 1991;75 Special Suppl 1:S59-66.
- Miyasaka N, Kuroiwa T, Zhao FY, Nagaoka T, Akimoto H, Yamada I, et al. Cerebral ischemic hypoxia: discrepancy between apparent diffusion coefficients and histologic changes in rats. *Radiology.* 2000;215:199-204.
- Grant PE, He J, Halpern EF, Wu O, Schaefer PW, Schwamm LH, et al. Frequency and clinical context of decreased apparent diffusion coefficient reversal in the human brain. *Radiology.* 2001;22:43-50.
- Gasparetto EL, Rueda Lopes FC, Domingues RC, Domingues RC. Diffusion imaging in traumatic brain injury. *Neuroimaging Clin N Am.* 2011;21:115-25.
- Cercignani M, Horsfield MA. The physical basis of diffusion-weighted MRI. *J Neurol Sci.* 2001;186 Suppl 1:S11-4.
- Xing D, Papadakis NG, Huang CL, Lef VM, Carpenter TA, Hall LD. Optimised diffusion-weighting for measurement of apparent diffusion coefficient (ADC) in human brain. *Magn Reson Imaging.* 1997;15:771-84.
- Schaefer PW. Applications of DWI in clinical neurology. *J Neurol Sci.* 2001;186:s25-35.
- Moritani T, Shrier DA, Numaguchi Y, Takase Y, Takahashi C, Wang HZ, et al. Diffusion-weighted echo-planar MR imaging: clinical applications and pitfalls. A pictorial essay. *J Clin Imaging.* 2000;24:181-92.
- Gass A, Niendorf T, Hirsch JG. Acute and chronic changes of the apparent diffusion coefficient in neurological disorders—biophysical mechanisms and possible underlying histopathology. *J Neurol Sci.* 2001;186 Suppl 1:S15-23.
- Beauchamp NJ, Ulug AM, Passe TJ, van Zijl PC. MR diffusion imaging in stroke: review and controversies. *Radiographics.* 1998;18:1269-83.
- Schaefer PW, Gonzalez RG, Hunter G, Wang B, Koroshetz WJ, Schwamm LH. Diagnostic value of apparent diffusion coefficient hyperintensity in selected patients with acute neurologic deficits. *J Neuroimaging.* 2001;11:369-80.
- Schaefer PW, Ozsunar Y, He J, Hamberg LM, Hunter GJ, Sorensen AG, et al. Assessing tissue viability with MR diffusion and perfusion imaging. *AJNR Am J Neuroradiol.* 2003;24:436-43.
- Mullins ME, Schaefer PW, Sorensen AG, Halpern EF, Ay H, He J, et al. CT and conventional and diffusion-weighted MR imaging in acute stroke: study in 691 patients at presentation to the emergency department. *Radiology.* 2002;224:353-60.
- Gallagher CN, Hutchinson PJ, Pickard JD. Neuroimaging in trauma. *Curr Opin Neurol.* 2007;20:403-9.
- Ezaki Y, Tsutsumi K, Morikawa M, Nagata I. Role of diffusion-weighted magnetic resonance imaging in diffuse axonal injury. *Acta Radiol.* 2006;47:733-40.
- Barzó P, Marmarou A, Fatouros P, Hayasaki K, Corwin F. Biphasic pathophysiological response of vasogenic and cellular edema in traumatic brain swelling. *Acta Neurochir.* 1997;70 Suppl:119-22.
- Teasdale G, Jennett B. Assessment of coma and impaired consciousness. A practical scale. *Lancet.* 1974;2:81-4.
- Marshall LF, Marshall SB, Klauber MR, Clark MB. A new classification of head injury based on computerized tomography. *J Neurosurg.* 1991;75:S14-20.
- Jennett B, Bond M. Assessment of outcome after severe brain damage. *Lancet.* 1975;i:480-7.
- Helenius H, Soinnie L, Perkiö J, Salonen O, Kangasmäki A, Kaste M, et al. Diffusion-weighted MR imaging in normal human brains in various age groups. *Am J Neuroradiol.* 2002;23:194-9.
- Hanstock C, Faden A, Bendall M, Vink R. Diffusion-weighted imaging differentiates ischemic tissue from traumatized tissue. *Stroke.* 1994;25:843-8.
- Barzó P, Marmarou A, Fatouros P, Hayasaki K, Corwin F. Contribution of vasogenic and cellular edema to traumatic brain swelling measured by diffusion-weighted imaging. *J Neurosurg.* 1997;87:900-7.
- Alsop D, Murai H, Detre J, McIntosh T, Smith D. Detection of acute pathologic changes following experimental traumatic brain injury using diffusion-weighted magnetic resonance imaging. *J Neurotrauma.* 1996;13:515-21.

24. Ito J, Marmarou A, Barzó P, Fatouros P, Corwin F. Characterization of edema by diffusion-weighted imaging in experimental traumatic brain injury. *J Neurosurg.* 1996;84:97–103.
25. Portella G, Beaumont A, Corwin F, Fatouros P, Marmarou A. Characterizing edema associated with cortical contusion and secondary insult using magnetic resonance spectroscopy. *Acta Neurochir.* 2000;76 Suppl:273–5.
26. Beaumont A, Hayasaki K, Marmarou A, Barzó P, Fatouros P, Corwin F. The effects of dopamine on edema formation in two models of traumatic brain injury. *Acta Neurochir.* 2000;76 Suppl:147–51.
27. Unterberg AW, Stroop R, Thomale UW, Kiening KL, Pauser S, Vollmann W. Characterisation of brain edema following “controlled cortical impact injury” in rats. *Acta Neurochir.* 1997;70 Suppl:106–8.
28. Barzó P, Marmarou A, Fatouros P, Ito J, Corwin F. MRI diffusion-weighted spectroscopy of reversible and irreversible ischemic injury following closed head injury. *Acta Neurochir.* 1997;70 Suppl:115–8.
29. Van Putten HP, Bouwhuis MG, Muizelaar JP, Lyeth BG, Berman RF. Diffusion-weighted imaging of edema following traumatic brain injury in rats: effects of secondary hypoxia. *J Neurotraum.* 2005;22:857–72.
30. Huisman TA, Sorensen AG, Hergan K, Gonzalez RG, Schaefer PW. Diffusion-weighted imaging for the evaluation of diffuse axonal injury in closed head injury. *J Comput Assist Tomogr.* 2003;27:5–11.
31. Schaefer P, Trevisky A, Gonzalez R. Echo planar diffusion weighted imaging in diffuse axonal injury. In: *Proceedings of the 36th annual meeting of the American Society of Neuroradiology.* 1998.
32. Schaefer PW, Huisman TA, Sorensen AG, Gonzalez RG, Schwamm LH. Diffusion-weighted MR imaging in closed head injury: high correlation with initial glasgow coma scale score and score on modified Rankin scale at discharge. *Radiology.* 2004;233:58–66.
33. Liu AY, Maldjian JA, Bagley LJ, Sinson GP, Grossman RI. Traumatic brain injury: diffusion-weighted MR imaging findings. *Am J Neuroradiol.* 1999;20:1636–41.
34. Hou DJ, Tong KA, Ashwal S, Oyoyo U, Joo E, Shutter L, et al. Diffusion-weighted magnetic resonance imaging improves outcome prediction in adult traumatic brain injury. *J Neurotrauma.* 2007;24:1558–69.
35. Marmarou A, Portella G, Barzó P, Signoretti S, Fatouros P, Beaumont A, et al. Distinguishing between cellular and vasogenic edema in head injured patients with focal lesions using magnetic resonance imaging. *Acta Neurochir.* 2000;76 Suppl:349–51.
36. Marmarou A, Signoretti S, Fatouros PP, Portella G, Aygok GA, Bullock MR. Predominance of cellular edema in traumatic brain swelling in patients with severe head injuries. *J Neurosurg.* 2006;104:720–30.
37. Pasco A, Ter Minassian A, Chapon C, Lemaire L, Franconi F, Darabi D, et al. Dynamics of cerebral edema and the apparent diffusion coefficient of water changes in patients with severe traumatic brain injury. A prospective MRI study. *Eur Radiol.* 2006;16:1501–8.
38. Goetz P, Blamire A, Rajagopalan B, Cadoux-Hudson T, Young D, Styles P. Increase in apparent diffusion coefficient in normal appearing white matter following human traumatic brain injury correlates with injury severity. *J Neurotrauma.* 2004;21:645–54.
39. Nakahara M, Ericson K, Bellander B. Diffusion-weighted MR and apparent diffusion coefficient in the evaluation of severe brain injury. *Acta Radiol.* 2001;42:365–9.