



IMAGES IN INTENSIVE MEDICINE

Spontaneous multivisceral cholesterol crystal embolism presenting as *livedo reticularis*☆



Embolismo espontáneo multivisceral por cristales de colesterol, manifestado por *livedo reticularis*

P. Carmona Sánchez^{a,*}, M.T. González Serrano^b, J.M. Serrano Simón^a

^a Unidad de Cuidados Intensivos, Hospital Universitario Reina Sofía, Córdoba, Spain

^b Departamento de Patología, Hospital Universitario Reina Sofía, Córdoba, Spain

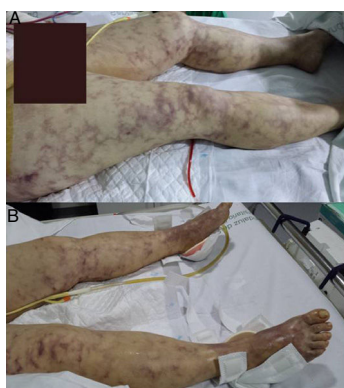

Figure 1 Image of *livedo reticularis* on the lower extremities, first 24 h of admission. Skin involvement comprising the upper abdomen, hips, buttocks and both feet, with "blue toes". The image at top shows drainage after emergency laparotomy with splenectomy, gastrectomy and pancreatectomy due to multivisceral infarcts.

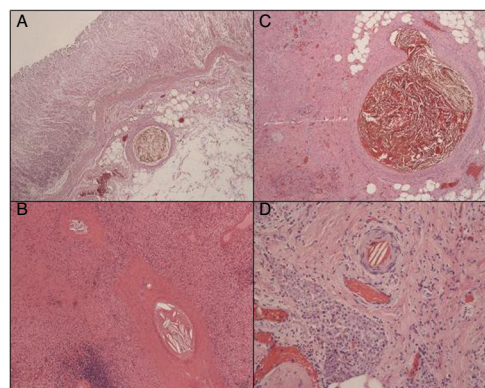


Figure 2 Histopathology: cholesterol crystals within the lumen of the small arterioles. (A) Gastric. (B) Splenic. (C) Pancreatic. (D) Cutaneous (hematoxylin-eosin, 10×).

A 47-year-old hypertensive woman was admitted to the Intensive Care Unit due to abdominal pain and shock with violet macular skin rash (Fig. 1). Laboratory testing revealed normal leukocyte and renal function values, with lactic acid 4.4 mmol/l. The abdominal CAT scan revealed splenic, pancreatic and focal hepatic attenuation. Emergency laparotomy was performed, revealing multivisceral infarcts and necrosis. Splenectomy, distal pancreatectomy and gastrectomy were performed. The biopsy revealed the presence of cholesterol crystal emboli (CCE) (Fig. 2). Full patient recovery was achieved. The mortality rate of CCE can reach 65%. Affected patients usually have a history of cardiovascular procedures or anticoagulant-fibrinolytic treatments, which was not seen in our patient. We present an infrequent case of spontaneous CCE manifesting as *livedo reticularis* and multivisceral infarcts. The skin involvement can suggest CCE, though vasculitis and neoplastic processes must be discarded. The skin lesion biopsy can confirm the diagnosis and facilitate curative surgical management.

☆ Please cite this article as: Carmona Sánchez P, González Serrano MT, Serrano Simón JM. Embolismo espontáneo multivisceral por cristales de colesterol, manifestado por *livedo reticularis*. Med Intensiva. 2018;42:e4.

© 2018 by Elsevier España, S.L.U. and SEMICYUC. All rights reserved.

E-mail addresses: purisympa@hotmail.com, jm.serranosimon@gmail.com (P. Carmona Sánchez).