



## IMAGES IN INTENSIVE MEDICINE

### Iatrogenic gastric emphysema<sup>☆</sup>

### Enfisema gástrico iatrogénico

Y. Corcía Palomo<sup>\*</sup>, L. Martín Villén, J.J. Egea Guerrero



Unidad de Cuidados Intensivos, Hospital Universitario Virgen del Rocío, Sevilla, Spain

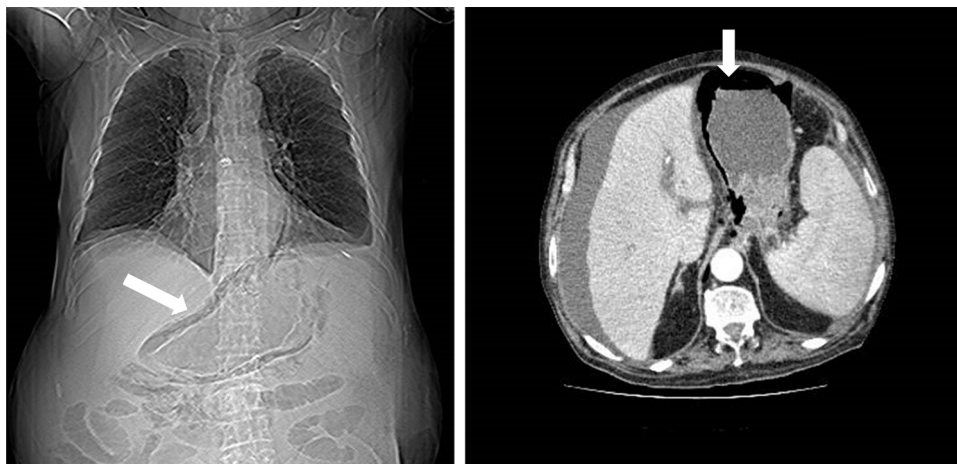


Figure 1 Topogram and axial acquisition.

A 78-year-old male smoker was admitted to the Intensive Care Unit due to severe acute pancreatitis. Endoscopic retrograde cholangiopancreatography was performed, with the detection of tearing of the esophageal mucosa. The thoracic computed tomography scan showed dissection of the wall of the middle-distal third of the esophagus and stomach due to air (Fig. 1 white arrow in the topogram and axial image). Esophageal perforation was evidenced in the operating room. Gastric emphysema is secondary to rupture of the digestive mucosa, producing dissection of the gastric wall. This condition must be distinguished from emphysematous gastritis, where the presence of intramural air is secondary to gas-producing bacterial infection, and has a poorer prognosis.

<sup>☆</sup> Please cite this article as: Corcía Palomo Y, Martín Villén L, Egea Guerrero JJ. Enfisema gástrico iatrogénico. Med Intensiva. 2018;42:e9.

<sup>\*</sup> Corresponding author.

E-mail address: [yaelcorcia@gmail.com](mailto:yaelcorcia@gmail.com) (Y. Corcía Palomo).