



IMAGES IN INTENSIVE MEDICINE

Analysis of three cases of diffuse alveolar hemorrhage: False-negative results in pulmonary ultrasound[☆]



Análisis de 3 casos de hemorragia alveolar difusa: resultados falsos negativos en la ecografía pulmonar

L.A. Gorordo Delsol^{a,*}, A. Jiménez Ruiz^b, G.D. Hernández López^a

^a Unidad de Cuidados Intensivos Adultos, Hospital Juárez de México, Mexico City, Mexico

^b Servicio de Urgencias, IMSS Hospital General de Zona # 25 «Ignacio Zaragoza», Mexico City, Mexico

We will be reviewing the cases of three (3) women hospitalized at one polyvalent ICU with a diagnosis of systemic erythematosus lupus (SEL) and diffuse alveolar hemorrhage (DAH). One point-of-care ultrasound device with a 3.5 MHz convex transducer was used in the supine position with the patients' heads inclined in a 30° angle and four (4) areas in each hemithorax were assessed, three (3) with mechanical ventilatory support. The lung pattern was "A" in the eight (8) areas assessed. Images 1A, 2A and 3A correspond to the Pulmonary ultrasound on right sector 3 (superior and lateral) and show the two-dimensional mode (B) with "A" lines and motion mode (M)–the "seashore" sign; panels B and C correspond to the simple CT scan and the X-ray (point-of-care, same position). The normal finding would be the alveolar-interstitial pattern with a great amount of "B" lines due to subpleural air entrapment in DAH and heterogeneous distribution, which leads to false negatives (Fig. 1).

[☆] Please cite this article as: Gorordo Delsol LA, Jiménez Ruiz A, Hernández López GD. Análisis de 3 casos de hemorragia alveolar difusa: resultados falsos negativos en la ecografía pulmonar. *Med Intensiva*. 2018;42:e7–e8.

* Corresponding author.

E-mail address: luis.gorordodelsol@icloud.com (L.A. Gorordo Delsol).

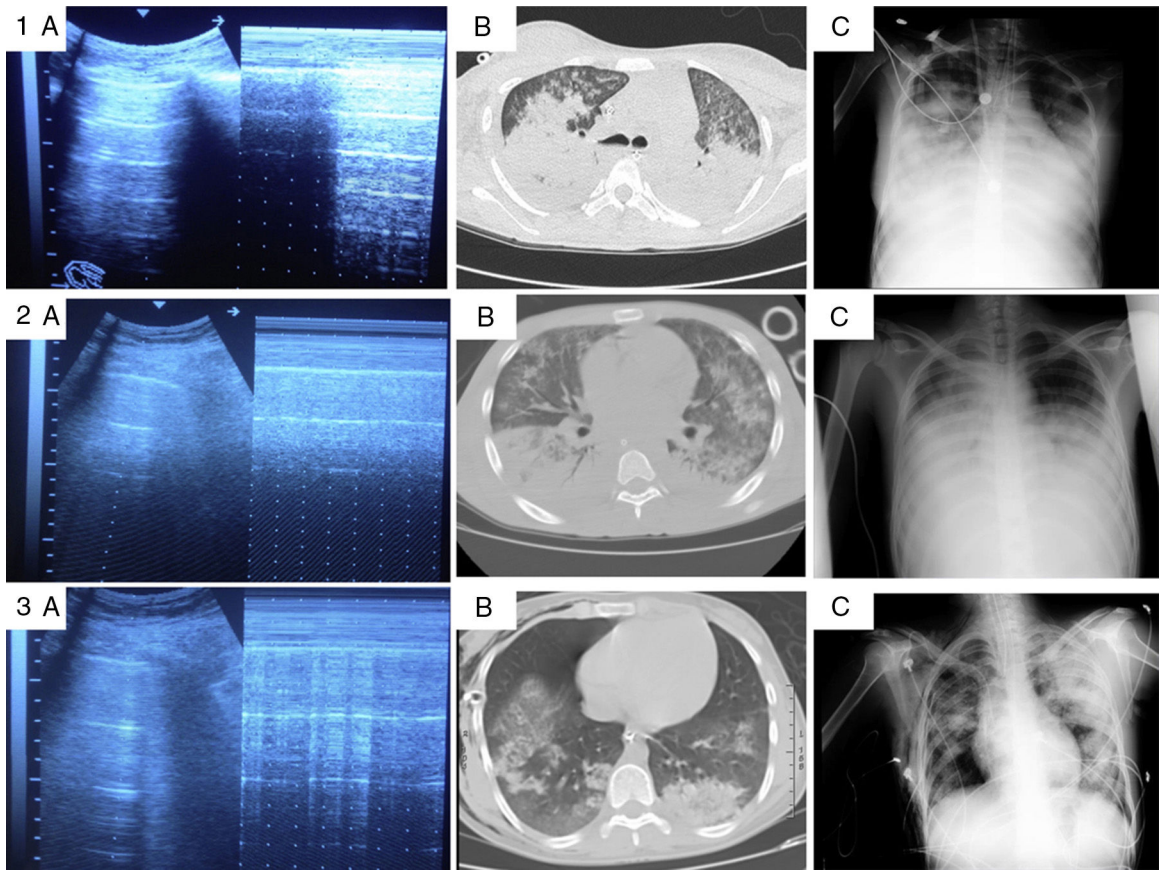


Figure 1