



## IMAGES IN INTENSIVE MEDICINE

### Pneumocoles in out-hospital methicillin-sensitive *Staphylococcus aureus* pneumonia ☆



### Neumatocoles en una neumonía extrahospitalaria por *Staphylococcus aureus* sensible a meticilina

A. Padilla-Serrano <sup>a,\*</sup>, T. Vizuete-Medrano <sup>a</sup>, J. González-Spínola <sup>b</sup>

<sup>a</sup> Unidad de Cuidados Intensivos, Hospital General La Mancha Centro, Alcázar de San Juan, Ciudad Real, Spain

<sup>b</sup> Servicio de Radiodiagnóstico, Hospital General La Mancha Centro, Alcázar de San Juan, Ciudad Real, Spain

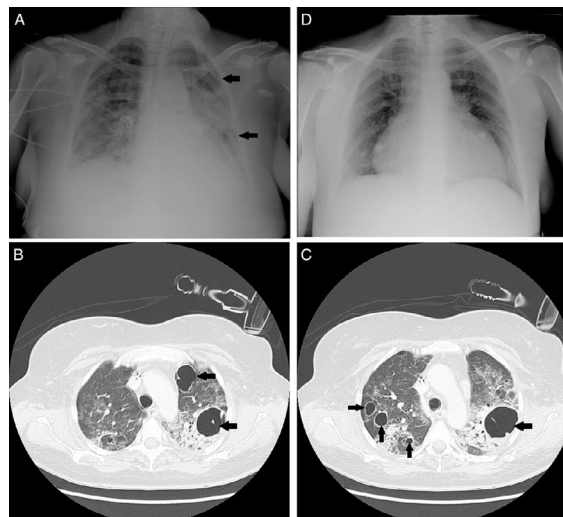


Figure 1

Forty-eight-year-old woman without a significant medical history admitted to the intensive care unit (ICU) due to community-acquired pneumonia by methicillin-sensitive *Staphylococcus aureus* that required invasive mechanical ventilation. After 13 days one anteroposterior chest X-ray (Fig. 1A) shows one smooth, thin walled radiolucent lesion without hydroaerial level in the basal segment of the superior lobe of left lung and in inferior lobe of the same lung. The CT scan (Fig. 1B and c) confirms the presence of new-onset thin walled multiple round radiolucent lesions consistent with pneumatocele.

The management of pneumatocele is that of the underlying condition, which is why our patient was prescribed one cycle of 14 days on cloxacillin, 2 g every 6 h. In most cases, pneumatocele regresses spontaneously (Fig. 1D) and long-term pulmonary function is normal.

☆ Please cite this article as: Padilla-Serrano A, Vizuete-Medrano T, González-Spínola J. Neumatocoles en una neumonía extrahospitalaria por *Staphylococcus aureus* sensible a meticilina. Med Intensiva. 2018;42:e15.

\* Corresponding author.

E-mail address: [apadilla@jccm.es](mailto:apadilla@jccm.es) (A. Padilla-Serrano).