



IMAGES IN INTENSIVE MEDICINE

Propofol-induced non-convulsive epileptic crisis[☆]

Crisis epiléptica no convulsiva inducida por propofol

A. Zabalegui^{a,*}, M. Arroyo Diez^a, R.A. Peláez Cruz^b



^a Servicio de Medicina Intensiva, Hospital Universitario de Burgos, Burgos, Spain

^b Servicio de Neurofisiología Clínica, Hospital Universitario de Burgos, Burgos, Spain

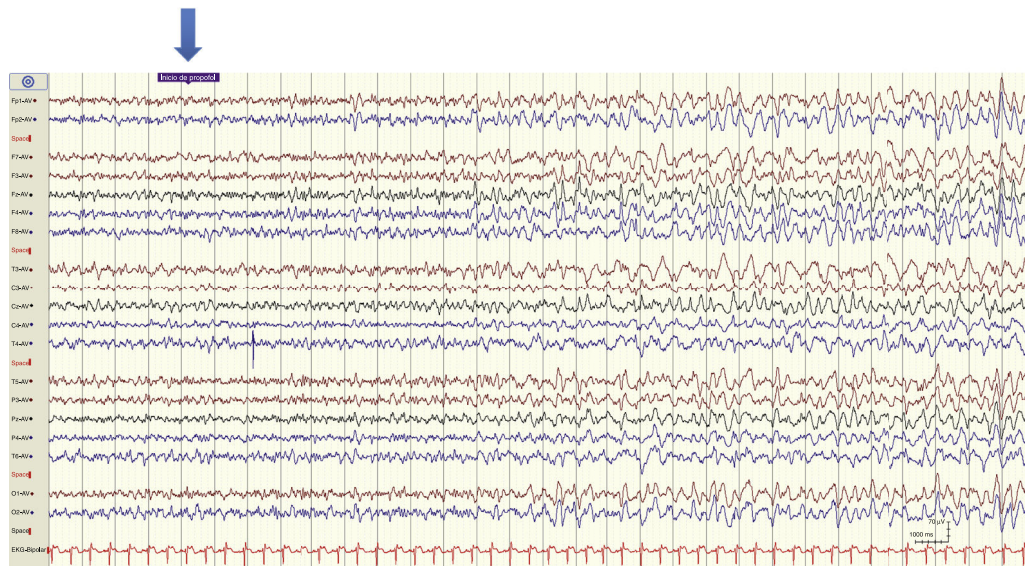


Figure 1

Patient admitted to the ICU due to idiopathic super-refractory status epilepticus monitored through EEG and bilateral BIS simultaneously.

[☆] Please cite this article as: Zabalegui A, Arroyo Diez M, Peláez Cruz RA. Crisis epiléptica no convulsiva inducida por propofol. Med Intensiva. 2018;42:e13–e14.

* Corresponding author.

E-mail address: azabalegui@saludcastillayleon.es (A. Zabalegui).

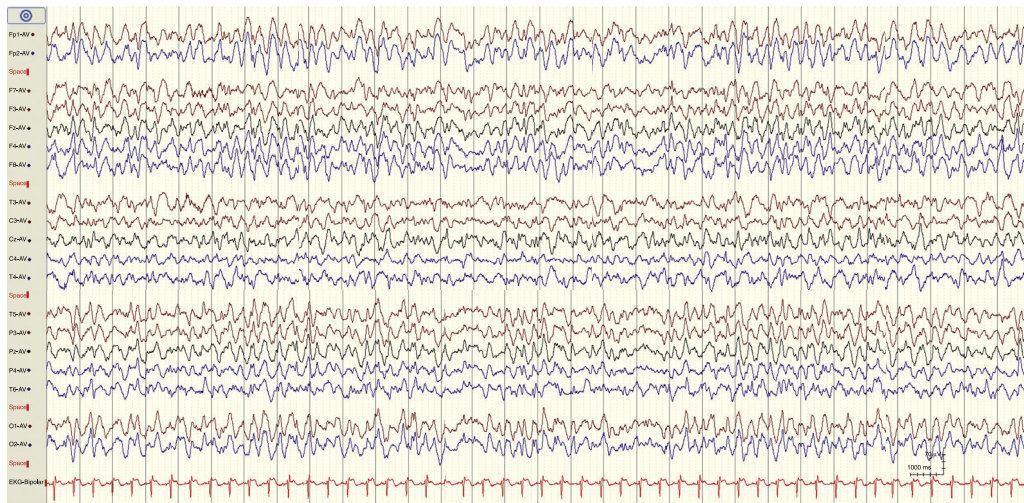


Figure 2

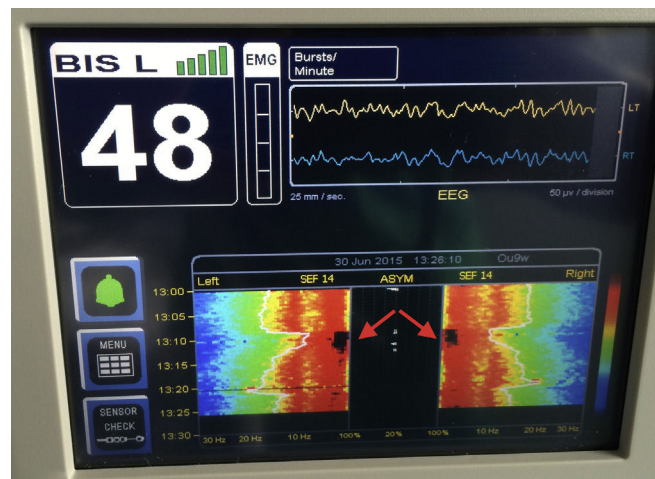


Figure 3

The basal EEG shows low-amplitude mixed activity with isolated epileptiform discharges in frontocentral regions. After the administration of one 20 mg bolus of IV propofol (Fig. 1, blue arrow) we can see an increased epileptiform activity evolving towards rhythmic acute slow-wave pattern at 2–3 Hz (Fig. 2).

The density spectral array of bilateral BIS, from 13:09 to 13:13h, shows a dark brown self-limited interval (Fig. 3, red arrows) consistent with the rhythmic pattern at 2–3 Hz (both the BIS value and the EEG were taken at 13:26 h).

The pattern is consistent with non-convulsive epileptic seizure that regressed spontaneously in 4 min.