



## SCIENTIFIC LETTERS

### Arrhythmic storm solved with ExtraCorporeal Membrane Oxygenation and consecutive percutaneous coronary intervention and ventricular tachycardia ablation<sup>☆</sup>



### Tormenta arrítmica resuelta tras angioplastia y ablación bajo soporte con oxigenación de membrana extracorpórea venoarterial

Dear Editor,

The arrhythmic storm due to sustained monomorphic ventricular tachycardia (SMVT) is a life-threatening condition in which the catheter ablation procedure is key for management purposes, especially in the presence of a scar.<sup>1,2</sup> Similarly, it is advisable to look for the presence of coronary ischemia and proceed to correct it.<sup>2</sup> Yet none of these procedures is risk-free, especially in the presence of hemodynamic instability or severe ventricular dysfunction. In this paper we will see an example of the utility of ECMO in this clinical scenario.

A seventy-year-old male was admitted to our center ER after receiving three (3) discharges from his automatic implantable cardiac defibrillator (AICD). He had a prior history of diabetes and arterial hypertension. Also, ten (10) years ago he suffered from an episode of SMVT with a left ventricle ejection fraction (LVEF) of 30%, chronic occlusion of his right and circumflex coronary arteries with lack of viability in such territories based on the single photon emission computed tomography (SPECT) scan, which is why an AICD was implanted followed by amiodarone.

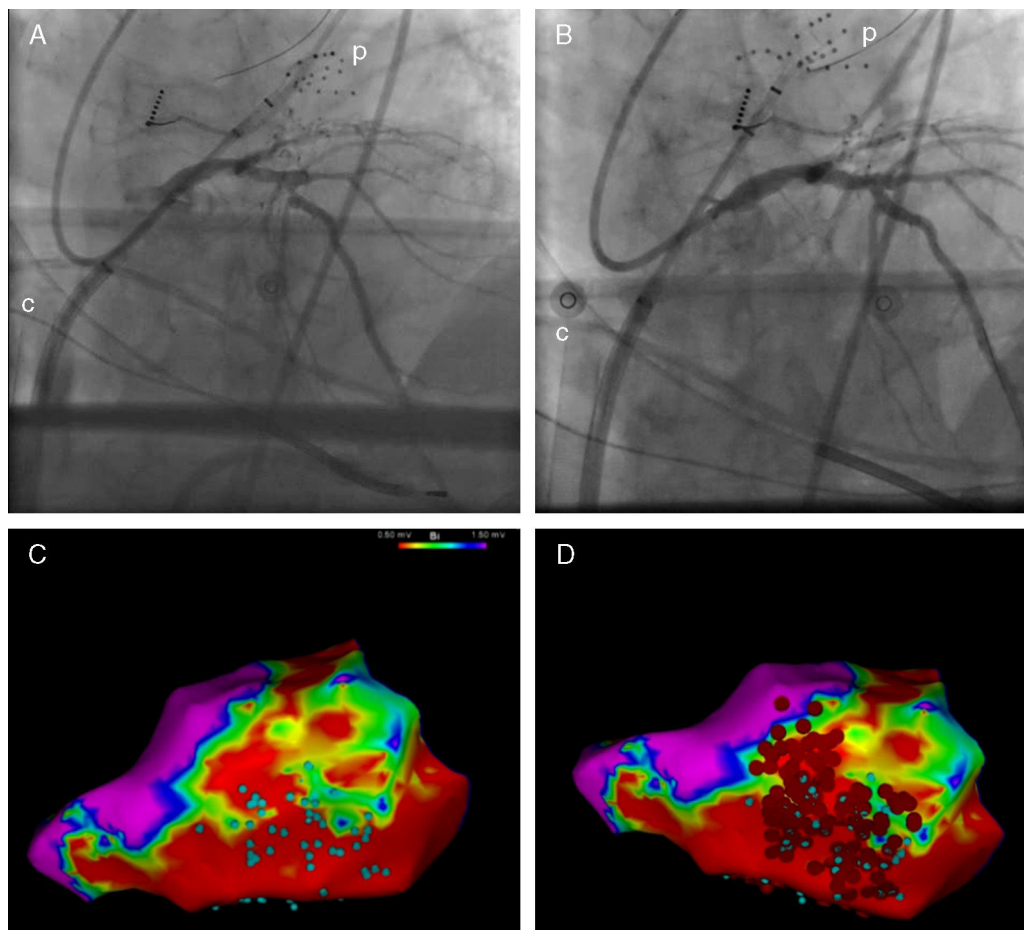
The patient was admitted to the Acute Cardiology Care Unit, his AICD checked, and then it was confirmed that the discharges had been appropriate following an episode of SMVT. While the patient was being monitored, common self-limiting episodes of such arrhythmias were seen, which is why treatment with procainamide in perfusion was prescribed and the AICD therapies disconnected.

This time, the echocardiogram showed a LVEF of 25% and the coronariography showed one severe de novo lesion in the proximal anterior descending artery. After heart-team discussion of the case, it was decided to revascularize the anterior descending artery and perform the ablation of the SMVT. Both were high-risk procedures, which is why hemodynamic support with venoarterial ECMO was taken into consideration.

The intervention was conducted at the electrophysiology lab with intubation, sedation with Propofol, analgesia with remifentanyl and cisatracurium for muscle relaxation. In the first place, the left ventricle was accessed using the transeptal puncture technique; then one IV bolus dose of heparin was administered with ECMO support percutaneous implantation through the femoral approach. The Cardiohelp<sup>®</sup> device was used (Maquet, Germany), with a 15F arterial cannula and a 23F venous cannula. The ECMO support was initiated with 1.5 bpm and with the possibility of increasing flow if necessary. The next step was to treat the stenosis of the anterior descending artery by implanting one drug-eluting stent (Fig. 1A and B). During this revascularization, the arterial blood pressure dropped and pulsatility disappeared, which is why the ECMO flow was brought to 3 bpm in order to keep the average blood pressure above 60 mmHg. This situation was maintained for another 15 min due to myocardial stunning, after which pulsatility slowly recovered. And that is when the ablation started. Endocardial voltage mapping during sinus rhythm was created using one multidetector-row catheter with the CARTO<sup>®</sup> 3 system (Biosense Webster Inc., USA); 1.5 and 0.5 mV were the voltage limits used to define scar and dense scar. Also, inside the scar, electrogram areas with isolated or potentially delayed components (Fig. 1C) were identified. During the scheduled pacing no SMVTs were induced, but ventricular fibrillation was induced that had to be terminated through defibrillation. Once again, we saw that after the shock a period of several minutes of hypotension and loss of pulsatility followed, during which the ECMO support was increased. Finally, one arrhythmic substrate extensive ablation procedure was conducted (Fig. 1D).

After finishing the procedure, the patient remained hemodynamically stable and with a good pulse amplitude, which is why it was decided to remove the circulatory support system. The decannulation was conducted in the lab by the vascular surgeon with vein and femoral artery repair. The patient's progression was favorable without SMVT recurrences, and he was discharged from the hospital five (5) days after the procedure.

<sup>☆</sup> Please cite this article as: Sousa-Casasnovas I, Ávila-Alonso P, Juárez-Fernández M, Díez-Delhoyo F, Martínez-Sellés M, Fernández-Avilés F. Tormenta arrítmica resuelta tras angioplastia y ablación bajo soporte con oxigenación de membrana extracorpórea venoarterial. Med Intensiva. 2018;42:504–506.



**Figure 1** Pre- (A) and postoperative coronary intervention fluoroscopy (B). Endocardial voltage mapping showing inferior–lateral scar. Electrogram areas with isolated or potentially delayed components (C, blue dots) and ablation sites (D, red dots). c: ECMO venous cannula; p: electrophysiology mapping and imaging catheter.

The case presented here shows the benefits that circulatory support can provide in the management of arrhythmic storms. This support can be necessary in cases of incessant forms of arrhythmia and hemodynamic instability, and also as the back-up of high-risk therapeutic interventions. In particular, the patient described above had a high-risk coronary anatomy with a significant lesion in his only patent blood vessel, which elevated the risk of the revascularization and the ablation procedure.

Today, there are several hemodynamic support devices available to conduct high-risk percutaneous procedures: counter-pulsation balloon, TandemHeart®, Impella®, venoarterial ECMO.<sup>3</sup> Of all, the ECMO support guarantees a full circulatory support and a minimum interference when manipulating the catheters. There is prior experience using ECMO support in percutaneous revascularization procedures, in the implantation of percutaneous valves, and in the ablation of arrhythmias,<sup>3–6</sup> and it has also been used for the hemodynamic rescue of arrhythmic storms.<sup>6,7</sup> On the other hand, ECMO implantation, initially surgical, has evolved toward percutaneous cannulation, making it a useful tool fully available for all hemodynamic and electrophysiology labs.<sup>8,9</sup>

Our case illustrates the possibilities of ECMO in the circulatory support of percutaneous devices. Also, it has the

peculiarity of being the first case ever reported in medical literature where two (2) consecutive procedures (coronary revascularization and ablation) were conducted with short-term support with the advantage of reducing health care time and avoiding second cannulations.

## References

1. Arenal A, Glez-Torrecilla E, Ortiz M, Villacastín J, Fdez-Portales J, Sousa E, et al. Ablation of electrograms with an isolated, delayed component as treatment of unmappable monomorphic ventricular tachycardias in patients with structural heart disease. *J Am Coll Cardiol.* 2003;41:81–92.
2. Priori SG, Blomstrom-Lundqvist C, Mazzanti A, Blom N, Borggrefe M, Camm J, et al. 2015 ESC guidelines for the management of patients with ventricular arrhythmias and the prevention of sudden cardiac death. *Eur Heart J.* 2015;36:2793–867.
3. Naidu SS. Novel percutaneous cardiac assist devices: the science of and indications for hemodynamic support. *Circulation.* 2011;123:533–43.
4. Seco M, Forrest P, Jackson SA, Martinez G, Andvik S, Bannon PG, et al. Extracorporeal membrane oxygenation for very high-risk transcatheter aortic valve implantation. *Heart Lung Circ.* 2014;23:957–62.

5. Tsao NW, Shih CM, Yeh JS, Kao YT, Hsieh MH, Ou KL, et al. Extracorporeal membrane oxygenation-assisted primary percutaneous coronary intervention may improve survival of patients with acute myocardial infarction complicated by profound cardiogenic shock. *J Crit Care.* 2012;27, 530 e1–e11.
6. Rizkallah J, Shen S, Tischenko A, Zieroth S, Freed DH, Khadem A. Successful ablation of idiopathic left ventricular tachycardia in an adult patient during extracorporeal membrane oxygenation treatment. *Can J Cardiol.* 2013;29:174117–9.
7. Baratto F, Pappalardo F, Oloriz T, Bisceglia C, Vergara P, Silberbauer J, et al. Extracorporeal membrane oxygenation for hemodynamic support of ventricular tachycardia ablation. *Circ Arrhythm Electrophysiol.* 2016;9:e004492.
8. Díez-Villanueva P, Sousa I, Núñez A, Díez F, Elízaga J, Fernández-Avilés F. Tratamiento precoz del shock cardiogénico refractario mediante implante percutáneo de ECMO venoarterial en el laboratorio de hemodinámica. *Rev Esp Cardiol.* 2014;67:1059–61.
9. Díez-Delhoyo F, Sousa-Casasnovas I, Juárez M, Elízaga J, Martínez-Sellés M, Fernández-Avilés F. Tratamiento del infarto agudo de miocardio con ECMO: más allá del balón de contrapulsación. *Med Intensiva.* 2016;40:518–20.

I. Sousa-Casasnovas\*, P. Ávila-Alonso, M. Juárez-Fernández, F. Díez-Delhoyo, M. Martínez-Sellés, F. Fernández-Avilés

*Servicio de Cardiología, Hospital General Universitario Gregorio Marañón, Madrid, Spain*

\* Corresponding author.

*E-mail address:* [iagosousa@yahoo.es](mailto:iagosousa@yahoo.es) (I. Sousa-Casasnovas). 2173-5727/

© 2017 Elsevier España, S.L.U. and SEMICYUC. All rights reserved.

## Kounis syndrome or allergic infarction: A relatively unknown entity<sup>☆</sup>



### Síndrome de Kounis o infarto alérgico: una entidad desconocida

Dear Editor,

Kounis syndrome (KS) or allergic infarction was first described back in 1991 as the simultaneous appearance of an acute coronary syndrome (ACS) and an anaphylactic allergic reaction. Its incidence is still unknown, since most data come from small series of cases.<sup>1–10</sup> When it comes to its etiology, multiple trigger factors have been described such as drugs or food.<sup>3</sup>

We conducted one retrospective study including all patients admitted to our hospital Intensive Care Unit (including both the Polyvalent Intensive Care Unit and the Coronary Unit) due to anaphylactic reactions from 2007 through 2015 (a total of 11,780 admissions). This study was approved by our center research ethics committee. The goal was to know the incidence, characteristics, management and progression of the KS.

Twenty (20) patients were included, of which nine (9) (45%) suffered allergic infarctions (Table 1), which amounts to an incidence rate of six (6) cases for every 1000 admissions-year. The average age was 63 years old (range 59–77); 66.7% of the cases showed some cardiovascular risk factor, although only one (1) patient had a prior history of ACS. All cases showed ST-segment elevation: the inferior territory was the most commonly damaged territory followed by the anterior territory or by simultaneous damage to both territories. None of the patients of our series was

treated with thrombolysis; 77% of the patients showed elevated markers of myocardial damage (high-sensitive cardiac troponin T [normal hs-cTnT 0–14 pg/mL] and creatine phosphokinase [normal CK 26–140 UI/L]), yet the hs-cTnT was significantly higher (mean 133, range 10–567) than the CK (mean 96, range 35–859). Only two (2) patients (cases 7 and 9) showed ventricular dysfunction, one of them in the context of the Tako-Tsubo syndrome, but somehow unrelated to the acute coronary occlusion that was also present in two (2) cases. In the cases with ventricular dysfunction, such dysfunction resolved during follow-up. During the average follow-up of  $39.7 \pm 28.6$  months no deaths were reported or major cardiovascular events.

Using the Student's *t*-test for mean-comparison or the  $\chi^2$ -test for proportion-comparison and yet despite the limitation due to the number of patients and after checking the adjustment of a normal distribution using the Kolmogorov–Smirnov's test, one comparative analysis was conducted with the anaphylactic reaction without allergic infarction. There were no statistically significant differences except for age: the youngest patients were those without KS and on treatment with adrenaline, that was most commonly used in the latter (Table 2).

The sudden onset of thoracic pain followed by allergic symptoms should be suspicious of KS and, in our series, a considerable number of patients with anaphylactic shock who were admitted to the ICU showed clinical manifestations compatible with an allergic infarction.

There are three (3) types of KS that appear in our series. Type I occurs in patients without coronary disease and the most likely mechanism is vasospastic disorder or microvascular damage.<sup>2</sup> In type II there is preexisting atheromatous disease and erosion, or acute tear of the plaque induced by the release of mediators of anaphylaxis.<sup>1–6</sup> The last one, type III, is described as somehow related to the thrombosis of a stent previously implanted.<sup>5</sup>

As it occurs in our series, the ECG usually shows the ST-segment elevation in inferior and anterior leads<sup>2,8</sup> and it is essential not only for its diagnosis, but also to establish a cause-effect correlation with the possible trigger factor. Added to the usual lab conclusions of ACS, an immune-allergic study should be conducted here<sup>3</sup> including tryptase, histamine, complement, eosinophils and IgE.<sup>2,7,8</sup>

<sup>☆</sup> Please cite this article as: Barrionuevo Sánchez MI, Corbí Pascual MJ, Córdoba Soriano JG, Ramírez Guijarro C, Calero Nuñez S, Gallego Sánchez G. Síndrome de Kounis o infarto alérgico: una entidad desconocida. *Med Intensiva.* 2018;42:506–509.