



IMAGES IN INTENSIVE MEDICINE

Pulmonary edema ex vacuo after drainage of pneumothorax[☆]



Edema pulmonar *ex vacuo* tras drenaje de neumotórax

E. Chicote Álvarez^{*}, M. Arlabán Carpintero, A. González-Castro

Servicio de Medicina Intensiva, Hospital Universitario Marqués de Valdecilla, Santander, Cantabria, Spain

Seventy-two-year-old patient with a clinical history of sleep apnea–hypopnea treated with nocturnal continuous positive airway pressure (CPAP) who presents to the ER complaining of exertional progressive dyspnea and chest pain of one week–duration. The chest X-ray conducted confirms the presence of left pneumothorax (Fig. 1A). One anterior thoracic tube was placed connected to negative aspiration at -25 cm of H_2O from the moment it was inserted with abundant outflow of air. It is then that the patient initiated a more significant work of breathing. The X-ray showed pulmonary re-expansion with edema occupying the entire left lung (Fig. 1B). The patient was then admitted to the hospital intensive care unit (ICU) and high-flow nasal cannula (HFNC) oxygen therapy was initiated. The patient’s progression was favorable, the HFNC oxygen therapy was withdrawn, the plaque receded, and the patient was discharged from the ICU after eight (8) days. Re-expansion pulmonary edema after drainage of pneumothorax is an uncommon complication. Its appearance is favored by the application of elevated aspiration from the moment the drainage tube is inserted, therefore, the use of negative aspiration should be avoided right from the start after placing the thoracic tube, especially in tension pneumothorax. Treatment is basically support treatment, both respiratory and oxygen-therapy, and the use of positive end-expiratory pressure (PEEP) can also be considered as hemodynamic approach.

[☆] Please cite this article as: Chicote Álvarez E, Arlabán Carpintero M, González-Castro A. Edema pulmonar *ex vacuo* tras drenaje de neumotórax. Med Intensiva. 2018;42:e24–e25.

^{*} Corresponding author.

E-mail address: chicotelogro@hotmail.com (E. Chicote Álvarez).

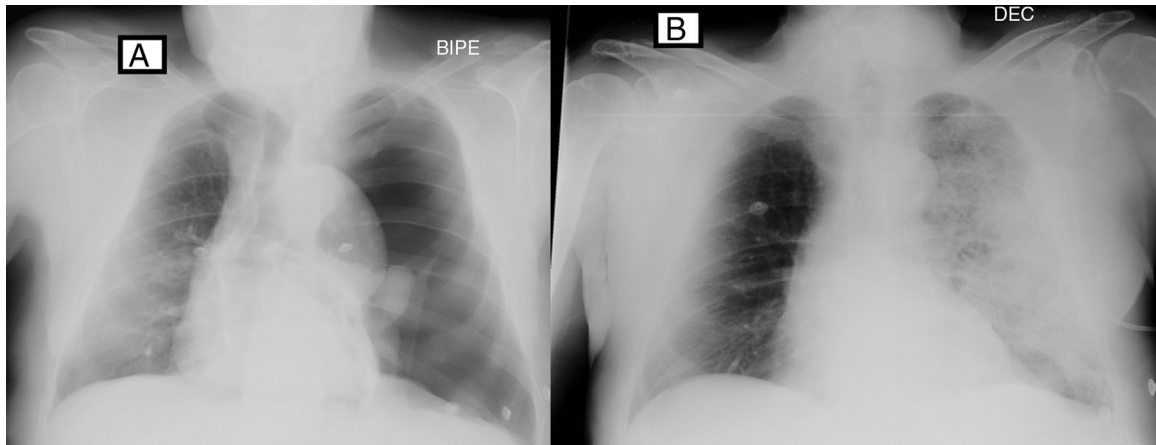


Figure 1