



IMAGES IN INTENSIVE MEDICINE

Disappearance of cerebral diastolic flow after an unexpected complication ☆



Desaparición del flujo diastólico cerebral tras una complicación inesperada

M. Arroyo Diez^{a,*}, A. Zabalegui Pérez^a, G. Kaminsky^b

^a Servicio de Medicina Intensiva, Hospital Universitario de Burgos, Burgos, Spain

^b Servicio de Medicina Intensiva, Hospital de Fuenlabrada, Fuenlabrada, Madrid, Spain

Available online 9 April 2019

A 43-year-old woman presented with headache of sudden onset. The CT scan revealed left parietal-occipital hemorrhage over an underlying lesion with partial herniation. The Glasgow coma score (GCS) was 15 until day four, when she presented right anisocoria and GCS 3. Osmotherapy was started, with sedation, mechanical ventilation,

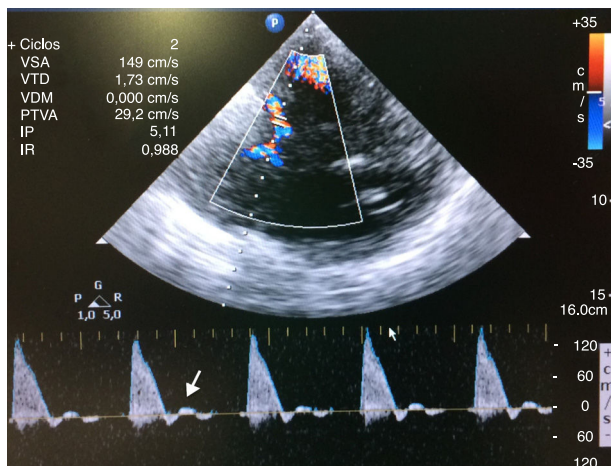


Figure 1 Transcranial color-coded duplex ultrasound recording. Systolic flow in left middle cerebral artery. Note the absence of diastolic flow (white arrow).

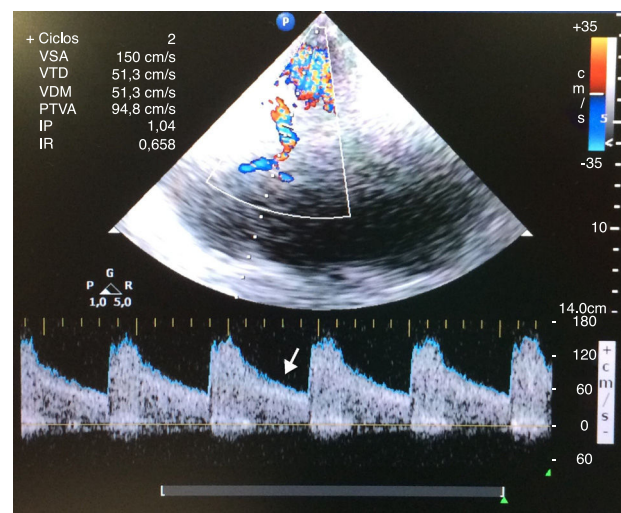


Figure 2 Transcranial color-coded duplex ultrasound recording. After evacuation of the pneumothorax, the diastolic wave was recovered in the left middle cerebral artery (white arrow).

hyperventilation and the placement of a right subclavian catheter, followed by resolution of the anisocoria, with a bispectral index (BIS) of 40 (CT discarded repeat bleeding). A few minutes later an intracranial pressure (ICP) sensor was placed (65 mmHg), the BIS dropped to 0 and transcranial Doppler ultrasound showed systolic flow with no diastolic wave (Fig. 1). Reversion was not achieved with first level measures. After discarding other causes of elevated ICP, a chest X-ray for catheter control (still pending) was obtained, revealing an iatrogenic right-side tension pneumothorax (PT). After evacuating the PT, the pupils normalized, as did middle cerebral arterial flow (Fig. 2), BIS and ICP.

☆ Please cite this article as: Arroyo Diez M, Zabalegui Pérez A, Kaminsky G. Desaparición del flujo diastólico cerebral tras una complicación inesperada. *Med Intensiva*. 2019;43:259.

* Corresponding author.

E-mail address: martaarroyo84@hotmail.com (M. Arroyo Diez).