

## Stellate ganglion block as rescue therapy in refractory vasospasm after subarachnoid hemorrhage<sup>☆</sup>



### Bloqueo del ganglio estrellado como terapia de rescate en el vasoespasm refractario tras hemorragia subaracnoidea

Dear Editor:

Vasospasm-induced late brain ischemia is one complication of aneurysmal subarachnoid hemorrhage (SAH) that can be present in 30% of the patients and is associated with high morbimortality.<sup>1</sup> A small percentage of cases do not respond to the recommended treatment with induced hypertension or interventional procedures such as brain angioplasty and the infusion of intraarterial vasodilators, and to this day there are no effective options available when all these therapies fail. We hereby describe a case of refractory vasospasm where stellate ganglion anesthetic block was used with good results.

Sixty-one-year-old patient without a significant medical history admitted due to sudden headache, nausea, and photophobia of 4-day duration due to SAH (WFNS III) following one ruptured aneurysm in the anterior communicating artery. Upon the patient's arrival to the ER, he showed right hemiparesis with brachial predominance and dysphasia that was recovered after the IV administration of nimodipine, fluid therapy, and noradrenaline. Twenty-four hours after admission, one coronary arteriography was conducted followed by the adequate embolization of the aneurysm. During the test, the presence of significant vasospasm was confirmed and it was treated with the local infusion of 2 mg of nimodipine in both anterior cerebral arteries and left middle cerebral artery (MCA), and in the left pericallosal artery where 2 additional mg of nimodipine were instilled followed by one balloon angioplasty with good final angiographic results. After completing the procedure, the presence of 3/5 hemiparesis was confirmed in the patient's right arm without dysphasia that improved after increasing the arterial blood pressure.

The following 48 h included left focality-related fluctuating events and evidence of severe vasospasms in the transcranial Doppler (TCD) ultrasound with mean velocities of up to 250 cm/s in the left MCA and Lindgaard ratio > 3. On the third day, the angiography was repeated with a new infusion of 8 mg of nimodipine but this time with partial results. The computed tomography scan performed revealed the presence of one small left frontal ischemic lesion. Due to the lack of clinical improvement (right arm paralysis and dysphasia), the Pain Treatment Unit was contacted to perform one left cervical stellate ganglion block procedure

that was conducted 4 days after admission and under X-ray imaging (Fig. 1). One bolus of 10 ml of bupivacaine at 0.5% was administered and one IV cannula was inserted for the repeated administration of the drug every 12 h. Thirty minutes after the block, the right arm partially recovered its strength and the naming of objects improved as well. At that time, the TCD confirmed that mean velocity was reduced 10% in the left MCA (Fig. 2A and B) and that it gradually decreased over the following hours. After 3 days on bupivacaine (6 doses), the patient showed minimum brachial claudication, and no speech disorder. Cervical block was removed without symptom relapse and reduced velocity on the TCD ultrasound of up to 70% with respect to its highest value.

The pathophysiology of cerebral vasospasm is still under discussion but there are numerous theories on this issue: prolonged arterial vasoconstriction, vasoactive neuropeptide release, structural changes in the arterial wall or an exaggerate inflammatory response.<sup>2,3</sup> If not diagnosed early, the narrowing of the arterial lumen can increase vascular resistance and reduce blood flow to the brain leading to irreversible cerebral ischemia. There are several factors associated with the appearance of vasospasm. Among the most important ones we find the volume of blood flow in the subarachnoid space (Fisher grading scale), the neurological status on admission (the Hunt-Hess scale or WFNS scales) and the size and location of the aneurysm.<sup>4</sup>

According to the last recommendations established by the AHA,<sup>5</sup> in the presence of focal symptoms indicative of vasospasm, treatment should be based on inducing hypertension (class I, level B) and using intravascular techniques through cerebral angioplasty and/or selective infusion of intraarterial vasodilators (class IIIa, level B). No study recommends the use of any other therapies with enough level of evidence. In cases of vasospasm refractory to these treatments, several different options have been suggested such as the intrathecal administration of vasodilating drugs, the use of a continuous perfusion of intraarterial nimodipine or the stellate ganglion block.<sup>6,7</sup>

The stellate ganglion regulates the sympathetic tone of head, neck, and upper extremities; its anesthetic block is indicated to control neuropathic pain, in cases of phantom limb pain, hyperhidrosis or vascular failure of upper extremities such as Raynaud's phenomenon due to its vasodilating effect.<sup>8</sup> The stellate ganglion block has been used successfully for the management of refractory vasospasm in isolated cases or series of cases; these show that, after the stellate ganglion block using a local anesthetic (usually bupivacaine), there is clinical improvement with partial or complete recovery of neurologic deficit since there is more blood flow coming to the cerebral arteries that are ipsilateral to the block being this effect more significant in younger patients.<sup>9,10</sup>

In order to perform this technique an adequate anatomical knowledge is essential. We should be paying attention here to the correlation between the cervical sympathetic ganglion chain and other muscle structures (scalene muscles; longus colli muscle, etc.), the esophagus, the trachea, and the neurovascular bundle (recurrent laryngeal nerve, subclavian and vertebral arteries). The technique is ultrasound-or-fluoroscopy guided. The longus colli mus-

<sup>☆</sup> Please cite this article as: Sánchez Arguiano J, Hernández-Hernández MA, Jáuregui Solórzano RA, Maldonado-Vega S, González Mandly A, Burón Mediavilla J. Bloqueo del ganglio estrellado como terapia de rescate en el vasoespasm refractario tras hemorragia subaracnoidea. *Med Intensiva*. 2019;43:437-439.

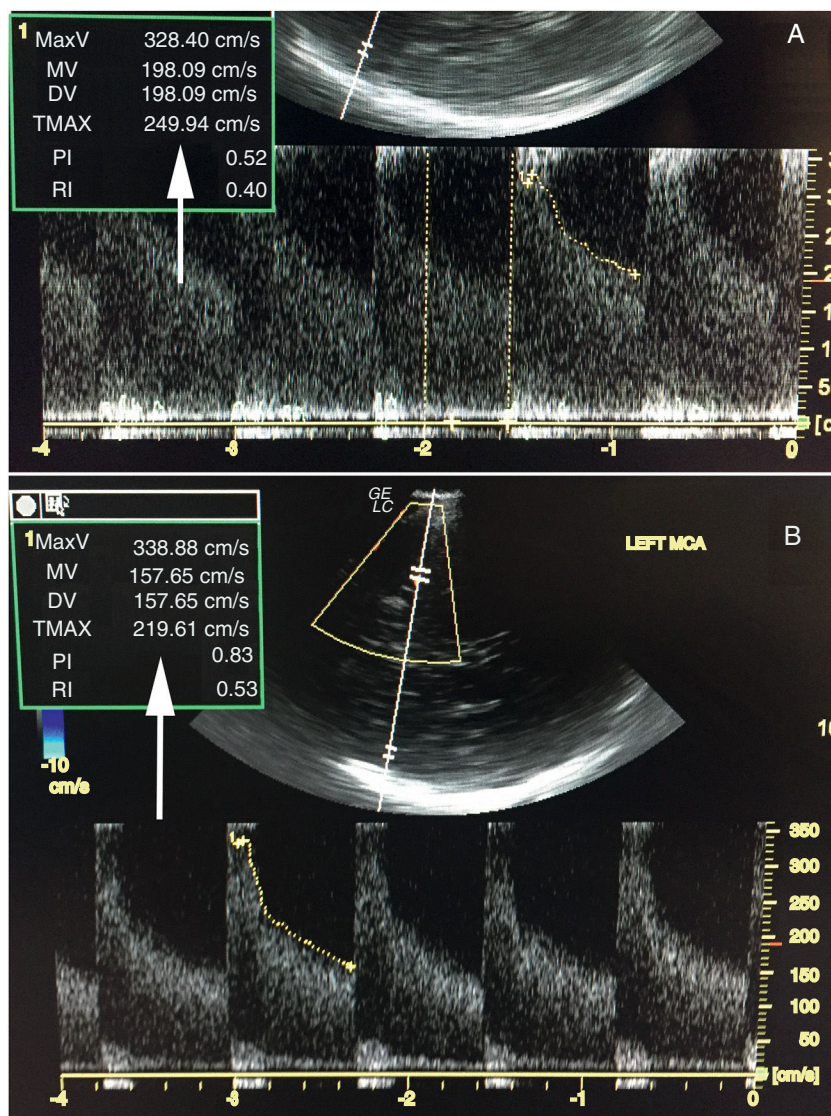


Figure 1 Measurement of mV in left MCA. TCD ultrasound before the block (A) and after the block (B).

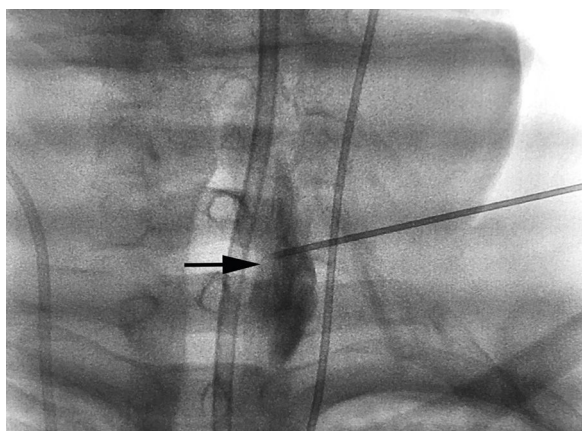


Figure 2 Block technique under X-ray imaging.

cle is the muscle reference, it is lateral to the ganglion and it is between 5 mm and 10 mm thick in the C6, and 8 mm and 10 mm thick in the C7. After the block, the denervation of head and neck structures occurs. The signs suggestive of successful blocks are the unilateral appearance of Horner's syndrome, anhidrosis, nasal congestion (Guttman's sign), conjunctival congestion, vein dilatation, and temperature increases of at least 1 °C.<sup>6</sup> This technique has few complications such as dysphonia or dysphagia, damage to the brachial plexus, hematomas, phrenic nerve block or epidural injection of the drug.

In sum, our case confirms that the stellate ganglion block may be a useful technique as a second-line therapy for the management of SAH-related late cerebral ischemia, especially when the vasospasm is of unilateral predominance.

## References

- Durrant JC, Hinson HE. Rescue therapy for refractory vasospasm after subarachnoid hemorrhage. *Curr Neurol Neurosci Rep.* 2015;15:521.
- Mejía JA, Niño de Mejía MC, Ferrer LE, Cohen D. Vasoespasmo cerebral secundario a hemorragia subaracnoidea por ruptura de aneurisma intracerebral. *Rev Col Anest.* 2007;35:143–65.
- Van Lieshout JH, Dibué-Adjei M, Cornelius JF, Slotty PJ, Schneider T, Restin T, et al. An introduction to the pathophysiology of aneurysmal subarachnoid hemorrhage. *Neurosurg Rev.* 2017;1:1–14, <http://dx.doi.org/10.1007/s10143-017-0827-y>.
- Findlay J, Darsaut T. Medical management of cerebral vasospasm. In: Winn H, editor. *Youmans and Winn neurological surgery.* 7th ed. Philadelphia: Elsevier; 2017. p. 3274–84.
- Hemphill JC 3rd, Greenberg SM, Anderson CS, et al. Guidelines for the management of spontaneous intracerebral hemorrhage: a guideline for healthcare professionals from the American Heart Association/American Stroke Association. *Stroke.* 2015;46:2032–60.
- Caplan JM, Colby GP, Coon AL, Huang J, Tamargo RJ. Managing subarachnoid hemorrhage in the neurocritical care unit. *Neurosurg Clin N Am.* 2013;24:321–37.
- Adamczyk P, He S, Amar AP, et al. Medical management of cerebral vasospasm following aneurysmal subarachnoid hemorrhage: a review of current and emerging therapeutic interventions. *Neurol Res Int.* 2013;462–91.
- Serna-Gutiérrez J. Bloqueo del ganglio estrellado guiado por ultrasonografía. *Rev Colomb Anestesiología.* 2015;43:278–82.
- Nie Y, Song R, Chen W, Qin Z, Zhang J, Tang J. Effects of stellate ganglion block on cerebrovascular vasodilation in elderly patients and patients with subarachnoid haemorrhage. *Br J Anaesth.* 2016;117:131–2.
- Jain V, Rath GP, Dash H, Bithal PK, Chouhan RS, Suri A. Stellate ganglion block for treatment of cerebral vasospasm in patients with aneurysmal subarachnoid hemorrhage—a preliminary study. *Anaesthesiol Clin Pharmacol.* 2011;27:516–21.

J. Sánchez Arguiano<sup>a,\*</sup>, M.A. Hernández-Hernández<sup>a</sup>, R.A. Jáuregui Solórzano<sup>a</sup>, S. Maldonado-Vega<sup>b</sup>, A. González Mandly<sup>c</sup>, J. Burón Mediavilla<sup>a</sup>

<sup>a</sup> Servicio de Medicina Intensiva, Hospital Universitario Marqués de Valdecilla, Santander, Spain

<sup>b</sup> Servicio de Anestesiología, Hospital Universitario Marqués de Valdecilla, Santander, Spain

<sup>c</sup> Servicio de Radiología Intervencionista, Hospital Universitario Marqués de Valdecilla, Santander, Spain

Corresponding author.

E-mail addresses: [o414@humv.es](mailto:o414@humv.es), [mjuncalsar@gmail.com](mailto:mjuncalsar@gmail.com) (J. Sánchez Arguiano).

2173-5727/

© 2017 Elsevier España, S.L.U. and SEMICYUC. All rights reserved.

## Renal replacement therapy in severe phenobarbital poisoning: Another brick in the wall



### Diálisis extracorpórea en el caso de grave fenobarbital envenenamiento: otro ladrillo en la pared

Dear Editor,

The prevalence of severe poisoning with sedatives or hypnotics has been increasing dramatically over the last years.<sup>1</sup> In this setting, barbiturates remain one of the most common classes of drugs associated with fatal poisoning. The current report aims at illustrating the usefulness of renal replacement therapy with intermittent hemodialysis in the acute care of massive phenobarbital poisoning.

A 56-year old woman was addressed to the intensive care unit (ICU) for a massive phenobarbital poisoning (assumed ingested dose: 5.5 g). The estimated maximum delay between phenobarbital ingestion and ICU admission was 6 hours. The patient presented with hypotension (77/44 mmHg), hypothermia (33 °C) and altered mental status (Glasgow Coma Scale: 3) requiring endotracheal intubation, fluid loading with 1000 mL of saline and noradrenalin infusion up to 0.33 µg/kg/min before ICU admission. Her neurological examination revealed bilateral mydriasis with no pupillary response, together with the disappearance of other brainstem reflexes. A trans-thoracic echocardiography showed preserved left ventricle ejection fraction and car-

diac output consistent with a vasoplegic shock. In spite of the profound coma and respiratory depression, there was no evidence for aspiration. The diagnosis of massive phenobarbital poisoning was confirmed by high barbiturate plasma levels measured upon admission (273 mg/L).

Initial management of barbiturate poisoning included supportive care of organ failures (*i.e.*, mechanical ventilation and noradrenalin infusion), the administration of activated charcoal (a single 1 g/kg dose) so that to limit the enterohepatic recirculation of barbiturates, together with urinary alkalinization in an attempt to increase their urinary excretion. On day-1, hemodynamic improvement allowed for noradrenalin discontinuation. Yet, the neurological examination was no significantly improved (GCS: 3), except for a spontaneous breathing activity under mechanical ventilation. Multiple-dose activated charcoal (MDAC) was introduced on day-2, with no significant decrease in plasma phenobarbital levels or neurological improvement (Fig. 1). On day-4, because the patient was still deeply comatose, renal replacement therapy (RRT) initiation was decided. Intermittent dialysis was performed using an Artis Physio™ dialysis system (Gambro AB, Meyzieu, France) with a Sureflux™-19E dialyzer (Nipro Europe, Saint Beauzire, France), achieving an estimated average creatinine clearance of 188 mL/min. A 4-hour session allowed for dramatically reducing plasma phenobarbital levels from 313 to 125 mg/L. The second dialysis session, performed on day-5, further reduced plasma levels from 129 to 47 mg/L (Fig. 1). The patient awoke twenty-four hours after RRT initiation, as illustrated by an increase in the Richmond Agitation-Sedation Scale from –5 (patient unarousable) to