

References

- Durrant JC, Hinson HE. Rescue therapy for refractory vasospasm after subarachnoid hemorrhage. *Curr Neurol Neurosci Rep.* 2015;15:521.
- Mejía JA, Niño de Mejía MC, Ferrer LE, Cohen D. Vasoespasmo cerebral secundario a hemorragia subaracnoidea por ruptura de aneurisma intracerebral. *Rev Col Anest.* 2007;35:143–65.
- Van Lieshout JH, Dibué-Adjei M, Cornelius JF, Slotty PJ, Schneider T, Restin T, et al. An introduction to the pathophysiology of aneurysmal subarachnoid hemorrhage. *Neurosurg Rev.* 2017;1:1–14, <http://dx.doi.org/10.1007/s10143-017-0827-y>.
- Findlay J, Darsaut T. Medical management of cerebral vasospasm. In: Winn H, editor. *Youmans and Winn neurological surgery.* 7th ed. Philadelphia: Elsevier; 2017. p. 3274–84.
- Hemphill JC 3rd, Greenberg SM, Anderson CS, et al. Guidelines for the management of spontaneous intracerebral hemorrhage: a guideline for healthcare professionals from the American Heart Association/American Stroke Association. *Stroke.* 2015;46:2032–60.
- Caplan JM, Colby GP, Coon AL, Huang J, Tamargo RJ. Managing subarachnoid hemorrhage in the neurocritical care unit. *Neurosurg Clin N Am.* 2013;24:321–37.
- Adamczyk P, He S, Amar AP, et al. Medical management of cerebral vasospasm following aneurysmal subarachnoid hemorrhage: a review of current and emerging therapeutic interventions. *Neurol Res Int.* 2013;462–91.
- Serna-Gutiérrez J. Bloqueo del ganglio estrellado guiado por ultrasonografía. *Rev Colomb Anestesiología.* 2015;43:278–82.
- Nie Y, Song R, Chen W, Qin Z, Zhang J, Tang J. Effects of stellate ganglion block on cerebrovascular vasodilation in elderly patients and patients with subarachnoid haemorrhage. *Br J Anaesth.* 2016;117:131–2.
- Jain V, Rath GP, Dash H, Bithal PK, Chouhan RS, Suri A. Stellate ganglion block for treatment of cerebral vasospasm in patients with aneurysmal subarachnoid hemorrhage—a preliminary study. *Anaesthesiol Clin Pharmacol.* 2011;27:516–21.

J. Sánchez Arguiano^{a,*}, M.A. Hernández-Hernández^a, R.A. Jáuregui Solórzano^a, S. Maldonado-Vega^b, A. González Mandly^c, J. Burón Mediavilla^a

^a Servicio de Medicina Intensiva, Hospital Universitario Marqués de Valdecilla, Santander, Spain

^b Servicio de Anestesiología, Hospital Universitario Marqués de Valdecilla, Santander, Spain

^c Servicio de Radiología Intervencionista, Hospital Universitario Marqués de Valdecilla, Santander, Spain

Corresponding author.

E-mail addresses: o414@humv.es, mjuncalsar@gmail.com (J. Sánchez Arguiano).

2173-5727/

© 2017 Elsevier España, S.L.U. and SEMICYUC. All rights reserved.

Renal replacement therapy in severe phenobarbital poisoning: Another brick in the wall



Diálisis extracorpórea en el caso de grave fenobarbital envenenamiento: otro ladrillo en la pared

Dear Editor,

The prevalence of severe poisoning with sedatives or hypnotics has been increasing dramatically over the last years.¹ In this setting, barbiturates remain one of the most common classes of drugs associated with fatal poisoning. The current report aims at illustrating the usefulness of renal replacement therapy with intermittent hemodialysis in the acute care of massive phenobarbital poisoning.

A 56-year old woman was addressed to the intensive care unit (ICU) for a massive phenobarbital poisoning (assumed ingested dose: 5.5 g). The estimated maximum delay between phenobarbital ingestion and ICU admission was 6 hours. The patient presented with hypotension (77/44 mmHg), hypothermia (33 °C) and altered mental status (Glasgow Coma Scale: 3) requiring endotracheal intubation, fluid loading with 1000 mL of saline and noradrenalin infusion up to 0.33 µg/kg/min before ICU admission. Her neurological examination revealed bilateral mydriasis with no pupillary response, together with the disappearance of other brainstem reflexes. A trans-thoracic echocardiography showed preserved left ventricle ejection fraction and car-

diac output consistent with a vasoplegic shock. In spite of the profound coma and respiratory depression, there was no evidence for aspiration. The diagnosis of massive phenobarbital poisoning was confirmed by high barbiturate plasma levels measured upon admission (273 mg/L).

Initial management of barbiturate poisoning included supportive care of organ failures (*i.e.*, mechanical ventilation and noradrenalin infusion), the administration of activated charcoal (a single 1 g/kg dose) so that to limit the enterohepatic recirculation of barbiturates, together with urinary alkalinization in an attempt to increase their urinary excretion. On day-1, hemodynamic improvement allowed for noradrenalin discontinuation. Yet, the neurological examination was no significantly improved (GCS: 3), except for a spontaneous breathing activity under mechanical ventilation. Multiple-dose activated charcoal (MDAC) was introduced on day-2, with no significant decrease in plasma phenobarbital levels or neurological improvement (Fig. 1). On day-4, because the patient was still deeply comatose, renal replacement therapy (RRT) initiation was decided. Intermittent dialysis was performed using an Artis Physio™ dialysis system (Gambro AB, Meyzieu, France) with a Sureflux™-19E dialyzer (Nipro Europe, Saint Beauzire, France), achieving an estimated average creatinine clearance of 188 mL/min. A 4-hour session allowed for dramatically reducing plasma phenobarbital levels from 313 to 125 mg/L. The second dialysis session, performed on day-5, further reduced plasma levels from 129 to 47 mg/L (Fig. 1). The patient awoke twenty-four hours after RRT initiation, as illustrated by an increase in the Richmond Agitation-Sedation Scale from –5 (patient unarousable) to

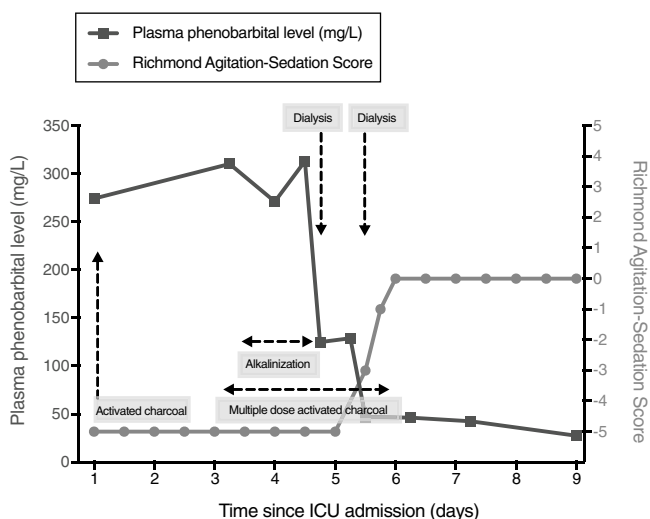


Figure 1 Time course of phenobarbital plasma levels (left y-axis) and patient consciousness (Richmond Agitation-Sedation Scale, right y-axis). There was a dramatic decrease in phenobarbital plasma levels after two hemodialysis sessions, concomitant with neurological status improvement.

0 (patient alert and calm) (Fig. 1). The clinical course was eventually favorable, allowing for the patient to be successfully extubated on day-7 and discharged to a psychiatric unit on day-10.

We herein report a case of massive phenobarbital poisoning with a favorable course under intermittent hemodialysis. Medical interventions to enhance phenobarbital elimination (activated charcoal and urinary alkalization) had failed to improve the neurological status of our patient. Also, this strategy did not significantly alter phenobarbital plasma levels. In a previous study, the administration of repeated doses of activated charcoal enhanced the elimination of barbiturates but had no clear effect on clinical outcome.² Furthermore, activated charcoal could hypothetically increase the risk of gastric impaction. This may partially explain the variation in serum concentrations during the initial course (between day-1 and day-4), as phenobarbital is a long-acting barbiturate. Regarding urinary alkalization, there is to date no clinical evidence of a clinical benefit in barbiturate poisoning, despite its pharmacokinetic rationale.³

In the current case, RRT with intermittent hemodialysis dramatically improved the clearance of phenobarbital and, hence, neurological status improved concomitantly. Two 4-hour sessions were sufficient to achieve a dramatic reduction in phenobarbital levels. Hemodialysis was discontinued after neurological status improved, rather than targeting a specific concentration. All barbiturates are inducers of the hepatic cytochrome P450 and hepatic metabolism is the main component of their endogenous clearance. Barbiturates are thus classified according to their pharmacokinetic properties. Long-acting barbiturates (such as phenobarbital) have a smaller volume of distribution, which tends to limit post-dialysis rebound, and are less protein-bound and lipid soluble than short-acting barbiturates. Importantly, up to 20–25% of phenobarbital can be excreted as an active drug in urine. During dialysis, phenobarbital clearance has been

shown to vary from 150 to 200 mL/min.⁴ For all these reasons, long-acting barbiturates are theoretically dialyzable. A few case studies have reported the effectiveness of both hemoperfusion^{5,6} and hemodialysis^{7,8} to enhance the clearance of barbiturates. Yet, these two techniques have not been evaluated and compared in randomized control trials. Hemoperfusion is not widely available and requires a specific training. As compared to hemoperfusion, hemodialysis has been shown to be associated with a lower risk of thrombocytopenia or hypocalcemia and seems less costly.⁹ The 2015 recommendations of the EXTRIP Workgroup suggest using intermittent hemodialysis to treat long-acting barbiturate poisoning in case of prolonged coma, shock (after initial fluid resuscitation), or persistence of toxicity despite MDAC.¹⁰

This case provides further support for the early initiation of renal replacement therapy in patients admitted for severe long-acting barbiturates poisoning, especially in those with prolonged coma and/or persistence of toxicity despite multiple-dose activated charcoal.

Funding

This research received no specific grant from any funding agency, commercial or not-for-profit sectors.

Conflict of interests

The authors have no conflicts of interest to declare.

References

- Mowry JB, Spyker DA, Brooks DE, Zimmerman A, Schauben JL. 2015 Annual Report of the American Association of Poison Control Centers' National Poison Data System (NPDS): 33rd Annual Report. *Clin Toxicol*. 2016;54:924–1109.
- Pond SM, Olson KR, Osterloh JD, Tong TG. Randomized study of the treatment of phenobarbital overdose with repeated doses of activated charcoal. *JAMA*. 1984;251:3104–8.
- Frenia ML, Schauben JL, Wears RL, Karlix JL, Tucker CA, Kunisaki TA. Multiple-dose activated charcoal compared to urinary alkalization for the enhancement of phenobarbital elimination. *J Toxicol Clin Toxicol*. 1996;34:169–75.
- Palmer BF. Effectiveness of hemodialysis in the extracorporeal therapy of phenobarbital overdose. *Am J Kidney Dis*. 2000;36:640–3.
- Lin J-L, Jeng L-B. Critical, acutely poisoned patients treated with continuous arteriovenous hemoperfusion in the emergency department. *Ann Emerg Med*. 1995;25:75–80.
- Bouma AW, van Dam B, Meynaar IA, Peltenburg HG, Walenbergh-van Veen MCM. Accelerated elimination using hemoperfusion in a patient with phenobarbital intoxication. *Ned Tijdschr Geneesk*. 2004;148:1642–5.
- Primo Botti, Garcia P, Dannoui B, Pistelli A. Hemodialysis vs forced alkaline diuresis in acute barbiturate poisoning. *Clin Toxicol (Phila)*. 2004;42:518.
- Srinivas S, Karanth S, Nayyar V. Does it matter how we treat phenobarbitone overdose of moderate severity? *Indian J Crit Care Med*. 2004;8:153.
- Bouchard J, Lavergne V, Roberts DM, Cormier M, Morissette G, Ghannoum M. Availability and cost of extracorporeal treatments for poisonings and other emergency indications: a worldwide survey. *Nephrol Dial Transplant Off Publ Eur Dial Transpl Assoc Eur Ren Assoc*. 2017;32:699–706.

10. Mactier R, Laliberté M, Mardini J, Ghannoum M, Lavergne V, Gosselin S, et al. Extracorporeal Treatment for barbiturate poisoning: recommendations from the EXTRIP Workgroup. *Am J Kidney Dis.* 2014;64:347–58.

A. Bedet^{a,b,*}, A. Alestra^c, D. Vodovar^d,
A. Mekontso Dessap^{a,b}, N. de Prost^{a,b}

^a *Service de Réanimation Médicale, AP-HP, Hôpitaux Universitaires Henri Mondor, DHU A-TVB, Créteil, France*

^b *Groupe de recherche clinique CARMAS, Université Paris Est Créteil, Faculté de Médecine, Créteil, France*

^c *Service d'Accueil des Urgences, AP-HP, Hôpitaux Universitaires Henri Mondor, DHU A-TVB, Créteil, France*
^d *Service de Réanimation Chirurgicale Cardio Vasculaire, AP-HP, Hôpitaux Universitaires Henri Mondor, DHU A-TVB, Créteil, France*

*Corresponding author.

E-mail address: alexandre.bedet@aphp.fr (A. Bedet).

0210-5691/

© 2017 Elsevier España, S.L.U. y SEMICYUC. All rights reserved.

Prognostic utility of the multiorgan failure scores and inotropic index in the postoperative of cardiac transplantation in children[☆]



Utilidad pronóstica de las puntuaciones de fallo multiorgánico y del índice inotrópico en el postoperatorio de trasplante cardíaco en niños

Dear Editor:

Patients who undergo heart transplants (HT) have many complications and multiorgan failure (MOF), which increases morbimortality.^{1,2} No studies so far have analyzed the impact of post-HT MOF in children. Some studies have shown the predictive value of THE inotropic index (II) in cardiac surgery^{3,4} and HT in children.⁵ The goal of this study was to analyze the prognostic utility of MOF scores and the II in HT in children in relation to mortality, the length of admission in the pediatric intensive care unit (PICU) and the duration of mechanical ventilation (MV).

One observational, retrospective, single-center study approved by the local ethics committee was conducted including 65 children (mean age, 57 months-old) admitted to the PICU after sustaining HTs between the years 2003 and 2014. The worst scores of clinical severity and MOF, Pediatric Logistic Organ Dysfunction (PELOD)⁶ and Pediatric Multiple Organ Dysfunction Score (PMODS),⁷ Pediatric Risk of Mortality III (PRISM III),⁸ Pediatric Index of Mortality 2 (PIM2)⁹ were estimated within the first 48 h after the transplant. The value of II = dopamine + dobutamine + 100 × adrenaline + 100 × noradrenaline + 10 × milrinone (all in μg/kg/min) + 10,000 × vasopressin (mU/kg/min) was estimated as well.^{3,4} We studied the correlation between the scores and PICU mortality and the length of the PICU stay and the duration of MV. In order to complete the statistical analysis, the chi-square test, Fisher's exact

test, Mann–Whitney *U* test, and Spearman's Rho tests were used. *P* values <.05 were considered statistically significant.

Fifty-point-eight percent (50.8%) had congenital heart disease, 47.7% cardiomyopathy, and 4.6% myocardial tumors. The PRISM III score was 12.6% (P25–P75: 3.5–25.9) and the PIM 2 score was 19% (P25–P75: 3.4–27.8). Other scores were: PELOD 11 (P25–P75: 2–13) and PMODS 5 (P25–P75: 3–8). The II was 22 (P25–P75: 15–36). There was a moderate correlation between the II and the PRISM III (*r* = .260; *P* = .036), PELOD (*r* = .370; *P* = .003), and PMODS scores (*r* = .300; *P* = .002) but not with the PIM2 scores (*r* = .300; *P* = .120).

Four patients died (6.2%) during the PICU admission, but only one due to MOF. There was no correlation whatsoever between the MOF scores or the clinical severity scores and mortality (Table 1). The II was significantly higher among dead children (Table 1). The mortality differences seen among children with II > 15 (8.1%) and < 15 (0%) were not statistically significant (*P* = .565). Children who died required ECMO and the extrarenal euration technique (ERET) more often than survivors did, yet the differences were only statistically significant with the ERET (Table 1). There was a moderate correlation between the II and clinical severity and MOF scores (except for PELOD) and the length of PICU admission and duration of MV (Table 2). Patients with II > 15 after the HT had the longest PICU stays.

Our study is the first one ever to study MOF in HTs performed in children. In our study, MOF scores were high although mortality was low (6.1%), similar to the one reported previously.^{2,4,5} We did not find a significant correlation between MOF and mortality although the fact that only 4 children died limits the statistical comparison.

In children who have undergone cardiac surgery, a correlation has been found between high II values and a higher mortality rate.^{3,4} Sanil and Aggarwal found that an II > 15 was associated with a higher mortality rate in 51 children after sustaining HTs.⁵ In our study, those patients who died had significantly higher IIs compared to survivors whereas all the children who died had II values > 15, which confirms the prognostic value of II after HT in children. However, the values of II were significantly higher than those found by Sanil and Aggarwal.⁵ On the other hand, we should take into consideration here that in children on ECMO, the II may underestimate the child's actual clinical severity since they may require lower doses of vasoactive drugs.

HT children with II values > 15 had the longest PICU stays which is consistent with what Sanil and Aggarwal

[☆] Please cite this article as: López J, Slöcker M, Heras E, Ríos D, Barrio L, Cebrián R, et al. Utilidad pronóstica de las puntuaciones de fallo multiorgánico y del índice inotrópico en el postoperatorio de trasplante cardíaco en niños. *Med Intensiva.* 2019;43:441–443.