



## IMAGES IN INTENSIVE MEDICINE

### Thrombus in transit in patient with COVID-19 pneumonia<sup>☆</sup>



### Trombo en tránsito en paciente con neumonía por COVID-19

R. Chalela<sup>a</sup>, M.P. Gracia-Arnillas<sup>b</sup>, R. Olivero-Soldevila<sup>c</sup>, A. Izquierdo-Marquisa<sup>c</sup>, M. Acer-Puig<sup>b</sup>, D.A. Rodríguez-Chiaradía<sup>a,\*</sup>

<sup>a</sup> Pulmonology Department, Hospital del Mar, Institut Hospital del Mar d'Investigacions Mèdiques (IMIM), Universitat Pompeu Fabra (UPF), CIBERES (ISCIII), Barcelona, Spain

<sup>b</sup> Intensive Care Unit, Hospital del Mar, Institut Hospital del Mar d'Investigacions Mèdiques (IMIM), Barcelona, Spain

<sup>c</sup> Cardiology Department, Hospital del Mar, Institut Hospital del Mar d'Investigacions Mèdiques (IMIM), Barcelona, Spain

Available online 10 September 2020

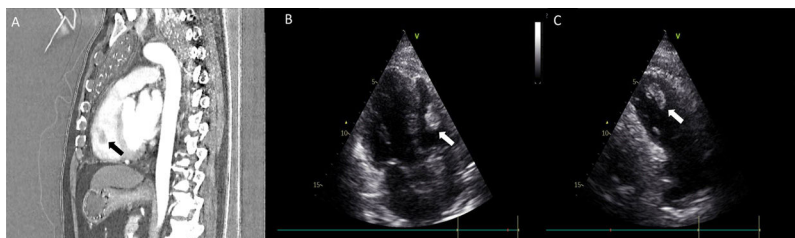


Figure 1

Sixty-two-year-old male patient with a diagnosis pneumonia due to SARS-CoV-2 infection in the hospitalization ward. Within the first 10 days the patient was treated with hydroxychloroquine, azithromycin, and enoxaparin at prophylactic doses and then with tocilizumab and methylprednisolone. On day 13 of the hospitalization (16 days since symptom onset), the patient remained with respiratory distress, severe hypoxemia, high D-dimer levels (>3000 ug/mL), and preserved hemodynamic stability. The computed tomography angiography performed revealed the presence of a pulmonary embolism in the right ventricle (Fig. 1A, black arrow). The echocardiogram confirmed the presence of a 2.4 cm thrombus in transit (Figure 1B and Figure C [white arrows] and supplementary data). The patient was then transferred to the intensive care unit where systemic fibrinolysis was performed with 100 mg of

alteplase. Forty-eight hours later, the patient was discharged without further complications

### Appendix A. Supplementary data

Supplementary material related to this article can be found, in the online version, at [doi:https://doi.org/10.1016/j.medin.2020.06.002](https://doi.org/10.1016/j.medin.2020.06.002).

<sup>☆</sup> Please cite this article as: Chalela R, Gracia-Arnillas MP, Olivero-Soldevila R, Izquierdo-Marquisa A, Acer-Puig M, Rodríguez-Chiaradía DA. Trombo en tránsito en paciente con neumonía por COVID-19. Med Intensiva. 2020;44:525.

\* Corresponding author.

E-mail address: [darodriguez@parcdesalutmar.cat](mailto:darodriguez@parcdesalutmar.cat) (D.A. Rodríguez-Chiaradía).