



ORIGINAL ARTICLE

Awake pronation with helmet continuous positive airway pressure for COVID-19 acute respiratory distress syndrome patients outside the ICU: A case series



G. Paternoster^a, C. Sartini^{b,*}, E. Pennacchio^c, F. Lisanti^c, G. Landoni^b, L. Cabrini^d

^a Cardiovascular Anesthesia and ICU, San Carlos Regional Hospital (San Carlo Azienda Ospedaliera Regionale), Potenza, Italy

^b Department of Anesthesia and Intensive Care, IRCCS San Raffaele Scientific Institute, Milan, Italy

^c Emergency Medicine San Carlo Hospital San Carlos Regional Hospital (San Carlo Azienda Ospedaliera Regionale), Potenza, Italy

^d Intensive Care and Anesthesia Unit, Ospedale di Circolo e Fondazione Macchi, Varese, Italy

Received 8 August 2020; accepted 11 August 2020

KEYWORDS

COVID-19;
SARS-COV-2;
Pandemic;
ARDS;
CPAP;
NIV;
Casco;
Pronation;
Prone position;
ARF;
Acute respiratory failure;
Dexmedetomidine

Abstract

Objective: Continuous positive airway pressure (CPAP) is an important therapeutic tool in COVID-19 acute respiratory distress syndrome (ARDS) since it improves oxygenation, reduces respiratory rate and can prevent intubation and intensive care unit (ICU) admission. CPAP during pronation has seldom been described and never during sedation.

Design: Case series.

Setting: High dependency unit of San Carlo University Hospital (Potenza, Italy).

Patients: Eleven consecutive patients with COVID-19 ARDS.

Intervention: Helmet CPAP in prone position after failing a CPAP trial in the supine position.

Main variable of interest: Data collection at baseline and then after 24, 48 and 72 h of pronation. We measured PaO₂/FIO₂, pH, lactate, PaCO₂, SpO₂, respiratory rate and the status of the patients at 28-day follow up.

Results: Patients were treated with helmet CPAP for a mean ± SD of 7 ± 2.7 days. Prone positioning was feasible in all patients, but in 7 of them dexmedetomidine improved comfort. PaO₂/FIO₂ improved from 107.5 ± 20.8 before starting pronation to 244.4 ± 106.2 after 72 h ($p < .001$). We also observed a significantly increase in SpO₂ from 90.6 ± 2.3 to 96 ± 3.1 ($p < .001$) and a decrease in respiratory rate from 27.6 ± 4.3 to 20.1 ± 4.7 ($p = .004$). No difference was observed in PaCO₂ or pH. At 28 days two patients died after ICU admission, one was discharged in the main ward after ICU admission and eight were discharged home after being successfully managed outside the ICU.

* Corresponding author.

E-mail address: sartini.chiara@hsr.it (C. Sartini).

Conclusions: Helmet CPAP during pronation was feasible and safe in COVID-19 ARDS managed outside the ICU and sedation with dexmedetomidine safely improved comfort. We recorded an increase in PaO₂/FiO₂, SpO₂ and a reduction in respiratory rate.

© 2020 Elsevier España, S.L.U. y SEMICYUC. All rights reserved.

PALABRAS CLAVE

COVID-19;
SARS-CoV-2;
Pandemia;
SDRA;
CPAP;
NIV;
Casco;
Pronación;
Posición prona;
Insuficiencia
respiratoria aguda;
Síndrome de
dificultad respiratoria
aguda;
Dexmedetomidina

Pronación en la planta en pacientes despiertos conectados a ventilación mecánica no invasiva y casco, con insuficiencia respiratoria aguda secundaria a COVID-19: una serie de casos

Resumen

Objetivo: La ventilación con presión positiva continua (CPAP) es una opción terapéutica útil en pacientes con síndrome de dificultad respiratoria aguda (SDRA) secundaria a infección por coronavirus 2019 (COVID-19) porque mejora la oxigenación, disminuye la frecuencia respiratoria y puede prevenir la intubación orotraqueal y así la admisión en la unidad de cuidados intensivos (UCI). El uso de la CPAP en pronación se ha descrito raramente, y nunca en pacientes con sedación superficial.

Diseño: Serie de casos.

Ámbito: Unidad de cuidados intensivos del Hospital San Carlo (Potenza, Italia).

Pacientes: Once casos consecutivos de pacientes con SDRA secundario a infección por COVID-19.

Intervenciones: Casco y CPAP y en posición de prono, después de fracasar una sesión de una hora de CPAP en posición supina.

Variables de interés principales: Datos clínicos registrados antes de iniciar la primera sesión de 12 h de pronación y a las 24, 48 y 72 h. Los datos registrados fueron PaO₂/FiO₂, pH, lactatos, PaCO₂, SpO₂, frecuencia respiratoria y visita de seguimiento a los 28 días.

Resultados: Todos los pacientes fueron tratados con CPAP y casco durante una media \pm DE de $7 \pm 2,7$. La posición de prono se realizó con éxito en los 11 pacientes, pero 7 pacientes recibieron dexmedetomidina para mejorar el confort.

El valor de PaO₂/FiO₂ mejoró desde $107,5 \pm 20,8$ antes de la pronación hasta $244,4 \pm 106,2$ después de 72 h ($p < 0,001$). Se observó un aumento significativo de la SpO₂ desde un basal de $90,6 \pm 2,3$ hasta $96 \pm 3,1$ a las 72 h ($p < 0,001$) y una reducción de la frecuencia respiratoria desde $27,6 \pm 4,3$ hasta $20,1 \pm 4,7$ ($p = 0,004$). No se observaron diferencias en los valores de PaCO₂ o de pH. A los 28 días dos pacientes habían fallecido, uno permanecía todavía ingresado en la planta después de la dimisión de la UCI y ocho fueron remitidos al domicilio después de ser tratados en la planta sin necesidad de ingreso en la UCI.

Conclusiones: La CPAP con casco durante la posición de prono fue segura y eficaz en pacientes con SDRA secundario a COVID-19 en la planta, y el uso de dexmedetomidina mejoró el confort. Se observó una mejora en los valores de PaO₂/FiO₂, de SpO₂ y de la frecuencia respiratoria.

© 2020 Elsevier España, S.L.U. y SEMICYUC. Todos los derechos reservados.

Introduction

A relevant part of patients affected by coronavirus disease 19 (COVID-19) develops mild to severe acute respiratory failure (ARF).^{1,2} Continuous positive airway pressure (CPAP) has been proposed as a simple, potentially effective tool to improve oxygenation and to avoid tracheal intubation.^{3,4} Helmet could be the best choice as interface, to minimize the risk of viral spreading to health care workers and other patients while offering the best comfort.^{4,5} Moreover, CPAP use in ordinary wards is a well-established practice, a valuable possibility when intensive care units (ICU) are overcrowded like during the COVID-19 pandemic.⁶⁻¹⁰

Prono positioning proved effective in reducing mortality in ARDS invasively ventilated patients,¹¹ and has been

proposed also for COVID-19 ARDS.¹² Its beneficial effects have been attributed to several mechanisms including recruitment of dorsal lung areas with improved ventilation/perfusion ratio and reduction of ventilation induced lung injury (VILI).¹³ The reduced difference in transpulmonary pressure between dorsal and ventral regions, makes ventilation more homogeneous, thus limiting alveolar overdistension and collapse.¹⁴ Moreover, pronation can reverse the atelectasis caused by the heart, in particular on the left lower lobe.¹⁵ Finally, diaphragm's displacement caudally decreases posterior compression of the lung, especially in obese patients.¹⁶

Prono positioning can also be applied in awake, spontaneously breathing patients treated by CPAP, both as a standard or as rescue treatment.^{8,17} So far, very few reports

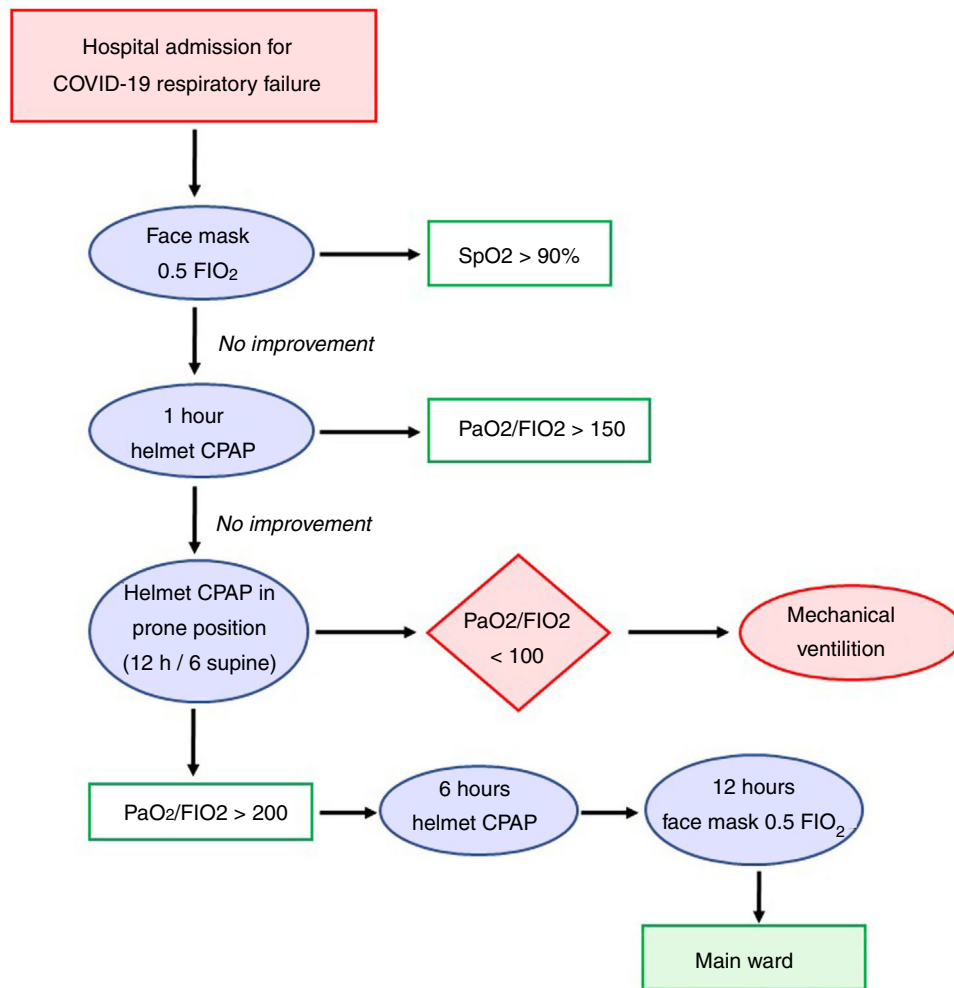


Figure 1 Flow chart adopted for the treatment of COVID-19 acute respiratory failure. COVID-19: coronavirus disease 19, CPAP: continuous positive airway pressure, FIO₂: fraction of inspired oxygen, PaO₂: arterial partial pressure of oxygen.

were published on this issue; moreover, no sedative strategy to improve patients' compliance to the treatment was reported. In the present study we describe our experience with helmet CPAP and pronation during the COVID-19 pandemic, also reporting on the use of dexmedetomidine to increase tolerance to prone positioning.

Methods

This was a single center study conducted in San Carlo University Hospital (Potenza, Italy) between April 1st and May 1st 2020. The hospital was reshaped to be the only COVID-19 hospital of an area with half million inhabitants in South Italy during the pandemic as per Health Ministry indication: the ICU beds increased from 23 to 39 and were dedicated to invasively ventilated COVID-19 patients; the six high dependency unit (HDU) beds were dedicated to patients with helmet CPAP and jointly managed by emergency and intensive care physicians; the main infectious disease 38 bed ward was dedicated to patients who were in spontaneous breathing, eupneic, and with peripheral oxygen saturation (SpO₂) ≥ 90% while receiving oxygen by face mask with a fraction of

inspired oxygen (FIO₂) of 0.5. The diagnosis of COVID-19-related pneumonia was performed with both a positive swab test and a suggestive CT scan.

In this study we collected data of all consecutive adult patients with COVID-19 ARDS who failed a one-hour helmet CPAP trial in supine position, with a persistent arterial partial pressure of oxygen/fraction of inspired oxygen (PaO₂/FIO₂) < 150. To avoid intubation (due to ICU bed scarcity and reports of poor outcome of COVID-19 invasively ventilated patients), if patients did not improve they received helmet CPAP in prone position: Twelve hours helmet CPAP in prone position were followed by six hours helmet CPAP in supine position. We did not consider pronation in case of excessive cough, hypotension, morbid obesity or patient refusal. Intubation and transfer to the intensive care unit were performed in case of PaO₂/FIO₂ < 100 and dyspnea.

After the third pronation cycle, with a PaO₂/FIO₂ > 200 pronation was stopped and oxygen by face mask was delivered with an FIO₂ of 0.5 for 48 h. The patient was discharged to the main ward when hemodynamically stable with a SpO₂ > 95%, respiratory rate (RR) < 20 and without dyspnea. The protocol adopted in our institution is presented in Fig. 1.

Since pronation with the helmet can be uncomfortable for the patient, dexmedetomidine (dose: 0.7–1.2 mcg/kg/min without starting bolus) was administered in case of poor compliance to the treatment.

Along with baseline characteristics, data collection included: SpO₂, PaO₂/FIO₂, arterial partial pressure of carbon dioxide (PaCO₂), pH, RR, and arterial lactate. Variables were recorded at 4 time points on CPAP treatment: immediately before prone position, at 24, 48 and 72 h. Need for ICU admission and 28-days mortality were collected.

Standard monitoring applied to all patients included: SpO₂, electrocardiography, invasive blood pressure, body temperature and RR. A central venous catheter was inserted through the right internal jugular vein.

In our institute standard severe acute respiratory syndrome coronavirus 2 (SARS COV-2) protocol treatment included: hydroxychloroquine (400 mg on first day, than 200 mg per day), piperacillin/tazobactam (4.5 g per day), acetylcysteine (300 mg 3 times a day), remdesivir (150 mg on first day, than 100 mg for 10 days) and tocilizumab (4–8 mg/kg once).

Ethical Committee approval was waived according to Italian law due to the retrospective and anonymized data collection.

Data are expressed as mean (\pm standard deviation) or number (percentage). Descriptive statistics were performed with STATA 16 and figures with Microsoft Excel 13. Variables were compared with unpaired *t*-test and statistical significance was assumed for *p* value less than 0.05.

Results

During the one-month study period, 27 out of the 81 patients hospitalized for SARS-COV-2 in our hospital were admitted in the high dependency unit to receive helmet CPAP for COVID-19 ARDS. Among these, 13 patients had PaO₂/FIO₂ < 150 after one hour with helmet CPAP in supine position. Two of these patients did not start helmet CPAP treatment in the prone position nor dexmedetomidine for cough and for hemodynamic instability respectively. Of the 11 consecutive patients who started helmet CPAP in the prone position, no patients interrupted helmet CPAP due to discomfort and no complications were observed during pronation sessions.

The 11 patients were treated for 7 ± 2.7 days with a positive end expiratory pressure (PEEP) of 9.6 ± 1.7 cmH₂O and pronation cycles of 13 ± 1.2 h duration. Patients were 62 ± 10 years old, seven were female and weighted 76 ± 11.6 kg. The most common comorbidity was hypertension (Table 1).

Dexmedetomidine was administered in seven (63.6%) patients to improve compliance to pronation without episodes of hypotension or bradycardia or other adverse events related to dexmedetomidine administration.

Blood gas analysis values and ventilation parameters are presented in Table 2 and Fig. 2. Mean SpO₂ was $90 \pm 2.3\%$ at baseline and improved to $97 \pm 3.1\%$ at 72 h ($p < .001$), meanwhile RR decreased from 27 ± 4.3 bpm to 20 ± 4.7 bpm ($p = .004$). At baseline mean PaO₂/FIO₂ was 107.5 ± 20.8 and improved to 244.4 ± 106.2 at 72 h ($p < .001$). No significant differences were observed for PaCO₂ pH and lactate.

Table 1 Baseline characteristics of the 11 patients who received helmet CPAP during pronation.

Age, years	62 (10)
Female, <i>n</i> ^o	7 (64%)
Weight, kg	76 (11.6)
Obesity, <i>n</i> ^o	2 (18%)
Hypertension, <i>n</i> ^o	5 (45%)
Diabetes, <i>n</i> ^o	2 (18%)
COPD, <i>n</i> ^o	3 (27%)
Previous CABG, <i>n</i> ^o	1 (11%)
Atrial fibrillation, <i>n</i> ^o	1 (11%)
No comorbidities, <i>n</i> ^o	2 (18%)
Active smokers, <i>n</i> ^o	2 (18%)
Past smokers, <i>n</i> ^o	4 (36%)
PEEP, cmH ₂ O	9.6 (1.74)

Values are presented as mean (SD) or number (%). CABG: coronary artery bypass graft, COPD: chronic obstructive pulmonary disease, PEEP: positive end-expiratory pressure.

At the 28 days follow up overall survival was 82%: eight patients were discharged home and three patients admitted to ICU for invasive mechanical ventilation. Among these, two died of multiple organ failure and one was discharged to main ward after nine days. These results are summarized in Fig. 3.

Discussion

In our experience conducted in a HDU managed by emergency physicians and intensivists, helmet CPAP in prone position resulted feasible and safe. Moreover, the infusion of dexmedetomidine to improve patients' compliance to pronation was well tolerated. No complication was observed in any of the pronation sessions. The failure rate (need of invasive ventilation) was relatively low (27%) considering that pronation was used as a rescue treatment in hypoxic COVID-19 ARDS patients failing supine-only CPAP. More importantly, the 28-day survival rate (82%) was high.

Mortality rate in patients requiring tracheal intubation and mechanical ventilation for COVID-19 ARF are reportedly quite high, approaching 100% in many studies.^{2,18,19} Furthermore, tracheal intubation can be dangerous for patients and healthcare workers.^{20,21} Hence, treatments to avoid tracheal intubation are valuable and potentially life-saving.^{3,22,23} CPAP already proved effective in several forms of ARF,^{9,10} and its application for COVID-19 ARF has been proposed.^{3,4} The use of the helmet as interface seems logical, as it can improve comfort and minimize air leakage (potentially a source of infection for other patients and healthcare workers).^{4,5} A very limited number of studies on helmet CPAP use for COVID-19 ARF is available.^{6,7}

A hot topic is whether prone position could enhance the efficacy of oxygen therapy or helmet CPAP in COVID-19 pneumonia, further reducing the risk of tracheal intubation and finally improving the survival rate. Thompson et al. reported its application in 25 spontaneously breathing patients treated by standard oxygen therapy: in all cases oxygenation improved at one-hour time-point. Interestingly, the intubation rate was lower in case of patients' SpO₂ improvement above 95% after one-hour pronation.²⁴

Table 2 Blood gas analyses results and respiratory rate at baseline and during CPAP at 24, 48 and 72 h.

	Baseline	24 h	48 h	72 h
PaO ₂ /FIO ₂	107.5 (20.8)	214.6 (73.1)	224.6 (86.6)	244.4 (106.2)
PaCO ₂ , mmHg	34 (3.2)	35 (3.6)	36 (3.4)	37 (3.3)
SaO ₂ , %	90 (2.3)	96 (2.2)	97 (1.4)	96 (3.1)
pH	7.41 (0.08)	7.43 (0.06)	7.40 (0.04)	7.40 (0.05)
Lactate, mmol/L	3.9 (1.90)	1.39 (0.04)	1.37 (0.03)	1.37 (0.44)
Respiratory rate, n	27 (4)	24 (5)	22 (4)	20 (5)

Values are presented as mean (SD). FIO₂: inspired fraction of oxygen, SaO₂: arterial oxygen saturation, PaO₂: arterial partial pressure of oxygen.

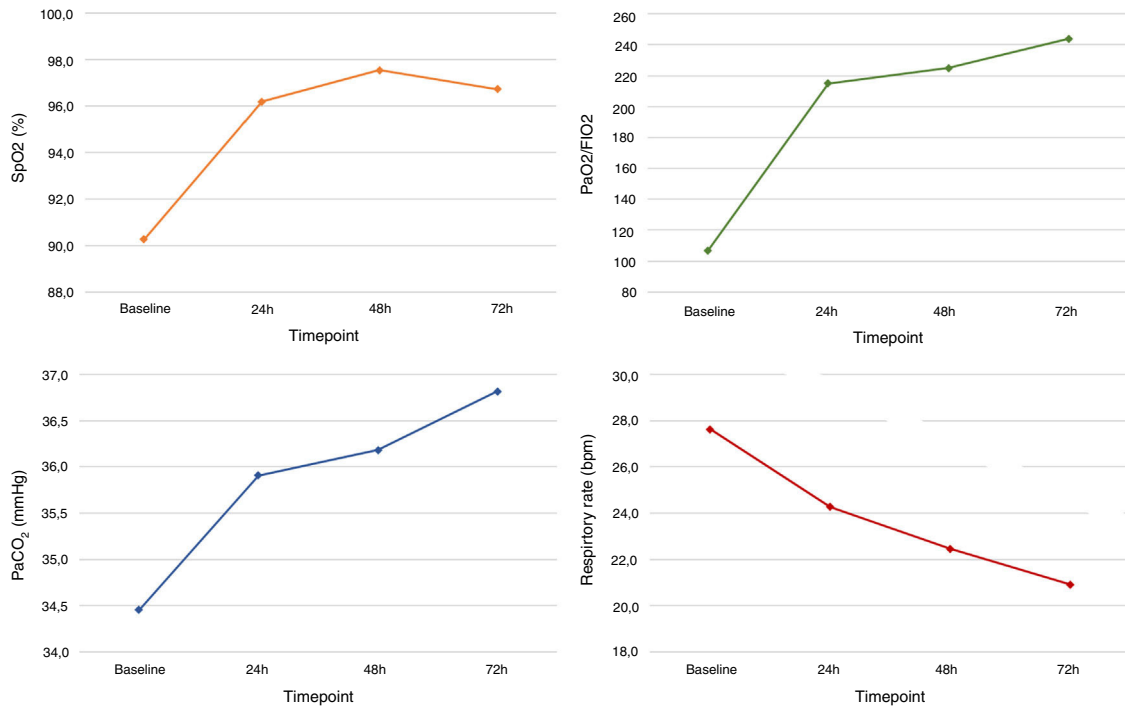


Figure 2 Trend of mean parameters at four time points: before pronation, 24, 48 and 72 h after starting pronation. Values are presented as mean. FIO₂: fraction of inspired oxygen, PaCO₂: arterial partial pressure of carbon dioxide, PaO₂: arterial partial pressure of oxygen, SpO₂: peripheral oxygen saturation.

Elharrar et al. reported on 24 patients treated with oxygen therapy: at 10-day follow-up five of them had been intubated.²⁵ In the context of noninvasive ventilation (NIV), Villareal-Fernandez et al. applied prone positioning in six severely hypoxemic patients while treated with NIV or high-flow nasal cannula: four avoided tracheal intubation.²² Sartini et al. applied pronation in 15 patients who had failed supine CPAP: at 14-day follow-up, one patient had been intubated and one had died.¹⁷ Finally one study evaluated pronation in 56 spontaneously breathing patients, a mixed population treated either with oxygen by face mask or NIV; only 47 actually were then pronated and 44 were treated with helmet CPAP. Thirteen patients were intubated and five deaths were observed at follow-up.⁸

Overall, only one complication was reported (an episode of emesis that required tracheal intubation),²² while refusal or intolerance were more common: 11% in the study by Coppo et al., 14% in the study by Thompson.^{8,24} Improving comfort and tolerance to prone positioning can be

of high relevance, allowing longer session and ultimately reducing the risk of tracheal intubation. Accordingly, we administered an infusion of dexmedetomidine in seven patients. Dexmedetomidine is a α 2-adrenoceptor agonist with sedative and anxiolytic effects; bradycardia and hypotension are possible side-effects, but the respiratory function is commonly preserved. So far, its successful use in relation to COVID-19 ARF has been reported in a single case, for a patient intolerant to standard oxygen therapy.²⁶ In our opinion dexmedetomidine could improve tolerance to helmet CPAP in prone position, provided that the treatments are performed in a well monitored setting like an HDU.

Limitations. None of the mentioned studies on helmet CPAP, including ours, was randomized, so the efficacy of the treatment is still unproved; on the other hand, CPAP efficacy has been demonstrated in the past in several other hypoxemic forms of ARF.^{5,9,10} Our study assessed a limited number of patients was assessed and larger studies are required to fully evaluate the safety of the treatment.

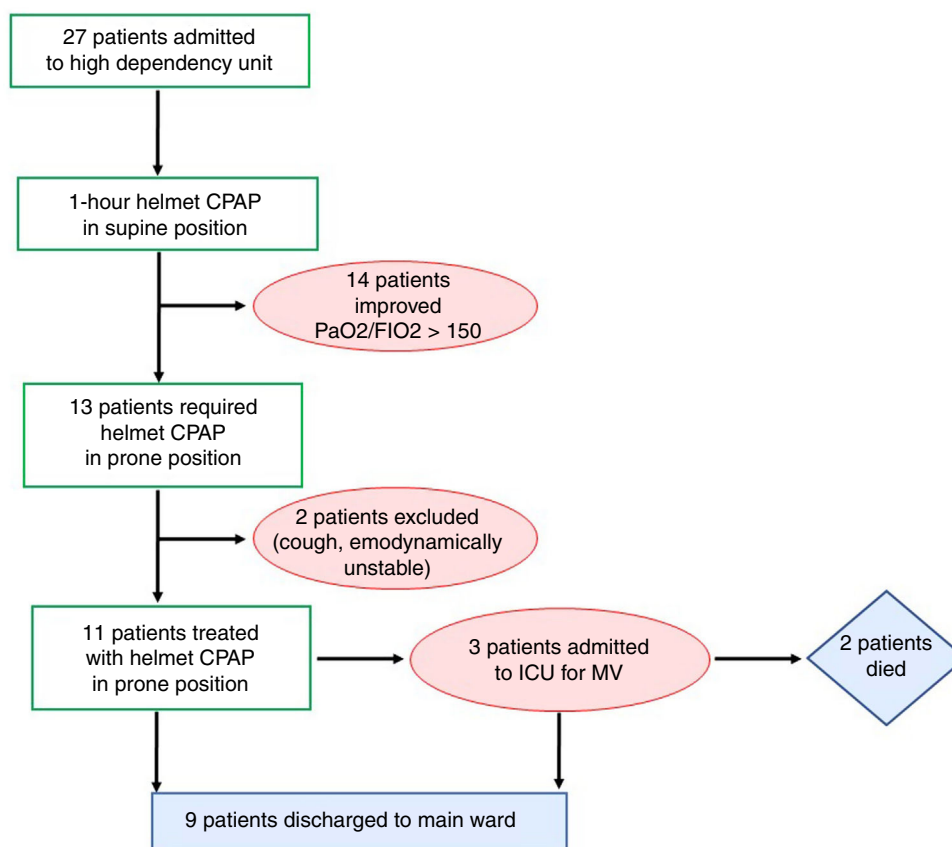


Figure 3 Flow chart of the 27 patients admitted for COVID-19 acute respiratory failure. CPAP: continuous positive airway pressure, FiO_2 : fraction of inspired oxygen, ICU: intensive care unit, MV: mechanical ventilation, PaO_2 : arterial partial pressure of oxygen.

Finally, the risk/benefit ratio of dexmedetomidine in this context requires a rigorous evaluation.

In conclusion, helmet CPAP in prone position for COVID-19 severely hypoxemic ARF resulted feasible and without complications; the infusion of dexmedetomidine to improve patients' compliance to pronation was well tolerated. The survival rate was high, but the efficacy of the treatment must be evaluated in randomized trials.

Authors' contributions

All the authors equally contributed to the manuscript.

Conflict of interest

The authors have no conflict of interest to disclose.

References

- Wang D, Hu B, Hu C, Zhu F, Liu X, Zhang J, et al. Clinical characteristics of 138 hospitalized patients with 2019 novel coronavirus-infected pneumonia in Wuhan, China. *JAMA*. 2020;323:1061–9, <http://dx.doi.org/10.1001/jama.2020.1585>.
- Yang X, Yu Y, Xu J, Shu H, Xia J, Liu H, et al. Clinical course and outcomes of critically ill patients with SARS-CoV-2 pneumonia in Wuhan, China: a single-centered, retrospective, observational study. *Lancet Respir Med*. 2020;8:475–81, [http://dx.doi.org/10.1016/S2213-2600\(20\)30079-5](http://dx.doi.org/10.1016/S2213-2600(20)30079-5).
- Arulkumar N, Brealey D, Howell D, Singer M. Use of non-invasive ventilation for patients with COVID-19: a cause for concern? *Lancet Respir Med*. 2020;8:e45, [http://dx.doi.org/10.1016/S2213-2600\(20\)30181-8](http://dx.doi.org/10.1016/S2213-2600(20)30181-8).
- Radovanovic D, Rizzi M, Pini S, Saad M, Chiumello DA, Santus P. Helmet CPAP to treat acute hypoxemic respiratory failure in patients with COVID-19: a management strategy proposal. *J Clin Med*. 2020;9.
- Cabrini L, Landoni G, Zangrillo A. Minimise nosocomial spread of 2019-nCoV when treating acute respiratory failure. *Lancet (Lond, Engl)*. 2020;395:685.
- Piva S, Filippini M, Turla F, Cattaneo S, Margola A, De Fulviis S, et al. Clinical presentation and initial management critically ill patients with severe acute respiratory syndrome coronavirus 2 (SARS-CoV-2) infection in Brescia, Italy. *J Crit Care*. 2020;58:29–33.
- Diurno F, Numis FG, Porta G, Cirillo F, Maddaluno S, Ragazzino A, et al. Eculizumab treatment in patients with COVID-19: preliminary results from real life ASL Napoli 2 Nord experience. *Eur Rev Med Pharmacol Sci*. 2020;24:4040–7.
- Coppo A, Bellani G, Winterton D, Di Pierro M, Soria A, Faverio P, et al. Feasibility and physiological effects of prone positioning in non-intubated patients with acute respiratory failure due to COVID-19 (PRON-COVID): a prospective cohort study. *Lancet Respir Med*. 2020.
- Cabrini L, Landoni G, Bocchino S, Lembo R, Monti G, Greco M, et al. Long-term survival rate in patients with acute respiratory failure treated with noninvasive ventilation in ordinary wards. *Crit Care Med*. 2016;44:2139–44.
- Cabrini L, Idone C, Colombo S, Monti G, Bergonzi PC, Landoni G, et al. Medical emergency team and non-invasive ventilation

- outside ICU for acute respiratory failure. *Intensive Care Med.* 2009;35:339–43.
11. Guérin C, Reignier J, Richard JC, Beuret P, Gacouin A, Boulain T, et al. Prone positioning in severe acute respiratory distress syndrome. *N Engl J Med.* 2013;368:2159–68.
 12. Alhazzani W, Møller MH, Arabi YM, Loeb M, Ng Gong M, Fan E, et al. Surviving sepsis campaign: guidelines on the management of critically ill adults with coronavirus disease 2019 (COVID-19), vol. 2019; 2020.
 13. Telias I, Katira BH, Brochard L. Is the prone position helpful during spontaneous breathing in patients with COVID-19? *JAMA.* 2020;323:2265–7.
 14. Cornejo RA, Díaz JC, Tobar EA, Bruhn AR, Ramos CA, González RA, et al. Effects of prone positioning on lung protection in patients with acute respiratory distress syndrome. *Am J Respir Crit Care Med.* 2013;188:440–8.
 15. Gattinoni L, Busana M, Giosa L, Macrì MM, Quintel M. Prone positioning in acute respiratory distress syndrome. *Semin Respir Crit Care Med.* 2019;40:94–100.
 16. Pelosi P, Croci M, Calappi E, Mulazzi D, Cerisara M, Vercesi P, et al. Prone positioning improves pulmonary function in obese patients during general anesthesia. *Anesth Analg.* 1996;83:578–83.
 17. Sartini C, Tresoldi M, Scarpellini P, Tettamanti A, Carcò F, Landoni G, et al. Respiratory parameters in patients with COVID-19 after using noninvasive ventilation in the prone position outside the intensive care unit. *JAMA.* 2020;323:2338–40.
 18. Richardson S, Hirsch JS, Narasimhan M, Crawford JM, McGinn T, Davidson KW, et al. Presenting characteristics comorbidities, and outcomes among 5700 patients hospitalized with COVID-19 in the New York City area. *JAMA.* 2020;323:2052–9.
 19. Wang Y, Lu X, Li Y, Chen H, Chen T, Su N, et al. Clinical course and outcomes of 344 intensive care patients with COVID-19. *Am J Respir Crit Care Med.* 2020;201:1430–4.
 20. Yao W, Wang T, Jiang B, Gao F, Wang L, Zheng H, et al. Emergency tracheal intubation in 202 patients with COVID-19 in Wuhan China: lessons learnt and international expert recommendations. *Br J Anaesth.* 2020;125:e28–37.
 21. Cook TM, El-Boghdady K, McGuire B, McNarry AF, Patel A, Higgs A. Consensus guidelines for managing the airway in patients with COVID-19: guidelines from the Difficult Airway Society, the Association of Anaesthetists the Intensive Care Society, the Faculty of Intensive Care Medicine and the Royal College of Anaesthetists. *Anaesthesia.* 2020;75:785–99.
 22. Villarreal-Fernandez E, Patel R, Golamari R, Khalid M, DeWaters A, Haouzi P. A plea for avoiding systematic intubation in severely hypoxemic patients with COVID-19-associated respiratory failure. *Crit Care.* 2020;24:337.
 23. Cabrini L, Ghislanzoni L, Severgnini P, Landoni G, Baiardo Redaelli M, Franchi F, et al. Early versus late tracheal intubation in COVID-19 patients: a pro-con debate also considering heart-lung interactions. *Cardioangiol J Miner.* 2020.
 24. Thompson AE, Ranard BL, Wei Y, Jelic S. Prone positioning in awake nonintubated patients with COVID-19 hypoxemic respiratory failure. *JAMA Intern Med.* 2020.
 25. Elharrar X, Trigui Y, Dols A-M, Touchon F, Martinez S, Prud'homme E, et al. Use of prone positioning in nonintubated patients with COVID-19 and hypoxemic acute respiratory failure. *JAMA.* 2020;323:2336–8.
 26. Stockton J, Kyle-Sidell C. Dexmedetomidine and worsening hypoxemia in the setting of COVID-19: a case report. *Am J Emerg Med.* 2020.