



## IMAGES IN INTENSIVE MEDICINE

### MRSA-related mycotic pseudoaneurysm of the aortic arch ☆



### Seudoaneurisma micótico en cayado aórtico por SARM

B.E. Lence Massa <sup>a,\*</sup>, A.M. López Lago <sup>a</sup>, A.X. Martínez de Alegría Alonso <sup>b</sup>

<sup>a</sup> Servicio de Medicina Intensiva, Complejo Hospitalario Universitario de Santiago de Compostela, Santiago de Compostela, La Coruña, Spain

<sup>b</sup> Servicio de Radiología, Complejo Hospitalario Universitario de Santiago de Compostela, Santiago de Compostela, La Coruña, Spain

Available online 5 March 2022

A 79-year-old woman presented with known cardiovascular risk factors and diagnosed with bacteremia due to methicillin-resistant *Staphylococcus aureus* (MRSA). As complications, she presented multiorgan failure, a mycotic pseudoaneurysm of the aortic arch, left middle cerebral artery stroke and purulent pericarditis. The patient finally died due to hypovolemic shock in the context of rupture of the mentioned pseudoaneurysm (Fig. 1). In the image: (A) Axial CT view of the aortic arch showing a large 2.5-cm defect at the medial margin, through which contrast extravasation is seen towards a cavity measuring  $5.7 \times 4$  cm (black arrows) (pseudoaneurysm). (B) Severe purulent/inflammatory pericardial effusion (white arrow) and left pleural effusion. (C) Three-dimensional volume rendering reconstruction of the aorta, showing the pseudoaneurysm (white arrow), originating from the medial margin of the arch, with displacement of the supraaortic trunks.

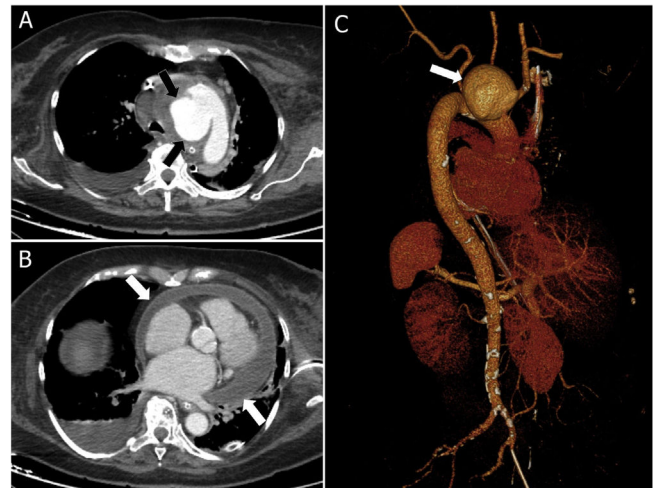


Figure 1

neurysm (white arrow), originating from the medial margin of the arch, with displacement of the supraaortic trunks.

☆ Please cite this article as: Lence Massa BE, López Lago AM, Martínez de Alegría Alonso AX. Seudoaneurisma micótico en cayado aórtico por SARM. *Med Intensiva*. 2022;46:293.

\* Corresponding author.

E-mail address: [lencemassa@gmail.com](mailto:lencemassa@gmail.com) (B.E. Lence Massa).