



IMAGES IN INTENSIVE MEDICINE

Massive hemoptysis due to *Aspergillus*-related pulmonary artery pseudoaneurysm in a patient with COVID-19 pneumonia



Hemoptisis masiva debido a un pseudoaneurisma de la arteria pulmonar en una paciente con aspergilosis pulmonar y neumonía COVID-19

I. Baeza^a, I. Romera^{a,*}, J.R. Fortuño^b

^a Unidad de Cuidados Intensivos, SCIAS Hospital de Barcelona, Barcelona, Spain

^b Departamento de Radiología, SCIAS Hospital de Barcelona, Barcelona, Spain

Available online 29 October 2022

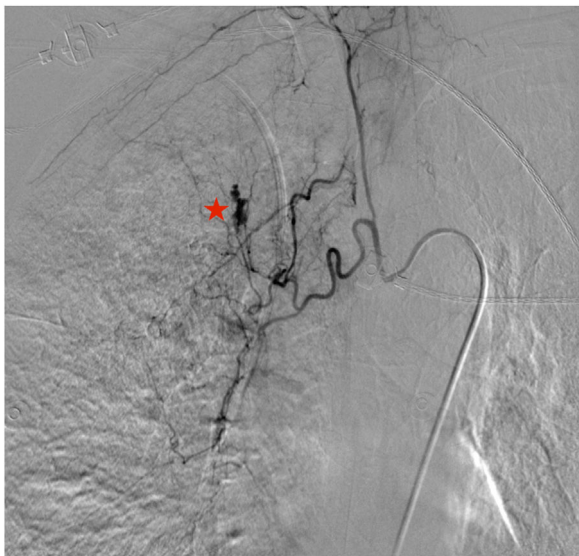


Figure 1

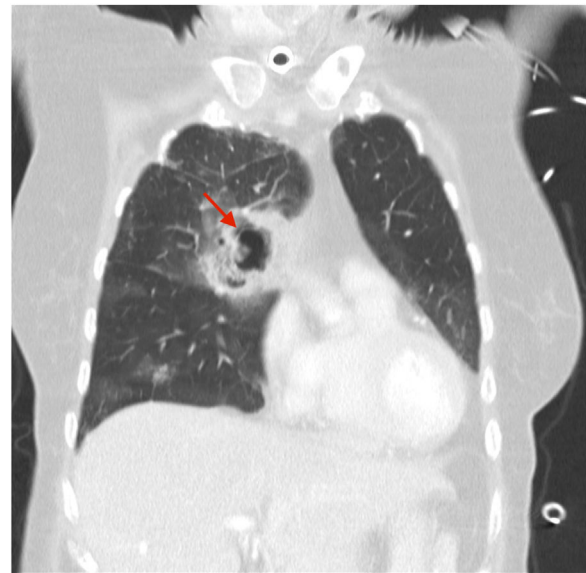


Figure 2

* Corresponding author.

E-mail address: irene.r.s@outlook.com (I. Romera).

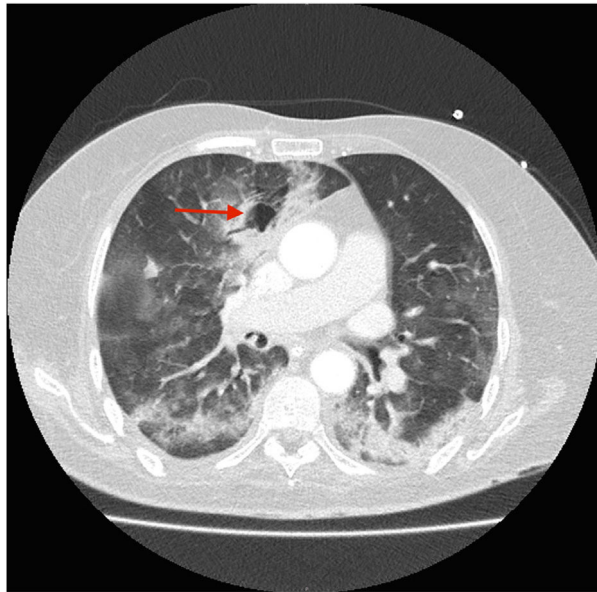


Figure 3

A 70-year-old woman was admitted to our intensive care unit due to COVID-19 pneumonia. She received treatment with remdesivir for five days, two doses of tocilizumab and methylprednisolone (1 mg/kg/day). Patient required intubation and tracheostomy due to myopathy. After nineteen days, patient presented a massive hemoptysis. An urgent bronchoscopy evidenced a non-occlusive clot in the right main bronchus and a pulsatile lesion underneath. The pulmonary artery angiography showed a pseudoaneurysm in a right intercostobronchial trunk (Fig. 1) with extravasation of iodinated contrast (*red star*). Immediate transcatheter exclusion of the pseudoaneurysm was successful. The thoracic CT-scan evidenced the typical COVID-19 pattern with a highly suspicious *aspergillus* cavity (*red arrow*) in the right upper lobe pulmonary parenchyma (Figs. 2 and 3). Respiratory secretions cultures were positive for *Aspergillus niger* so dual antifungal treatment was started. This case illustrates the risk of COVID-19 associated pulmonary aspergillosis (CAPA) and related complications.

Funding

This work has not received any type of funding.

Conflicts of interest

The authors declare that they have no conflict of interest.