



IMAGES IN INTENSIVE MEDICINE

Just another sepsis case? Lemmel's syndrome presenting as acute cholangitis



¿Otro caso de sepsis? Presentación de un síndrome de Lemmel como colangitis aguda

A.M. Ioan^a, B. Sobrino Guijarro^b, A. Santos^{a,c,*}

^a Intensive Care Medicine Department "Fundación Jiménez Díaz" University Hospital, Madrid, Spain

^b Radiology Department "Fundación Jiménez Díaz" University Hospital, Madrid, Spain

^c CIBER de Enfermedades Respiratorias, Instituto de Salud Carlos III, C/Monforte de Lemos 3-5, Madrid, Spain

Available online 29 October 2022

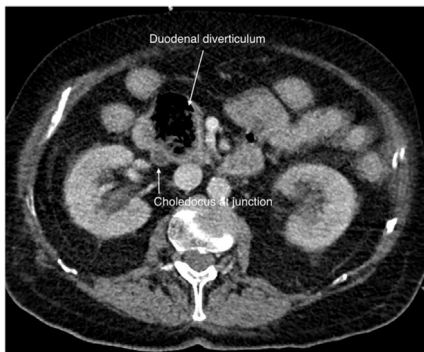


Figure 1

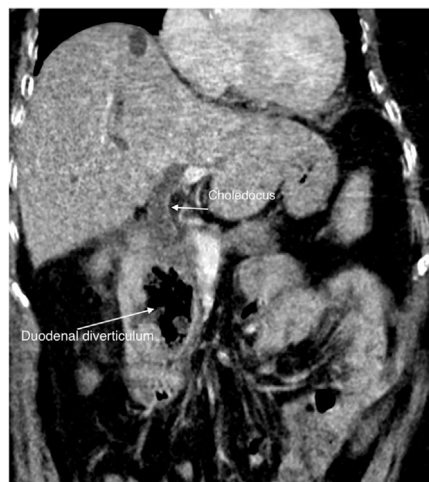

Figure 2

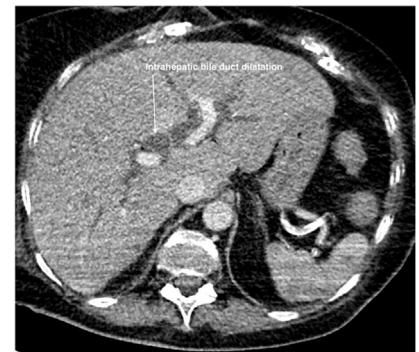

Figure 3

A 77 y.o. woman with a history of cholecystectomy was brought to the Emergency Department for low level of consciousness. Physical exam was normal except for hypoperfusion signs and hemodynamic instability. At paraclinical tests, she showed a normal EKG, blood analysis with acute renal failure data. Cranial computerized tomography (CT) and thoracic pulmonary CT angiography had no alteration. After aggressive fluid resuscitation in the first hour of admission, she improved alertness and mean arterial blood pressure, orienting further differential diagnosis towards sepsis. The abdominal CT scan revealed a voluminous diverticulum in the second portion of the duodenum (Fig. 1.), producing an obstructive effect and marked dilation of both extra (Fig. 2) and intrahepatic biliary ducts (Fig. 3) known as Lemmel's syndrome.

* Corresponding author.

E-mail address: asantosoviedo@yahoo.com (A. Santos).