

Four cases of unexpected severe community-acquired pneumonia aetiology: Group A *Streptococcus pyogenes* disruption



Cuatro casos de neumonía comunitaria grave de etiologica inesperada: Disrupción de *Streptococcus pyogenes* del grupo A

To the Editor,

SARS-CoV₂ pandemic has led to multiple changes in health-care. Unexpected changes in the incidence and etiology of infectious pathologies have been described. Among them, an increase of *Streptococcus pyogenes* infection prevalence has been described in 2022.¹⁻³ *S. pyogenes* community-acquired pneumonia (CAP) outbreaks were described in the early 20th century as a complication of viral infections such as influenza and measles.⁴ Case reports and small case series have been published ever after.^{5,6} In 2017 influenza season, *S. pyogenes* CAP outbreak was described in Australia, in which 92% of patients required ICU admission and 84.6% died due to the infection.⁷ We have reviewed all *S. pyogenes* CAP treated in our ICU in the last eight years. Hospital Ethics Committee reviewed and approved the study (code 2023-254-1).

Case 1 (March-2016). A 50 years-old woman with medical background of high blood pressure presented to the emergency room with a four-days clinical picture of sore throat, high fever, productive cough, right chest pain, and dyspnoea. Complementary test results are depicted in Table 1 and Fig. 1. She was admitted to ICU due to septic shock and respiratory failure. Mechanical ventilation (MV) was initiated. The patient received ceftriaxone and levofloxacin. *S. pyogenes* was detected in blood cultures and sputum and linezolid substituted levofloxacin. Besides, nasopharyngeal swab was positive to H1N1 influenza. Clinical course was complicated by pleural empyema, pneumothorax and ventilator-associated pneumonia (VAP). Tracheostomy was performed after 21 days of MV. Finally she was disconnected from MV after 63 days, and she was transferred to general ward after 72 days in ICU. She needed another 21 days in the ward to recover motor independence.

Case 2 (February-2018). A 40 years-old man without medical background presented to the emergency room with a one-week clinical picture of productive cough, high fever and left chest pain. Complementary test results are depicted in Table 1 and Fig. 1. He was admitted to ICU due to respiratory failure, septic shock and acute renal failure. Empirical antibiotic treatment was ceftriaxone plus azithromycin. Left pleural empyema was drained at ICU admission and *S. pyogenes* was isolated in pleural fluid. Azithromycin was therefore changed to linezolid. Respiratory virus PCR panel was positive to Metapneumovirus. MV and prone position ventilation was needed due to severe ARDS. Clinical course was complicated by *Pseudomonas aeruginosa* VAP. Tracheostomy was performed after 19 days of MV and could be withdrawn after 16 days. He was transferred to general ward after 36 days in ICU and to his home ten days later.

Table 1 Biochemical and haematological analysis at ICU admission.

	Age	SAPSIII	SOFA	Sex	Bilateral pneumonia	Multiobar pneumonia	Leucocytes (cell/mm ³)	Lymphocytes (cell /mm ³)	PCT (ng/mL)	CRP (mg/l)	Platelets (cell/mm ³)	Fibrinogen (mg/dl)	PaO ₂ / FIO ₂
Case 1	50	47	12	Female	Yes	Yes	610	130	18.06	202	136,000	628	83
Case 2	40	59	12	Male	No	Yes	2580	90	142	385.5	125,000	810	64.5
Case 3	51	80	16	Female	Yes	Yes	15,630	790	77.56	516.6	90,000	940	77
Case 4	32	39	8	Female	No	Yes	10,450	100	8.22	364	139,000	956	194

ICU: Intensive Care Unit; PCT: procalcitonin; CRP C-reactive protein.

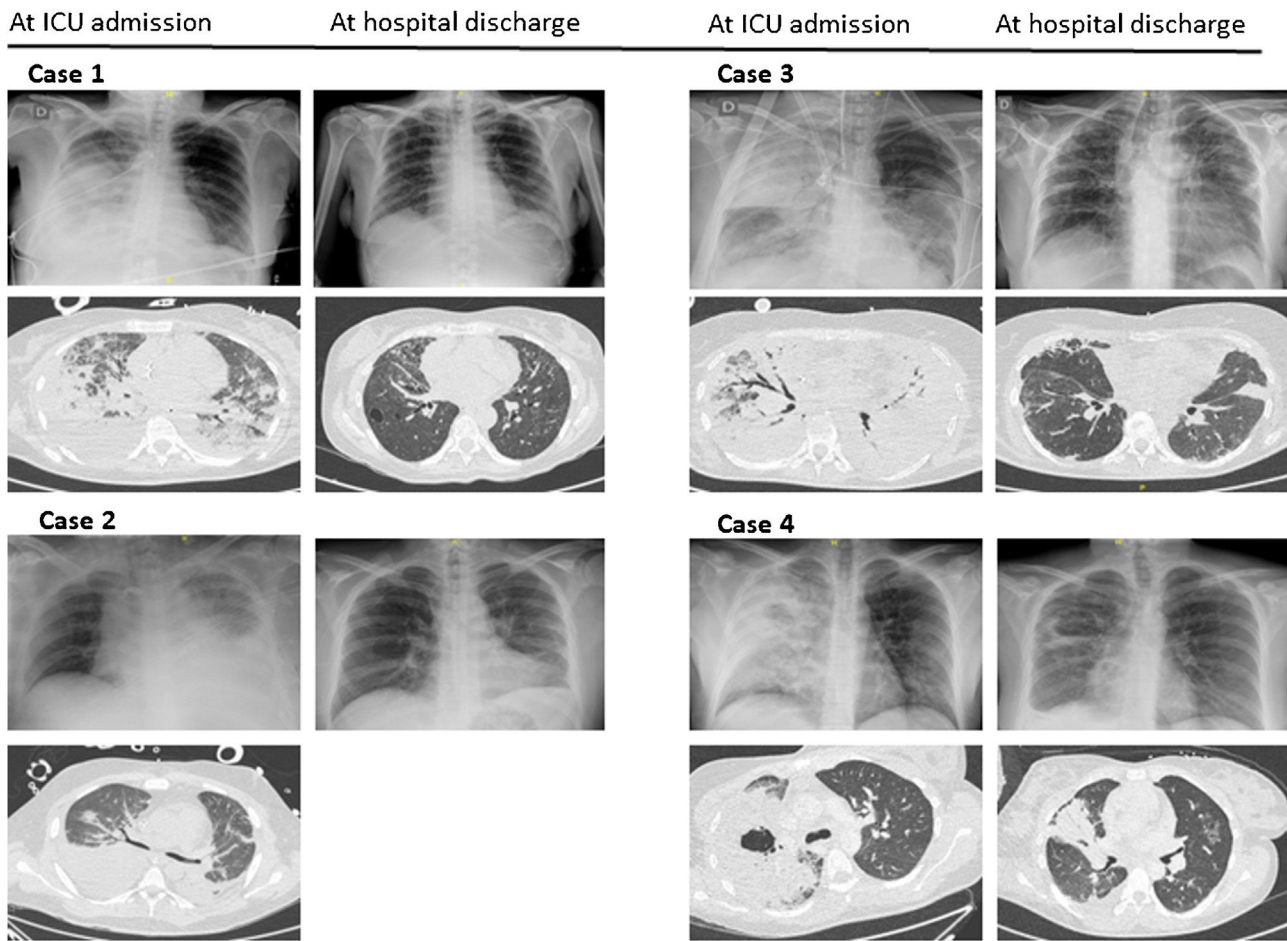


Figure 1 Thorax X-ray and thoracic CT-scan at ICU admission and at hospital discharge.

Case 3 (July-2022). A 51 years-old woman without medical background, and with a complete SARS-CoV₂ vaccination schedule presented to a regional hospital with a clinical picture of fever, productive cough and dyspnoea following a COVID₁₉ diagnosis. Complementary test results are depicted in [Table 1](#) and [Fig. 1](#). She was admitted to ICU due to respiratory failure, septic shock, acute renal failure and intravascular disseminated coagulopathy. She was empirically treated with piperacillin-tazobactam plus linezolid. Severe hypoxia was refractory to MV, prone position ventilation and alveolar recruitment manoeuvres, and therefore she was proposed for ECMO treatment two days later. The patient was connected to VV-ECMO and transferred to our ICU. *S. pyogenes* ADN was detected in alveolar fluid and treatment was shifted to ceftaroline and tedizolid. After 14 days, VV-ECMO was withdrawal and the patient was successfully extubated ten days later. However, a *P. aeruginosa* nosocomial pneumonia developed and dragged the patient into a new situation of sepsis and respiratory failure. The patient was newly intubated. Once again, given the refractoriness to other therapeutic measures, it was decided to switch back to ECMO. The clinical course was very intricate and included the need for amputation of the right hand due to ischemia. After 40 days tracheal cannula and MV were withdrawal and 9 days later the second VV-ECMO treatment

could be finished. She was discharged from ICU after 92 days and discharged home eleven days later.

Case 4 (December-2022). A 32 years-old woman with medical background of type 1 diabetes mellitus presented to the emergency room with a four days clinical picture of sore throat, productive cough, fever and right forearm pain. Complementary test results are depicted in [Table 1](#) and [Fig. 1](#). She was admitted to ICU due to respiratory failure, and clinical suspect of necrotizing fasciitis. Empirical treatment comprised meropenem plus levofloxacin. Respiratory support consisted in high flow nasal oxygen cannula. Debridement was performed the following day and *S. pyogenes* was detected by PCR in muscle tissue sample. Respiratory samples were not available, and we assumed that the etiology of the pneumonia was the same. Antibiotic treatment was switched to ceftaroline plus linezolid. Local surgery was needed in three more points till surgical edges could be closed. The patient was discharged from ICU after 10 days and discharged home 19 days later.

Our results are consistent with recently published findings on the notable increase in *S. pyogenes* infections. We have detected two cases of CAP due to *S. pyogenes* in 2022, which represents a notable increase compared to the previous seven years (from 0.38% of all bacterial CAP to 3.2% in 2022). Nowadays the only attributable risk factor for this

global *S. pyogenes* resurgence is SARS-CoV2 pandemia.^{1–3} Our serious clinical cases are the ultimate expression of *S. pyogenes* pneumonia. All of them had a complex course, a prolonged ICU stay and a high incidence of superinfections. In fact, the third case is our first experience in the use of two consecutive therapies with VV-ECMO. Our cases were treated with a beta-lactam and a toxin-producing inhibitor. 2022 cases were treated with ceftaroline. This clinical decision was based on the good results obtained by ceftaroline compared to ceftriaxone in *S pneumoniae* CAP,⁸ but it was also due to the pharmacokinetic doubts that have arisen regarding ceftriaxone in critically ill patients and the lower MIC values exhibited to ceftaroline compared to ceftriaxone by *S. pyogenes*.^{9,10} Our four patients were able to overcome *S. pyogenes* pneumonia and illustrate the need to consider this etiology in order to carry out correct therapeutic management and a proactive search for local and systemic complications.

References

1. ISIS-AR Study Group; GAS Study group de Gier B, Marchal N, de Beer-Schuurman I, Wierik MT, Hooiveld M, de Melker HE, et al. Increase in invasive group A streptococcal (*Streptococcus pyogenes*) infections (iGAS) in young children in the Netherlands, 2022. *Euro Surveill.* 2023;28(1):2200941.
2. European Centre for Disease Prevention and Control (ECDC). Communicable disease threats report week 49, 4–10 December 2022. Stockholm: ECDC; 2022. Available from: <https://www.ecdc.europa.eu/en/publications-data/communicable-disease-threats-report-4-10-december-2022-week-49> [Accessed 12 December 2022].
3. World Health Organization (WHO), Available from: Disease Outbreak News; Increased incidence of scarlet fever and invasive Group A *Streptococcus* infection – multi-country. Geneva: WHO; 2022 <https://www.who.int/emergencies/disease-outbreak-news/item/2022-DON429>
4. Morens DM, Taubenberger JK. A forgotten epidemic that changed medicine: measles in the US Army, 1917–18. *Lancet Infect Dis.* 2015;15(7):852–61.
5. Wilson PA, Varadhan H. Severe community-acquired pneumonia due to *Streptococcus pyogenes* in the Newcastle area. *Commun Dis Intell.* 2020;44.
6. Tamayo E, Montes, Vicente D, Pérez-Trallero E. *Streptococcus pyogenes* pneumonia in adults: clinical presentation and molecular characterization of isolates 2006–2015. *PLoS One.* 2016;11(3):e0152640.
7. Rahi J, Will M. Group A *Streptococcus* necrotising myositis of the limbs secondary to cavitating pneumonia. *BMJ Case Rep.* 2021;14:e239929.
8. Taboada M, Melnick D, Iaconis JP, Sun F, Zhong NS, File TM, et al. Ceftaroline fosamil versus ceftriaxone for the treatment of community-acquired pneumonia: individual patient data meta-analysis of randomized controlled trials. *J Antimicrob Chemother.* 2016;71(6):1748–9.
9. Biek D, Critchley I, Riccobene TA, Thye DA. Ceftaroline fosamil: a novel broad-spectrum cephalosporin with expanded anti-Gram-positive activity. *Antimicrob Chemother.* 2010;65 Suppl 4:iv9–16.
10. Joynt GM, Lipman J, Gomersall CD, Young RJ, Wong EL, Gin T. The pharmacokinetics of once-daily dosing of ceftriaxone in critically ill patients. *Antimicrob Chemother.* 2001; 47(4):421–9.

Mónica Talavera^a, Almudena Martínez^a, Carlos Vicent^a, Juan Frasset^b, Ángel Orera^a, Paula Ramírez^{a,*}

^a Servicio de Medicina Intensiva, Hospital Universitario y Politécnico La Fe, Valencia, Spain

^b Servicio de Microbiología, Hospital Universitario y Politécnico La Fe, Valencia, Spain

* Corresponding author.

E-mail address: Ramirez.pau@gva.es (P. Ramírez).

2173-5727/ © 2023 Elsevier España, S.L.U. and SEMICYUC. All rights reserved.