



## IMAGES IN INTENSIVE MEDICINE

## Complication after renal tumorectomy: An unusual case

## Complicación tras tumorectomía renal: un caso inusual

Montserrat Rodríguez Gómez\*, Sara Domingo Marín, María Paloma González Arenas

Hospital Clínico San Carlos, Madrid, Spain

Available online 23 April 2024

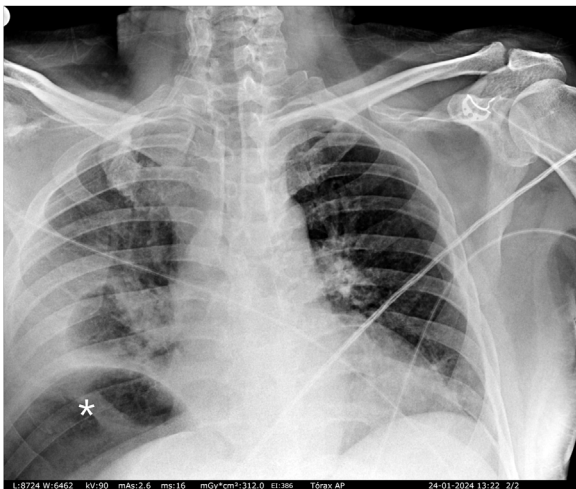


Figure 1

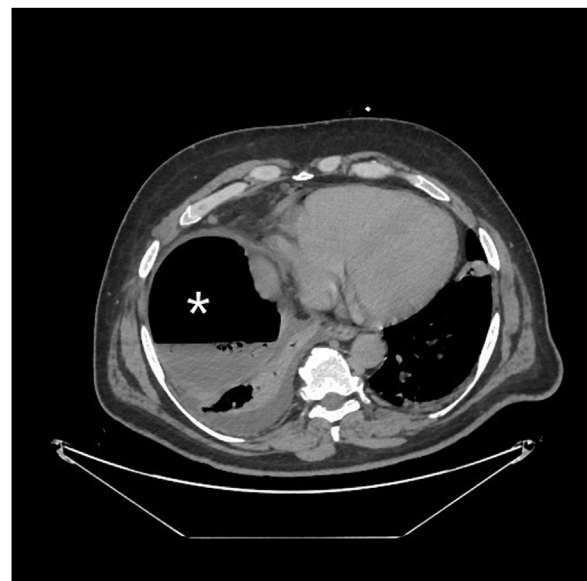

Figure 2

A 49-year-old male presented with no medical history apart from laparoscopic right renal cyst (Bosniak III-IV) removal performed a month ago. He presented to the emergency room with malaise, nonspecific abdominal pain and dyspnea. The initial chest radiographic study (Fig. 1) suggested pneumoperitoneum. The subsequent abdominal CAT scan (Fig. 2) revealed a subphrenic collection with an air-fluid level. Surgery confirmed retroperitoneal right colon perforation. Although retroperitoneal colon perforation is usually associated with retroperitoneum and retroperitoneal abscesses, neither of these conditions were observed in the present case. The patient exclusively presented a subphrenic abscess with an air-fluid level, which additionally produced a false image of pneumoperitoneum on the chest x-ray examination.

\* Corresponding author.

E-mail address: [Montserrat.rod.gom@gmail.com](mailto:Montserrat.rod.gom@gmail.com) (M. Rodríguez Gómez).