



SCIENTIFIC LETTERS

An unusual case of organizing pneumonia and infection by *P. jirovecii*

Un caso inusual de neumonía organizada e infección por *P. jirovecii*

Non-cryptogenic organising pneumonia (OP) secondary to a *Pneumocystis jirovecii* infection is a rare condition described in HIV (human immunodeficiency virus) infection, lung and liver transplantation; in this brief report we discuss the first clinical case in a patient not severely immunocompromised.

He was a 63 year-old man who consulted our centre's Emergency Department referring a 2 month long history of progressive dyspnoea and purulent sputum, oriented by general practitioner as an acute exacerbation of chronic bronchitis and treated with bronchodilators and amoxicillin-clavulanate. Two weeks before consulting dyspnoea became severe. Twenty-four hours before admission he referred fever (38 °C) and left pleural chest pain.

He was an active smoker (45 packs/year), ex-alcoholic, suffered from epilepsy well controlled with valproic acid for the last 2 years, hemochromatosis without organic impairment, an arytenoid carcinoma removed in 2009 endoscopically without relapse and a seronegative arthritis treated with methotrexate since 2009 with irregular medication intake (white blood cell count two months before admission was 10,200 leucocytes, 8520 neutrophils, 1560 lymphocytes).

He had worked as a subway driver, did not travel, and neither had pets.

Initial tests performed in the Emergency Department were: chest X-ray showing cardiomegaly; blood testing showing 9400 leukocytes, 8836 neutrophils, 654 lymphocytes; haemostasis, renal and hepatic functions were under normal parameters.

A lower respiratory tract infection was diagnosed and treated empirically with 40 mg/day corticosteroids, azytromycin, ceftriaxone and cotrimoxazole. Blood and sputum cultures, typical and atypical pneumonia antigenurias (urinary pneumococcal antigen detection) and serologies were negative as well as HIV. Antinuclear and antinuclear extractable auto-antibodies resulted negative.

He developed a progressive severe respiratory insufficiency with increasing interstitial opacities in chest X-ray, and the 7th day after admission he required intubation, mechanical ventilation with an oxygen injection fraction

of 1, being transferred to the Intensive Care Unit. Trans-thoracic echocardiography ruled out valvular alterations or decreased ventricular ejection fraction.

Suspecting lung interstitial pathology a biopsy by fibro-bronchoscopy was performed and three metilprednisolone 1g boluses were administered empirically. The patient improved after 2 days and computerised tomography scanning (CT scanning) was performed (Fig. 1), showing diffuse acute pulmonary damage, composed of ground glass areas associated to consolidation zones in inferior lobes, mild pleural effusion and cystic images suggestive of emphysema.

Initial results from transbronchial biopsy showed absence of malignancy, presence of widened septums due to fibrosis, mild inflammatory component with a lymphocytic predominance, and fibrin depots in the alveoli, all being diagnostic of an acute organising pneumonia.

The patient kept diminishing oxygen demands and the 11th day after admission the final biopsy result showed presence of *P. jirovecii*, in spite of being treated with cotrimoxazole 800 mg/day.

Control thoracic CT scanning was performed the 16th day since admission, showing residual ground glass areas and a mild left pleural effusion. The patient was extubated the 18th day after admission.

The patient was oriented as a non-cryptogenic organising pneumonia, secondary to a *P. jirovecii* infection. He kept receiving 60 mg/day of metilprednisolone for a month and later was tapered down gradually. He also completed 3 weeks of treatment against the infection, replacing cotrimoxazole for inhaled pentamidine due to hyperkalemia. He completed a 6 month follow up, with radiologic resolution of the infiltrates, mild ventilatory obstruction and remaining clinically asymptomatic without treatment.

In 1990, Liote et al.¹ described for the first time HIV patients suffering from *P. jirovecii* infection who developed synchronically bronchiolitis obliterans, nowadays known as OP, that was thought to appear in context of a great inflammatory reaction induced by the infection. Afterwards other authors described the same process in lung and liver transplanted subjects.²⁻⁴ The underlying pathogenic mechanism is still unknown but reports of *P. jirovecii*-related type 1 pneumocytes related damage or proteolysis,^{5,6} as well as documentation of acute alveolar damage⁷ in HIV patients, may show an important inflammatory background that could lead to the formation of the interstitial pneumonia architecture.

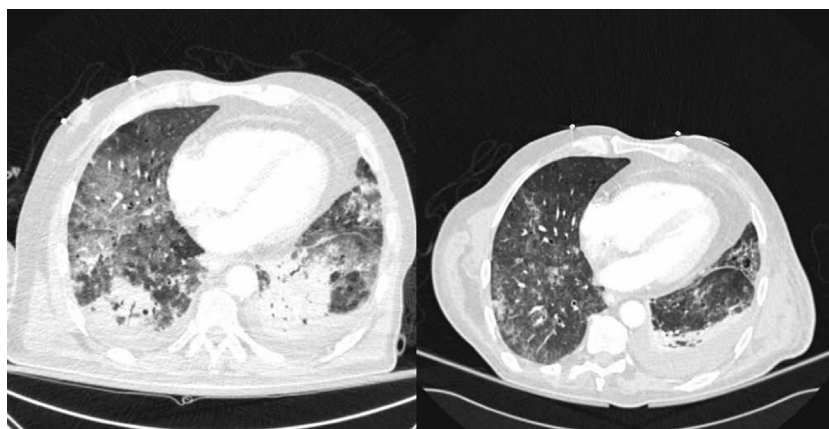


Figure 1 Computerised tomography scanning samples. On the left a cut of the first one performed and on the right, another cut after two weeks of treatment.

OP is an exclusion diagnosis⁸ and obtaining a biopsy specimen is mandatory. This case report, after ruling out HIV, bacterial or viral agents different from *P. jirovecii*; collagen diseases or other interstitial entities, could represent the first non-cryptogenic OP associated to *P. jirovecii* pneumonia reported in a patient who does not meet the conditions described before in literature. He had no lymphopenia, and neither neutropenia in previous tests, which are the best markers for immunosuppression due to methotrexate; although immunosuppressor intake and the subject's previous medical history may raise reasonable doubts about a completely intact immune system function. Drug induced pulmonary damage was not considered responsible because it had been introduced 2 years before at low doses and biopsy did not match with toxicity. The fact that the patient responded well and fast to high corticosteroid doses, instead to cotrimoxazole and medium corticosteroid doses, suggests that acute OP was the main responsible of the clinic. Acute onset OP has been associated to a poor prognosis⁹ and high dose corticosteroids are the main treatment.

Diagnosis of OP includes systematic ruling out of other aetiologies and a corresponding biopsy. Non-cryptogenic OP associated to *P. jirovecii* infection has been described in some severely immunosuppressed patients. In this report we describe the first case in a patient that does not meet those medical conditions. High dose corticosteroids and specific antibiotics have shown to be a successful treatment for this patient.

Conflicts of interest

The authors have no conflicts of interest to declare.

Acknowledgement

We would like to acknowledge Prof. Ferran Morell for his support.

References

1. Liote H, Porte JM, Postal MJ, Martin de Lassalle E, Derenne JP. Bronchiolite oblit rante, pneumocystose et infection par le V.I.H.

- [Bronchiolitis obliterans, pneumocystosis and HIV infection]. Rev Mal Respir. 1990;7:603-7.
2. Foley NM, Griffiths MH, Miller RF. Histologically atypical *Pneumocystis carinii* pneumonia. Thorax. 1993;48:996-1001.
 3. Sanito NJ, Morley TF, Condoluci DV. Bronchiolitis obliterans organizing pneumonia in an AIDS patient. Eur Respir J. 1995;8:1021-4.
 4. Yousem SA, Duncan SR, Griffith BP. Interstitial and airspace granulation tissue reactions in lung transplant recipients. Am J Surg Pathol. 1992;16:877-84.
 5. Blumenfeld W, Basgoz N, Owen WF, Schmidt DM. Granulomatous pulmonary lesions in patients with the acquired immunodeficiency syndrome (AIDS) and *Pneumocystis carinii* pneumonia. Ann Intern Med. 1988;109:505-7.
 6. Travis WD, Pittaluga S, Lipshik GY, Ognibene FP, Suffredini AF, Masur H, et al. Atypical pathologic manifestations of *Pneumocystis carinii* pneumonia in the acquired immune deficiency syndrome. Am J Surg Pathol. 1990;14:615-25.
 7. Askin FB, Katzenstein A-LA. Pneumocystis infection masquerading as diffuse alveolar damage; a potential source of diagnostic error. Chest. 1981;79:420-2.
 8. Cordier J-F. Cryptogenic organising pneumonia. Eur Respir J. 2006;28:422-46.
 9. Cohen AJ, King Jr TE, Downey GP. Rapidly progressive bronchiolitis obliterans with organizing pneumonia. Am J Respir Crit Care Med. 1994;149:1670.

A. Fern ndez-Codina^{a,*}, B. Caralt-Ramisa^b,
J.R. Masclans^{b,d}, M. Farr d^c, C. Bravo^c, J. Rello^{b,d}

^a Internal Medicine Department, Autoimmune Diseases Unit, Hospital Universitari Vall d'Hebron, Vall d'Hebron Institut de Recerca, Universitat Aut noma de Barcelona, Barcelona, Spain

^b Critical Care Department, Hospital Universitari Vall d'Hebron, Vall d'Hebron Institut de Recerca, Universitat Aut noma de Barcelona, Barcelona, Spain

^c Pneumology Department, Hospital Universitari Vall d'Hebron, Vall d'Hebron Institut de Recerca, Universitat Aut noma de Barcelona, Barcelona, Spain

^d CIBERES, Spain

* Corresponding author.

E-mail address: Andreu.fernandez@vhebron.net
(A. Fern ndez-Codina).

<http://dx.doi.org/10.1016/j.medin.2012.08.005>