



IMAGES IN INTENSIVE MEDICINE

Malpositioning of a venous cannula into the contralateral femoral vein in VA-ECMO



Colocación incorrecta de una cánula venosa en la arteria femoral contralateral en ECMO-VA

J. Song, S.J. Gong*, Y.Y. Yu

Department of Intensive Care Unit, Zhejiang Hospital, Hangzhou, Zhejiang, China

Available online 27 January 2020

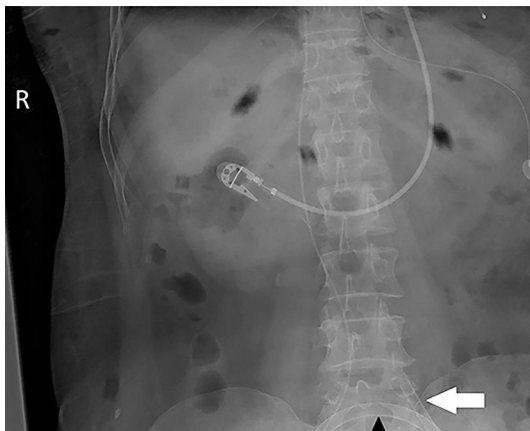


Figure 1

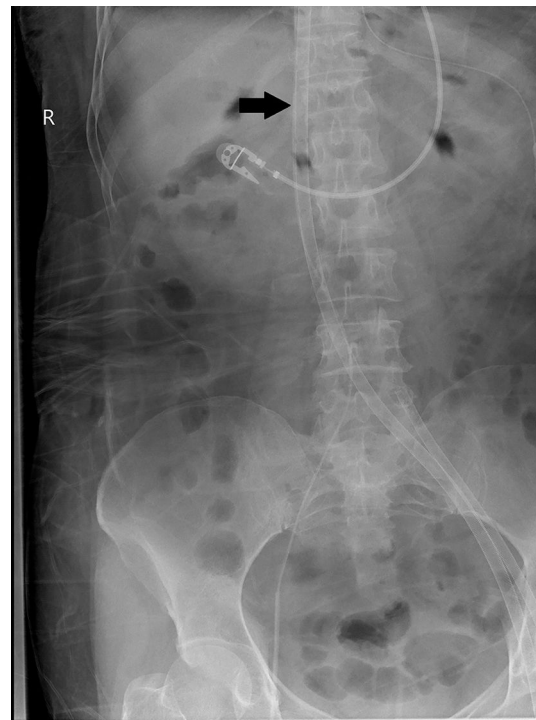


Figure 2

* Corresponding author.
E-mail address: gsj801@126.com (S.J. Gong).

A 52-year-old woman was admitted to the ICU for cardiogenic shock due to viral myocarditis. Despite exhausting maximal efforts, her hemodynamic status continued to deteriorate. The attending physician decided to initiate veno-arterial extracorporeal membrane oxygenation (ECMO) via a percutaneous femoral approach. The left femoral vein and femoral artery cannulas were inserted smoothly. However, low flow occurred immediately after the ECMO run, the ECMO flow was only 0.6 L/min at 3000 RPM. A bedside abdominal X-ray showed the venous cannula crossing the left iliac vein with its tip located in the right iliac vein (the black arrow in Fig. 1). Immediately after the diagnosis, we stopped ECMO and replanted the femoral vein cannula. Both the abdominal X-ray and echocardiography confirmed that the venous cannula was placed in the inferior vena cava (the black arrow in Fig. 2 and white arrow in Vid. A). As the heart function gradually improved, the patient was successfully weaned from ECMO after 5 days.

Although ultrasound is widely used to guide ECMO peripheral puncture cannulation, we believe that it also should be mandatory in confirmation of the cannula location during the ECMO cannulation procedure.

Acknowledgments

This work was supported by the scientific research fund of National Health and Family Planning Commission of PRC-Major Science (Grant No. WKJ-ZJ-1601), Zhejiang Medical and Health Science and Technology Plan Project (Grant No. 2017KY182).

Appendix A. Supplementary data

Supplementary data associated with this article can be found, in the online version, at [doi:10.1016/j.medin.2019.12.010](https://doi.org/10.1016/j.medin.2019.12.010).