



IMAGES IN INTENSIVE MEDICINE

Pneumomediastinum in critically ill adult with COVID-19

Neumomediastino en adultos en estado critico con COVID-19

N. Collercandy^{a,*}, A. Guillon^{a,b}

^a CHU de Tours, service de médecine intensive réanimation, université de Tours, Tours, France

^b INSERM, Centre d'Etude des Pathologies Respiratoires (CEPR), Université de Tours, France

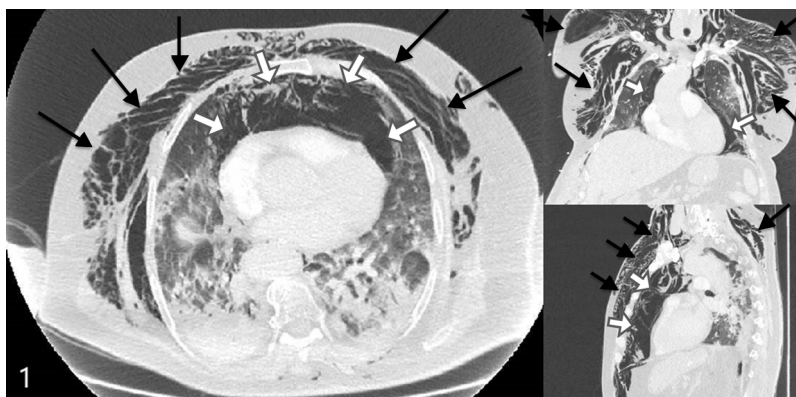


Figure 1

A 77-year-old man was admitted for moderate acute respiratory distress syndrome (ARDS) requiring invasive mechanical ventilation, with PCR confirmed SARS-Cov-2 infection. Protective ventilation strategy included: tidal volume of 6 mL/kg (ideal body weight), Positive End Expiratory Pressure (PEEP) titration with plateau pressure inferior to 28 cmH₂O, neuromuscular blockers, and prone position. At day 5 of ventilation, we observed acute chest and collar subcutaneous emphysema associated with bradycardia at 47bpm. Chest CT scan revealed diffuse pneumomediastinum (white arrows) with diffuse subcutaneous emphysema (black arrows) (Fig. 1). There was no pneumothorax and no evidence for tracheal or esophageal perforation. No intervention was required. Pneumomediastinum are observed in critically ill coronavirus disease 2019 (COVID-19) patients. Whether or not this complication is related to the mechanical ventilation or to the COVID-19 pathogeny *per se* remains an unanswered question.

Acknowledgements

The authors thank the patient, whom relative gave full written permission for this report.

* Corresponding author.

E-mail addresses: nived.collercandy@yahoo.fr (N. Collercandy), antoine.guillon@univ-tours.fr (A. Guillon).

<https://doi.org/10.1016/j.medin.2020.06.010>

0210-5691/© 2020 Elsevier España, S.L.U. y SEMICYUC. All rights reserved.