



IMAGES IN INTENSIVE MEDICINE

Pulmonary artery thrombus evidenced by transthoracic echocardiography during cardiopulmonary resuscitation[☆]



Trombo en arteria pulmonar, en ecocardiografía transtorácica, durante reanimación cardiopulmonar

A. Bohórquez López^{*}, A.M. Escosca Ortega, R. Martín Bermudez

Unidad de Cuidados Intensivos, Hospital Universitario Virgen del Rocío, Sevilla, Spain

Received 14 January 2016; accepted 1 February 2016

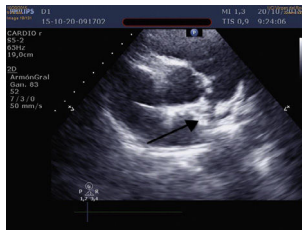


Figure 1

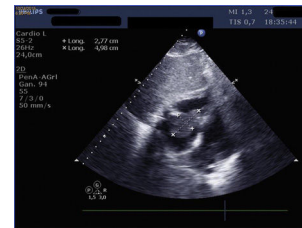


Figure 2

Thirty-one year old male with clinical manifestations of fever, and dyspnea attributed to infection who presents to the hospital eight days after suffering one episode of acromioclavicular luxation. He is admitted to the ICU with hypoxemic respiratory failure, shock, and three episodes of cardiac arrest (20 min total) during the first few minutes. During resuscitation, the transthoracic echocardiogram (TTE) (Fig. 1) (video TEP 1 and TEP 2) shows one large dilation of his right ventricle and one image is suggestive of a thrombus in the bifurcation of the pulmonary trunk. Fibrinolysis was performed during cardiopulmonary resuscitation. Four days later, the TTE confirmed one large mobile thrombus running through the tricuspid valve (Fig. 2) (video TEP 3), without hemodynamic repercussion. Thirty-six hours later the thrombus would have migrated with discrete repercussion—only seen in the ultrasound (dilation of right cavities). The patient's progression was satisfactory with complete recovery. In this case, the utility of the TTE in the ICU was significant both at the beginning and during the management of the patient, allowing immediate diagnosis and treatment.

Appendix A. Supplementary data

Supplementary data associated with this article can be found, in the online version, at <http://dx.doi.org/10.1016/j.medint.2016.02.007>.

[☆] Please cite this article as: Bohórquez López A, Escosca Ortega AM, Martín Bermudez R. Trombo en arteria pulmonar, en ecocardiografía transtorácica, durante reanimación cardiopulmonar. Med Intensiva. 2017;41:449.

^{*} Corresponding author.

E-mail address: abohorquez1983@gmail.com (A. Bohórquez López).