

optimal technique are, it is widely accepted that the PPT technique may be assessed in patients with contraindications for fibrinolysis or fibrinolytic failure. Based on our initial experience, we should avoid the combined treatment with local fibrinolysis in patients with contraindications for systemic fibrinolysis, yet despite the fact that the dose of the fibrinolytic agent is lower. In this sense, there are many studies that show that isolated PTT is a feasible and safe technique.⁶⁻⁹ Also, an immediate improvement of pulmonary pressures has been reported – something that may be useful in patients with shocks and severe right ventricular failure.⁶ During the last years, there were also several studies on the use of this technique in patients with sub-massive PTEs with good results.⁷ The advances of technology with the development of new devices that facilitate the extraction of thrombi together with the growing experience with this type of techniques may, in the coming years, generalize the use of the PPT technique for the management of patients with PTEs.

The goal of this paper is to show our own initial experience in the implementation of an urgent PTT program while benefiting from the presence of one on-call interventional cardiologist 24h/day and 365 days/year, within the recommendations established for the management of ST-segment elevation acute coronary syndrome (STACS). In Spain this type of program would be easier and cheaper to generalize to the large majority of centers with programs of primary angioplasty. To that end, the creation of multidisciplinary teams (ER, ICU, cardiology, radiology, etc.) may improve the management and prognosis of this type of patients.

Funding

The authors declare that they have received no funding while conducting this study.

References

1. Heit JA. The epidemiology of venous thromboembolism in the community. *Arterioscler Thromb Vasc Biol.* 2008;28:370–2.
2. Konstantinides SV, Torbicki A, Agnelli G, Danchin N, Fitzmaurice D, Galié N, et al. 2014 ESC Guidelines on the diagnosis and management of acute pulmonary embolism. *Eur Heart J.* 2014;35:3033–69.
3. Meyer G, Vieillard-Baron A, Planquette B. Recent advances in the management of pulmonary embolism: focus on the critically ill patients. *Ann Intensive Care.* 2016;6:19.
4. Pollack CV, Schreiber D, Goldhaber SZ, Slattery D, Fanikos J, O'Neil BJ, et al. Clinical characteristics, management, and outcomes of patients diagnosed with acute pulmonary embolism in the emergency department: initial report of EMPEROR (Multicenter Emergency Medicine Pulmonary Embolism in the Real World Registry). *J Am Coll Cardiol.* 2011;57:700–6.
5. Kuo WT, Gould MK, Louie JD, Rosenberg JK, Sze DY. Catheter therapy for the treatment of massive pulmonary embolism: systematic review and meta-analysis of modern techniques. *J Vasc Interv Radiol.* 2009;20:1431–40.
6. Dilektasli AG, Demirdogen Cetinoglu E, Acet NA, Erdogan C, Ursavas A, Ozkaya G, et al. Catheter-directed therapy in acute pulmonary embolism with right ventricular dysfunction: a promising modality to provide early hemodynamic recovery. *Med Sci Monit.* 2016;22:1265–73.
7. Mohan B, Chhabra ST, Aslam N, Mohan Mittal C, Mohan G, Tandon R, et al. Mechanical breakdown and thrombolysis in subacute massive pulmonary embolism: a prospective trial. *World J Cardiol.* 2013;5:141–7.
8. Bayiz H, Dumantepe M, Teymen B, Uyar I. Percutaneous aspiration thrombectomy in treatment of massive pulmonary embolism. *Heart Lung Circ.* 2015;24:46–54.
9. Dumantepe M, Teymen B, Akturk U, Seren M. Efficacy of rotational thrombectomy on the mortality of patients with massive and submassive pulmonary embolism. *J Card Surg.* 2015;30:324–32.

J.C. Castro-Garay, A. Uribarri*, I. Cruz-González, J. Martín-Moreiras, P.L. Sánchez

Servicio de Cardiología, Complejo Asistencial Universitario de Salamanca – Instituto de Investigación Biomédica de Salamanca, Salamanca, Spain

* Corresponding author.

E-mail address: auribarrig@gmail.com (A. Uribarri).

19 June 2016 10 July 2016

2173-5727/

© 2016 Elsevier España, S.L.U. and SEMICYUC. All rights reserved.

Progressive encephalopathy associated with nutritional deficiencies: Identifying patients at high risk for developing thiamine deficiency[☆]



Encefalopatía progresiva de origen carencial: identificar a los pacientes en riesgo de déficit de tiamina

[☆] Please cite this article as: Freire-Aragón MD, Fernández Delgado E, Carbajal-Guerrero J, Ribera-Rubiales G. Encefalopatía progresiva de origen carencial: identificar a los pacientes en riesgo de déficit de tiamina. *Med Intensiva.* 2017;41:439–441.

Dear Editor,

Wernicke's encephalopathy (WE) is a neurological entity due to thiamine deficiency that is classically associated with alcoholism although it may be present in non-alcoholics too.^{1,2} Its estimated prevalence is 0.4–2.8 per cent, but the coexistence of conditions of the same profile and the inaccessibility to diagnostic tests make the real incidence of this condition unknown.¹ Due to the severity and innocuousness of the treatment, the immediate administration of thiamine is recommended and it stops the progression of the disease and favours recovery.^{1,3} In order to prevent the occurrence of WE, we should know all those therapeutic situations and interventions where there is an increased metabolic demand that may lead to its deficiency.³ In view of this situation, we hereby present the case of one female patient with thiamine deficient-encephalopathy of rapid progression.

It is the case of a fifty-seven year old female with a history of duodenal bulbitis only. She had been experiencing compartmental alterations, vertigo, vomit, abdominal pain, and food intolerance for two (2) months that finally lead to acute renal failure, and severe metabolic acidosis that ended up with the patient being admitted to her reference hospital. At admission, symptomatic treatment and fluid therapy was initiated and renal function was recovered, but the persistence of the patient's digestive clinical manifestations recommended the initiation of parenteral nutrition (PN). One abdominal computed tomography (CT) scan was performed together with one digestive endoscopy, and several other serological and microbiological tests—all of them with anodyne results. In a progressive way, the behavioural changes became more and more significant and deteriorated the patient's level of consciousness until she scored 9–10 points in the Glasgow Coma Scale (GCS). One cranial CT scan and one lumbar puncture were performed and both were not pathological. Given the diagnostic uncertainty, the patient was transferred to our unit specialised in the management of neurocritical conditions.

Upon arrival the patient scored 8–12 points in the GCS. Her only physical focality was the inexistence of oculocephalic reflexes. Given the patient's clinical manifestations, chronopathology, and negative tests, the initial suspicion included the possibility of WE and the patient was administered IV thiamine; 24–48 h later the patient improved significantly and was bradypsychic, yet aware and collaborative. One cranial MRI was performed that confirmed the presence of thalamic, periaqueductal hyperintense, symmetrical lesions, mammillary bodies and quadrigeminal tubercles—all typical findings of WE and the patient was discharged early. Yet despite the patient's initial recovery, in the posterior follow-ups she showed sequelae noticeable in her gait and memory.

There are multiple publications on WE. The classical clinical triad includes the alteration of the mental state,

oculomotor signs and cerebellous alterations.^{1–3} The coexistence of these symptoms is variable, but the series coincide in that this entity is more common in alcoholic patients than in non-alcoholic patients, in whom the course of the disease is faster and more fatal, making its detection harder.^{1,3} The diagnostic sensitivity of the triad is limited (20 per cent), but it improves when nutritional deficit is included: if 2 out of these 4 symptoms are present, we may detect up to 85 per cent,⁴ coexisting all in our case. However, occasionally it is done by exclusion.³

The thiamine reserves are limited and we need a regular supply in our food.⁵ It is hydrolysed in the stomach and its local absorption is saturable, which is why its oral administration is not effective if we want to increase its levels rapidly,^{4,5} being the parenteral administration essential.^{1,3,5} Its function is being the cofactor of enzymes of the metabolism of carbohydrates that are essential in the production of cerebral energy, and its deficit^{3,5} causes neurotoxicity, and neuronal death.

If there is insufficient intake or incremental losses, its deposits are depleted in 3–4 weeks.⁵ Intake after prolonged fasting and/or the administration of glucose solutions increases the needs, which is why it is recommended to administer it before or together with glucose solutions.³

Its leading cause is alcoholism although it may be due to malnutrition, losses (vomits, dialysis), increased requirements (severe sepsis, burned) and genetic metabolic disorders,^{1,2} being the coexistence of various of these factors the ideal scenario for its rapid progression. In our case, prolonged hyperemesis was initially responsible, although the introduction of PN increased the metabolic demand in one patient in whom the deficit was unnoticed, which worsened the progression. Multivitamin supplements usually include between 3 and 3.5 mg of thiamine. Based on the actual guidelines, patients at risk who initiate PN should receive between 100 and 300 mg/day during the first three (3) days,^{1,3,6} especially patients with malnutrition.⁷

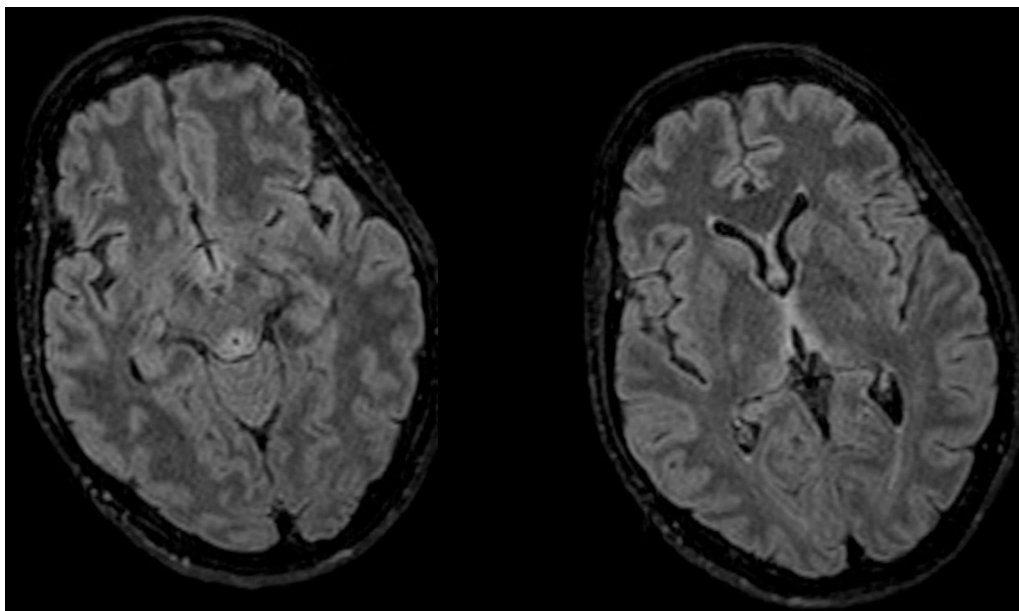


Figure 1 Axial FLAIR MRI sequence: hyperintense lesions at periaqueductal level and around the third ventricle confirmed—all of them typical of Wernicke's encephalopathy.

However, compliance is poor. There is no general consensus on dose in WE.

Diagnosis is clinical even though there are tests for assessment and support. The cerebral nuclear magnetic resonance is the modality of choice^{1,3} thanks to its specificity (93 per cent) and positive predictive value (89 per cent) being the CT scan discarded due to its low sensitivity. The typical lesions are symmetrical and they affect the medial thalamus, the mammillary bodies, the tectal plate, and the periaqueductal region⁸ (Fig. 1). The thiamine deficiency may be analysed using high resolution liquid chromatography or from the activity displayed by erythrocyte transketolase^{1,3,7} where it acts as a cofactor. In our patient we were unable to obtain any levels due to an extraction mistake that made our sample useless. The fast recovery after the administration is the best diagnosis as it occurred with our patient.

Vitamins and other coexisting deficits should be supplemented. Magnesium is an important cofactor of the thiamine pathways. One recent study confirmed a significant increase of the activity of erythrocyte transketolase in the group treated with magnesium and thiamine compared to the group that received thiamine only, which means that the administration of magnesium plus thiamine may speed up the recovery of metabolic pathways.^{9,10}

The prognosis of WE is closely associated with the precocity of diagnosis and treatment.^{1,3,5} Its low cost and innocuousness support its early administration. The residual deficits are common as it occurred with the case presented here.

We would like to finish with a thought. The diagnosis of WE is clinical and the response to treatment with thiamine is the best test there is. We should always take it into consideration with non-related neurological manifestations in patients with risk factors (increased metabolic demand, or deficits). When in clinical suspicion, we should supplement with IV thiamine, since it has a good profile of safety and innocuousness that may prevent and even stop the devastating effects of WE.

Funding

The authors declare that they have received no funding while conducting this study.

References

- Galvin R, Bråthen G, Ivashynka A, Hillbom M, Tanasescu R, Leone MA. EFNS guidelines for diagnosis, therapy and prevention of Wernicke encephalopathy. *Eur J Neurol*. 2010;17:1408–18.
- Scalzo S, Bowden S, Ambrose M, Whelan G, Cook M. Wernicke-Korsakoff syndrome not related to alcohol use: a systematic review. *J Neurol Neurosurg Psychiatry*. 2015;86:1362–8.
- Sechi G, Serra A. Wernicke's encephalopathy: new clinical settings and recent advances in diagnosis and management. *Lancet Neurol*. 2007;6:442–55.
- Caine D, Halliday GM, Kril JJ, Harper CG. Operational criteria for the classification of chronic alcoholics: identification of Wernicke's encephalopathy. *J Neurol Neurosurg Psychiatry*. 1997;62:51–60.
- Thomson AG, Marshall EJ. Wernicke's encephalopathy: role of thiamine. *Pract Gastroenterol*. 2009;33:21–30.
- Singer P, Berger MM, van den Berghe G, Biolo G, Calder P, Forbes A, et al., ESPEN. ESPEN guidelines on parenteral nutrition: intensive care. *Clin Nutr*. 2009;28:387–400.
- Vanek VW, Borum P, Buchman A, Fessler TA, Howard L, Jeejeebhoy K, et al., ASPEN. Position paper: Recommendations for changes in commercially available parenteral multivitamin and multi-trace element products. *Nutr Clin Pract*. 2012;27:440–91.
- Zuccoli G, Pipitone N. Neuroimaging findings in acute Wernicke's encephalopathy: review of the literature. *Am J Roentgenol*. 2009;192:501–8.
- Dingwall KM, Delima JF, Gent D, Batey RG. Hypomagnesaemia and its potential impact on thiamine utilisation in patients with alcohol misuse at the Alice Springs Hospital. *Drug Alcohol Rev*. 2015;34:323–8.
- Peake RW, Godber IM, Maguire D. The effect of magnesium administration on erythrocyte transketolase activity in alcoholic patients treated with thiamine. *Scott Med J*. 2013;58:139–42.

M.D. Freire-Aragón, E. Fernández Delgado*,
J. Carbajal-Guerrero, G. Ribera-Rubiales

*Unidad de Neurocríticos, Unidad de Cuidados Intensivos,
Hospital Universitario Virgen del Rocío, Sevilla, Spain*

* Corresponding author.

E-mail addresses: esperanzafernandezdelgado@gmail.com,
complejodewendy@gmail.com (E. Fernández Delgado).
2173-5727/

© 2016 Elsevier España, S.L.U. and SEMICYUC. All rights reserved.

Extracorporeal membrane oxygenation support for Takotsubo syndrome and long QT after cardiac surgery[☆]



SopORTE con oxigenación de membrana extracorpórea en un síndrome de Takotsubo y QT largo tras cirugía cardíaca

[☆] Please cite this article as: García-Delgado M, García-Huertas D, Navarrete-Sánchez I, Olivencia-Peña L, Garrido JM. SopORTE con oxigenación de membrana extracorpórea en un síndrome de Takotsubo y QT largo tras cirugía cardíaca. *Med Intensiva*. 2017;41:441–443.

Dear Editor,

Takotsubo syndrome is a type of cardiomyopathy characterized by transient left ventricular dysfunction associated to electrocardiographic changes similar to those of acute myocardial infarction, though without evidence of coronary disease, and with scanty altered myocardial enzyme levels. The syndrome is also known as transient apical dysfunction, "apical ballooning" or stress-induced cardiomyopathy, since it generally affects postmenopausal women following some stressing event. The diagnostic criteria of Takotsubo syndrome are: acute electrocardiographic anomalies such as ST-segment elevation or T-wave inversion; the absence of obstructive coronary disease; akinesia or transient dyskinesia of the left ventricle; and the absence of traumatic brain injury, intracranial hemorrhage, pheochromocytoma,