



IMAGE IN INTENSIVE MEDICINE

Fulminant sepsis caused by *Clostridium perfringens*[☆]



Sepsis fulminante por *Clostridium perfringens*

A. Guridi Mugica^{a,*}, L. Marti Gelonch^b, R. Jimenez Agüero^b

^a Servicio de Medicina Intensiva, Hospital Universitario Donostia, Donostia-San Sebastián, Guipúzcoa, Spain

^b Servicio de Cirugía General, Hospital Universitario Donostia, Donostia-San Sebastián, Guipúzcoa, Spain

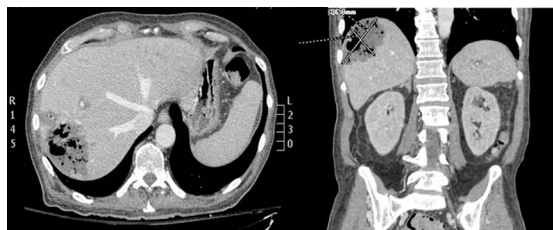

Figure 1

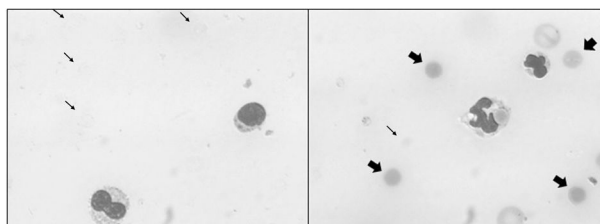


Figure 2

A 66-year-old male was admitted due to abdominal septic shock and a liver abscess identified by the CT scan (Fig. 1). The blood samples revealed advanced hemolysis, with the presence of erythrocyte ghosts (thin arrows) and spherocytes (thick arrows) (Fig. 2). The blood cultures proved positive for *Clostridium perfringens*. The clinical course was negative, leading to multiorgan dysfunction with progressive metabolic acidosis, anemization and thrombocytopenia. Treatment proved ineffective, and the patient died after three hours. Sepsis due to *C. perfringens* has a very poor prognosis if not detected early. The disorder should be suspected in the case of a septic patient with evidence of massive hemolysis, and blood cultures with gram staining of the blood smear are indicated. Early empirical antibiotic treatment with penicillin and clindamycin should be started, and local debridement is to be performed.

[☆] Please cite this article as: Guridi Mugica A, Marti Gelonch L, Jimenez Agüero R. Sepsis fulminante por *Clostridium perfringens*. Med Intensiva. 2018;42:137.

* Corresponding author.

E-mail address: amalur.guridimugica@osakidetza.eus (A. Guridi Mugica).