



IMAGES IN INTENSIVE MEDICINE

Traumatic lung hernia[☆]

Hernia pulmonar traumática



M.D. Freire Aragón^{*}, I. Palacios García, V. Rivera Fernández

Unidad de Cuidados Intensivos, Hospital Universitario Virgen del Rocío, Sevilla, Spain

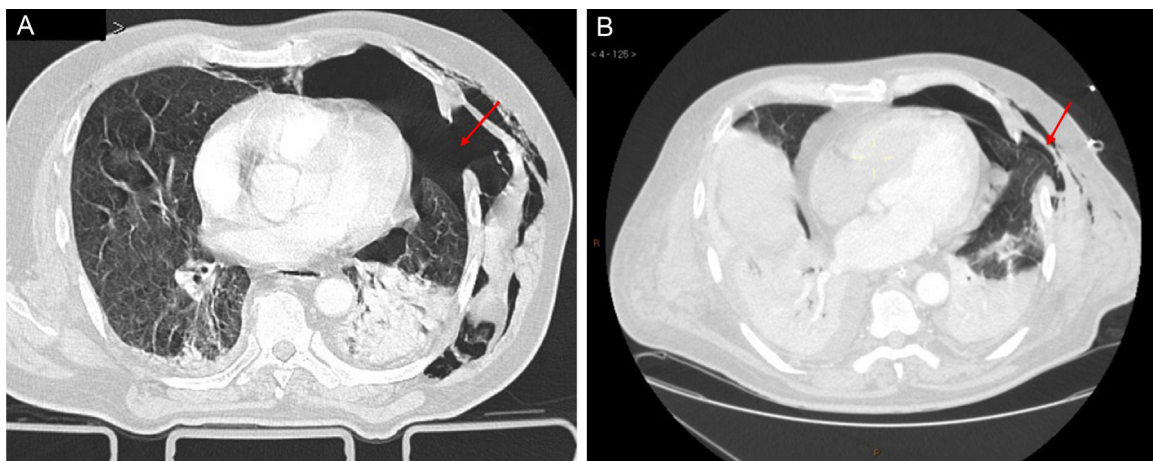


Figure 1

Seventy-three-year-old male with closed chest trauma. The CAT scan shows findings consistent with bilateral rib fractures, lung contusion, left pneumothorax and chest wall continuity defects associated with intercostal muscle tears (Fig. 1A). The insertion of chest drainage, and the initiation of mechanical ventilation with lung reexpansion confirmed, at 72 h, the herniation of one of the lingular segments (Fig. 1B). Surgical repair was conducted the ninth day after hospital admission with favorable outcome. Traumatic lung hernias are a rare entity. The chest CAT scan is the radiological imaging modality of choice used to confirm the lesion, and provides information about the hernial sac, the amplitude of the wall defect, and the involvement of pulmonary tissue.

[☆] Please cite this article as: Freire Aragón MD, Palacios García I, Rivera Fernández V. Hernia pulmonar traumática. Med Intensiva. 2018;42:e5.

^{*} Corresponding author.

E-mail address: lola.freire@ono.com (M.D. Freire Aragón).