



IMAGES IN INTENSIVE MEDICINE

Diagnosis of accidental foreign body[☆]

Diagnóstico de cuerpo extraño accidental



J. Sánchez Arguiano*, B. Suberviola Cañas, P. Escudero Acha

Servicio de Medicina Intensiva, Hospital Universitario Marqués de Valdecilla, Santander, Cantabria, Spain

Available online 15 February 2019

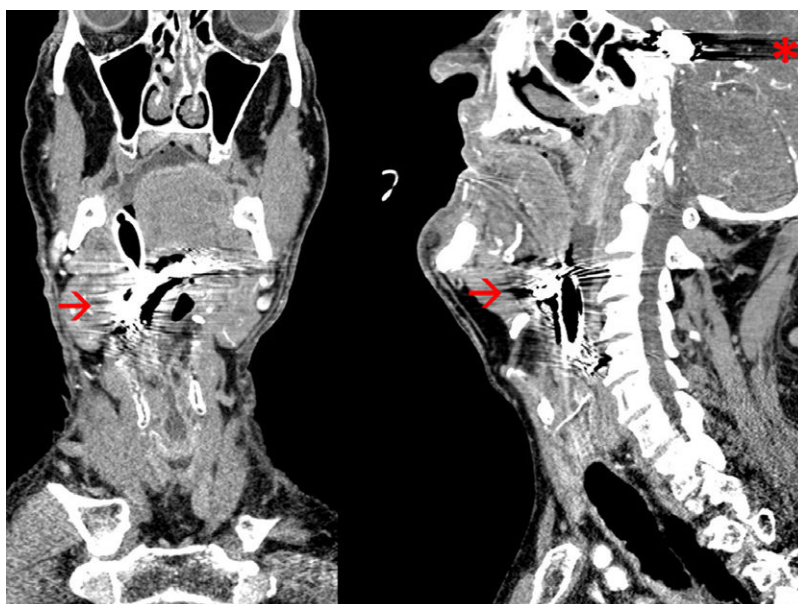


Figure 1 CAT scan cranial, coronal and sagittal slices with metallic artifacts.

We hereby present the case of a 72-year old male referred from the ER due to status epilepticus; the patient's past history showed one subarachnoid hemorrhage due to posterior communicating aneurysm. The image with the secondary artifact generated shows the embolization of that aneurysm back in 1995 (asterisk Fig. 1; sagittal slice). While the patient is being intubated in the emergency ward, he undergoes an eventless Cormack-Lehane Grade I laryngoscopy. The CAT scan conducted shows morphological changes and artifacts due to the embolization of the right posterior communicating artery aneurysm and an extensive area of right-hemisphere frontoparietal residual encephalomalacia due to an old intraparenchymal infarction; the CAT scan also shows the presence of radio-dense material located at oropharyngeal level (arrow Fig. 1; sagittal and coronal slice) and spreading caudally up to the middle part of the thyroid cartilage. During intubation suspicion abounds of the presence of one dental prosthesis given the morphology of the foreign body. It is eventually removed by the otolaryngology team.

[☆] Please cite this article as: Sánchez Arguiano J, Suberviola Cañas B, Escudero Acha P. Diagnóstico de cuerpo extraño accidental. Med Intensiva. 2019. <https://doi.org/10.1016/j.medin.2018.02.016>

* Corresponding author.

E-mail addresses: o414@humv.es, mjuncalsar@gmail.com (J. Sánchez Arguiano).