



## IMAGES IN INTENSIVE MEDICINE

### Recurrent subdural hematoma<sup>☆</sup>

### Hematoma subdural de repetición



J. Sánchez Arguiano\*, M. Arlabán Carpintero, Y. Peñasco Martín

Servicio de Medicina Intensiva, Hospital Universitario Marqués de Valdecilla, Santander, Cantabria, Spain

Available online 8 April 2019

A 66-year-old male was referred from a chronic patients center due to spontaneous lowered level of consciousness evidenced by a Glasgow coma score of 9. As relevant history, he presented a right acute subdural hematoma three months ago, secondary to an accidental fall, with surgical treatment (Fig. 1, arrows, old craniectomy). Mild motor sequelae remained, of which the patient was recovering in the mentioned center. During admission to the latter, he was also diagnosed with a left chronic subdural hematoma. A new CAT scan revealed a hyperintense signal (Fig. 1, asterisk) in the zone of the old chronic hematoma (Fig. 1, symbol +), suggestive of spontaneous acute hemorrhage with an important expansive effect. Emergency surgery was carried out, followed by admission to intensive care. This is a patient with repeat subdural hematomas in the absence of associated malformations, antecedents of hematological disorders and/or other predisposing factors.

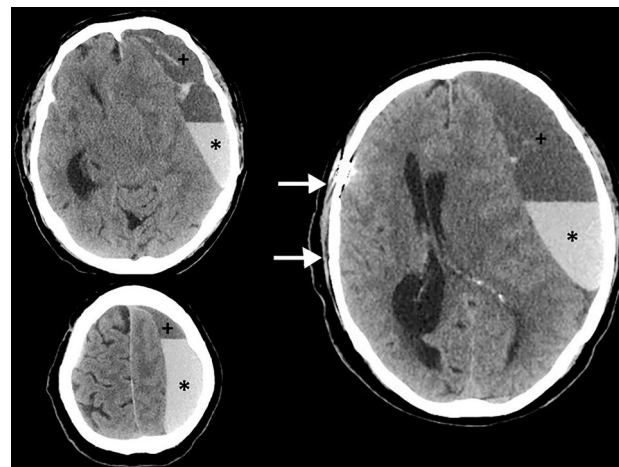


Figure 1

<sup>☆</sup> Please cite this article as: Sánchez Arguiano J, Arlabán Carpintero M, Peñasco Martín Y. Hematoma subdural de repetición. Med Intensiva. 2019;43:257.

\* Corresponding author.

E-mail addresses: [o414@humv.es](mailto:o414@humv.es), [mjuncalsar@gmail.com](mailto:mjuncalsar@gmail.com) (J. Sánchez Arguiano).