



IMAGES IN INTENSIVE MEDICINE

Tracheal rupture hidden by selective intubation of right bronchium[☆]



Rotura traqueal secundaria a intubación selectiva de bronquio derecho

N. Arriero Fernández^{a,*}, Z. Eguileor Marín^a, C. Marco Schulke^b

^a Servicio de Medicina Intensiva, Hospital Universitario de Guadalajara, Guadalajara, Spain

^b Servicio de Radiología, Hospital Universitario de Guadalajara, Guadalajara, Spain

Available online 27 April 2019

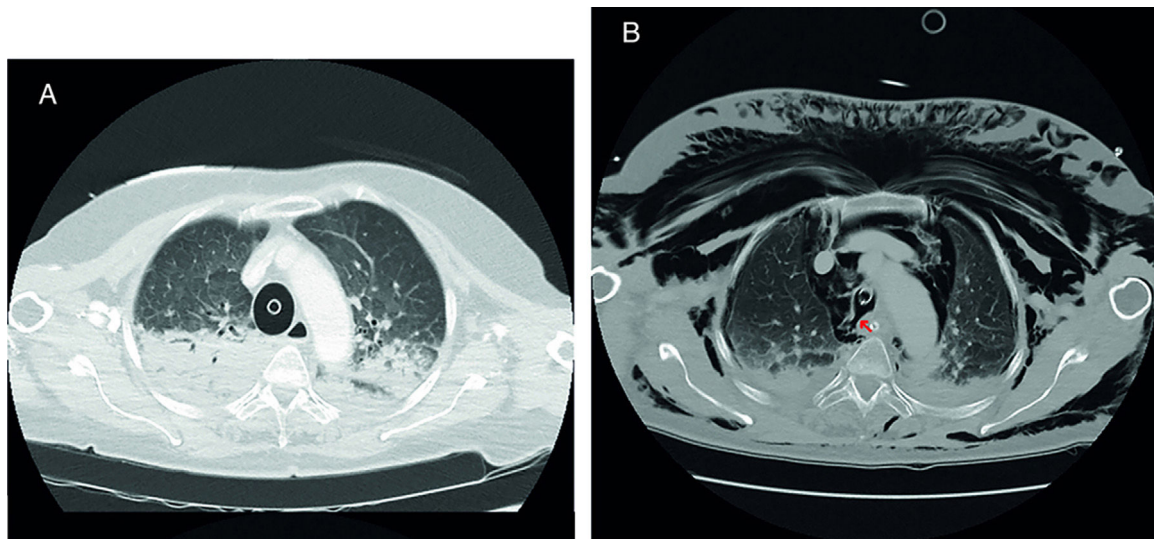


Figure 1 (A) Initial thoracic CT scan. (B) Thoracic CT scan at the ICU.

Seventy-year old woman without significant past medical history transferred to the hospital 35 min after performing advanced CPR maneuvers including orotracheal intubation (technique not described in the medical report) and use of mechanical chest compression device. One thoracic CT scan is conducted at the ER (A) followed by the selective intubation of the patient's right main bronchus. Upon arrival at the ICU, the endotracheal tube is removed followed by the sudden appearance of extensive subcutaneous emphysema. The thoracic CT scan (B) is repeated showing solution of

[☆] Please cite this article as: Arriero Fernández N, Eguileor Marín Z, Marco Schulke C. Rotura traqueal secundaria a intubación selectiva de bronquio derecho. *Med Intensiva*. 2019;43:327–328.

* Corresponding author.

E-mail address: noemi.arriero@gmail.com
(N. Arriero Fernández).

continuity at her right posterolateral tracheal wall due to tracheal tear that triggers bilateral apical pneumothorax, extensive pneumomediastinum, and subcutaneous emphysema (Fig. 1). Three (3) days after ICU admission, the patient died following limitation of life support treatment (LLST) due to severe anoxic encephalopathy.

Acknowledgements

We wish to thank the units of Intensive Medicine and Radiology at the Hospital de Guadalajara, Spain and, in particular, we wish to thank Dr. Marián Crespo, MD, and Dr. Jose Alberto Silva Obregón, MD for their unconditional support and dedication.