



## IMAGE IN INTENSIVE MEDICINE

### Mobile thrombus in right atrium during cannulation of veno-venous extracorporeal membrane oxygenation



### Trombo móvil en la aurícula derecha durante la canulación de una membrana de oxigenación extracorpórea veno-venosa

E. Rodríguez-Ruiz<sup>a,b,\*</sup>, A. López-Lago<sup>a,b</sup>, M. Álvarez Barredo<sup>c</sup>

<sup>a</sup> Intensive Care Medicine Department, University Clinical Hospital of Santiago de Compostela, SERGAS, Spain

<sup>b</sup> University of Santiago de Compostela, Santiago de Compostela, A Coruña, Spain

<sup>c</sup> Cardiology Department, University Clinical Hospital of Santiago de Compostela, Spain

A 44-year-old man was admitted to our ICU due to thoracic trauma with associated bilateral pulmonary contusion. He developed severe refractory respiratory failure ( $\text{PaO}_2/\text{FiO}_2 < 100$ ) and hemodynamic instability secondary to hypoxemia. Due to the inability to oxygenate the patient, it was decided to begin with veno-venous ECMO therapy. During cannulation of the femoral vein, a large thrombus (white arrow) was observed in the right atrium passing through the tricuspid valve into the pulmonary artery (Fig. 1); suddenly, the patient suffered cardiac arrest in pulseless electrical activity (Fig. 2), requiring advanced CPR maneuvers, recovering spontaneous circulation once ECMO therapy begun (Video). He remained under ECMO for seven days, after which, it was withdrawn due to respiratory improvement. He presented full neurological recovery.

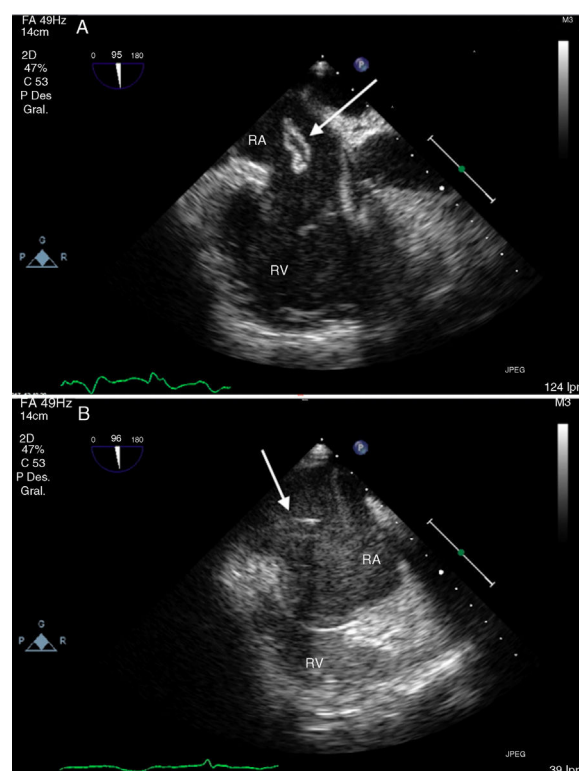


Figure 1

\* Corresponding author.

E-mail address: [r.ruizemilio@gmail.com](mailto:r.ruizemilio@gmail.com) (E. Rodríguez-Ruiz).

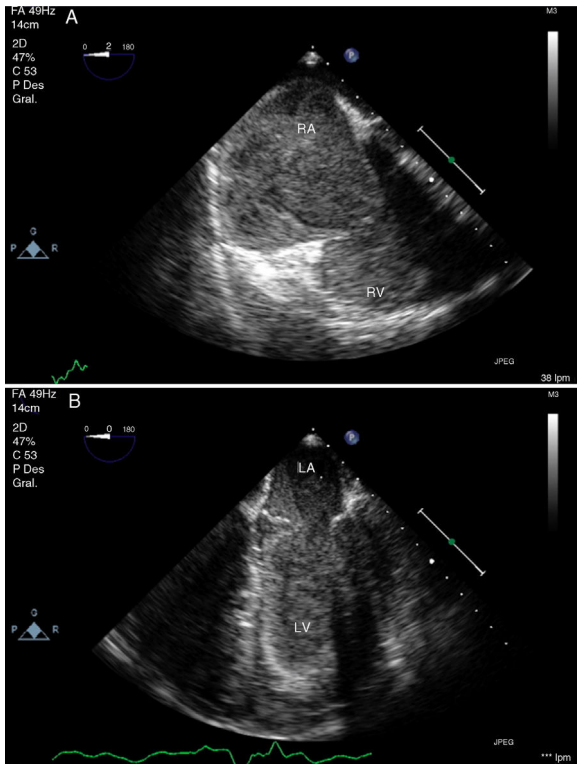


Figure 2

## Appendix A. Supplementary data

Supplementary data associated with this article can be found, in the online version, at [doi:10.1016/j.medin.2018.10.003](https://doi.org/10.1016/j.medin.2018.10.003)