



## IMAGES IN INTENSIVE MEDICINE

### “Snake eye” and “pencil-like” signs together with diaphragmatic paralysis in a patient with anterior spinal cord ischemia<sup>☆</sup>

### Signos de «ojo de serpiente» y «trazo de lápiz» junto con parálisis diafragmática en paciente con isquemia medular anterior

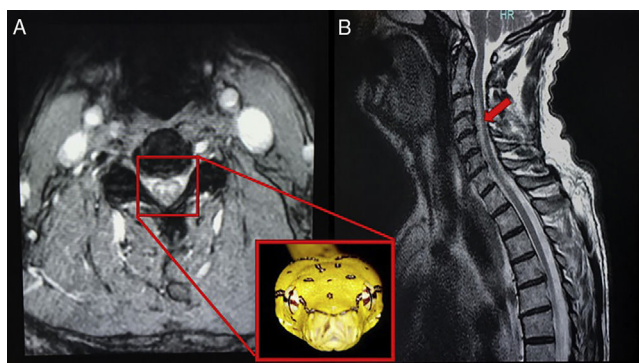


M.J. Martínez Tébar\*, A. Baeza Román, G. Julia Mejía Olmos

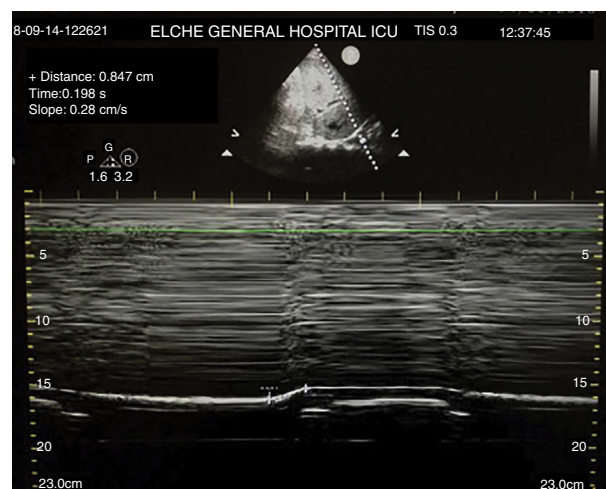
Servicio de Medicina Intensiva, Hospital General Universitario de Elche, Elche, Alicante, Spain

Available online 20 June 2019

Seventy-three-year-old male admitted due to a sudden episode of cervical pain after cervical flexion-extension while farming. The physical examination conducted showed clinical manifestations that were consistent with the syndrome of acute central cervical spinal cord injury and acute respiratory failure. The cervical magnetic resonance imaging conducted confirmed the diagnosis of anterior spinal cord ischemia showing the classical snake eye-image. The sagittal view showed pencil-like signal hyperintensity



**Figure 1** T2-weighted MRI images. The axial slice reveals one snake eye-lesion suggestive of spinal cord infarction. The sagittal slice shows pencil-like signal hyperintensity.



**Figure 2** Lung ultrasound of right hemithorax (mode M). It reveals the presence of one 0.8 mm-diaphragmatic excursion suggestive of right diaphragmatic paralysis.

(Fig. 1). This signal hyperintensity spread from C2–C3 towards C5–C6, with damage to the central and anterior spinal cord and degenerative changes at these levels. The physical examination was completed with a pulmonary ultrasound that revealed the presence of one 0.8 mm-right hemi-diaphragmatic excursion suggestive of right diaphragmatic paralysis (Fig. 2) following damage to the phrenic nerve (C3–C5). The spinal cord nerve is a rare entity that can be challenging when it comes to achieving diagnosis. One possible etiology is cervical arthrosis such as in this case due to compression of the spinal arteries by the osteophytes following prolonged postural changes.

<sup>☆</sup> Please cite this article as: Martínez Tébar MJ, Baeza Román A, Julia Mejía Olmos G. Signos de «ojo de serpiente» y «trazo de lápiz» junto con parálisis diafragmática en paciente con isquemia medular anterior. *Med Intensiva*. 2019;43:452.

\* Corresponding author.

E-mail address: [Martema3@gmail.com](mailto:Martema3@gmail.com) (M.J. Martínez Tébar).