



## IMAGES IN INTENSIVE MEDICINE

### Pulmonary vein stenosis after valve replacement surgery<sup>☆</sup>

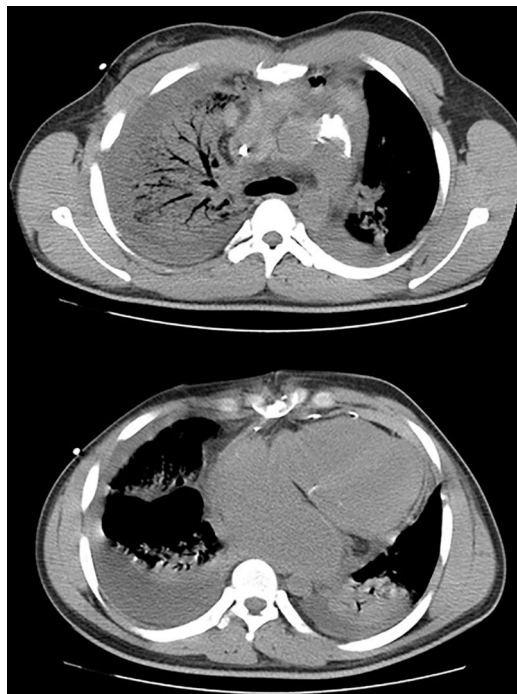### Estenosis de vena pulmonar tras cirugía de reemplazo valvular

M. Sevilla Martínez<sup>a,\*</sup>, A. Fernández Carmona<sup>a</sup>, S. Silvente Fernández<sup>b</sup>

<sup>a</sup> Unidad de Cuidados Intensivos, Hospital Universitario Virgen de las Nieves, Granada, Spain

<sup>b</sup> Unidad de Cuidados Intensivos, Hospital Vithas Parque San Antonio, Málaga, Spain

Available online 24 June 2019



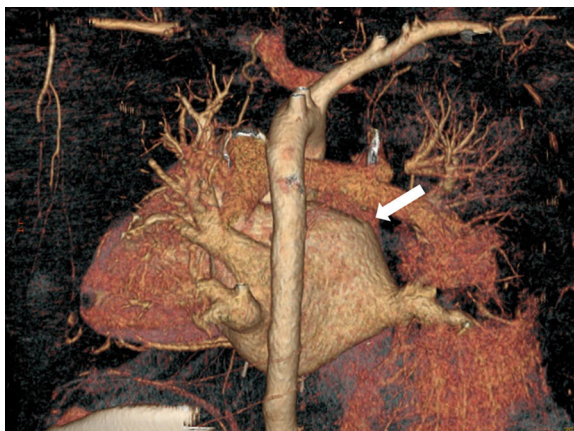
**Figure 1** Computed tomography scan: alveolar consolidation at the level of the right upper lobe of the lung and moderate mediastinal hematoma.

Acquired pulmonary vein stenosis after cardiovascular surgery is a rare yet not serious complication. We hereby present the case of one patient who developed a complete occlusion of the right upper pulmonary vein during

<sup>☆</sup> Please cite this article as: Sevilla Martínez M, Fernández Carmona A, Silvente Fernández S. Estenosis de vena pulmonar tras cirugía de reemplazo valvular. *Med Intensiva*. 2019;43:517–518.

\* Corresponding author.

E-mail address: [Sevillamartinezmaria@gmail.com](mailto:Sevillamartinezmaria@gmail.com) (M. Sevilla Martínez).



**Figure 2** Computed tomography scan reconstruction with contrast: collapse of the right pulmonary vein close to the junction of the right atrium (white arrow).

the immediate postoperative care following surgical mitral valve replacement. The diagnostic key was the development of respiratory failure and unilateral pulmonary edema. The axial chest computed tomography scan performed confirmed the presence of one alveolar consolidation at the level of the right upper lobe of the lung sparing the remaining pulmonary fields and one mediastinal hematoma (Fig. 1). This study was complemented with another study that used IV contrast and confirmed the collapse of the right pulmonary vein close to the junction of the right atrium (Fig. 2). Stenosis resolved after evacuating the mediastinal hematoma.

## Funding

This study received no funding whatsoever.