



## IMAGES IN INTENSIVE MEDICINE

### Massive hemoptysis as complication of catheterizing right with Swan-Ganz catheter<sup>☆</sup>



### Hemoptisis masiva como complicación de cateterismo derecho con catéter de Swan-Ganz

C. Amorós Verdú<sup>\*</sup>, A. Baeza Román, F.J. Coves Orts

*Servicio de Medicina Intensiva, Hospital General Universitario de Elche, Elche, Alicante, Spain*

Available online 11 November 2019

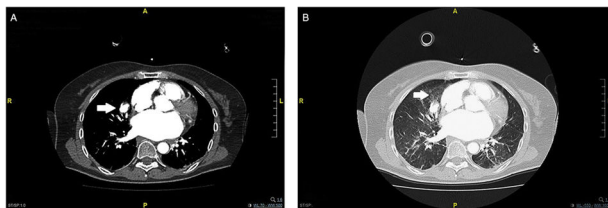


Figure 1

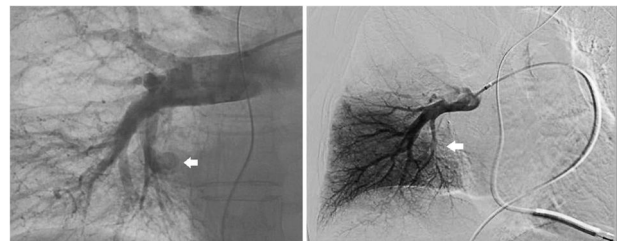


Figure 2

Ruptured pulmonary artery branches during right catheterization is a rare complication with mortality rates between 50% and 70%. This is the case of a 64-year-old woman with severe nonobstructive concentric hypertrophic cardiomyopathy. The patient is an ICD carrier and shows signs of dyspnea on minimal exertion and pulmonary hypertension on the echocardiography. She showed massive hemoptysis after balloon inflation of Swan-Ganz catheter during right side cardiac catheterization. After orotracheal intubation, the CT pulmonary angiogram (CTPA) performed reveals the presence of a pseudoaneurysm in the pulmonary artery branch at middle lobe level (Fig. 1A) and a locoregional alveolar hemorrhage (Fig. 1B). The arteriography confirms the presence of the pseudoaneurysm, and selective embolization is performed (Fig. 2). No extravasation is seen on the control CTPA performed 48 h later. The patient progression was good.

<sup>☆</sup> Please cite this article as: Amorós Verdú C, Baeza Román A, Coves Orts FJ. Hemoptisis masiva como complicación de cateterismo derecho con catéter de Swan-Ganz. *Med Intensiva*. 2019;43:589.

<sup>\*</sup> Corresponding author.

E-mail address: [amoros.cris@gmail.com](mailto:amoros.cris@gmail.com) (C. Amorós Verdú).