



IMAGES IN INTENSIVE MEDICINE

Vascular perforation by central venous catheter[☆] Perforación vascular por catéter venoso central



P. Escudero-Acha^{*}, A. González-Castro, C. Blanco Huelga

Servicio de Medicina Intensiva, Hospital Universitario Marqués de Valdecilla, Santander, Spain

Available online 10 November 2019




Figure 1 Image of drained pleural content.

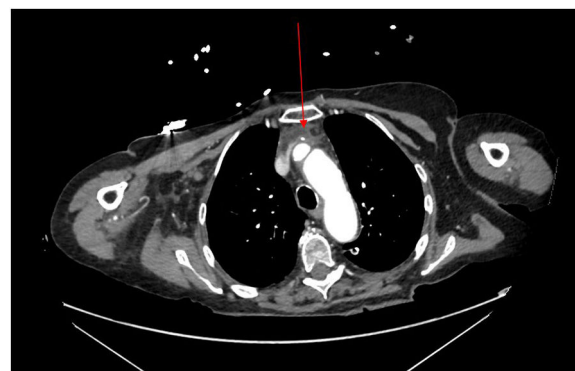


Figure 2 CT scan imaging showing the central venous catheter impacting the innominate vein.

This is the case of a 75-year-old woman admitted to the hospital floor unit due to Zenker's diverticulum, pending endoscopic therapy and requiring central venous catheter canalization of peripheral access for parenteral nutrition. Seven days later, she showed catheter-related bacteremia, the central venous catheter of peripheral access had to be removed and the jugular central venous catheter had to be canalized. Forty-eight hours later, the patient started showing progressive respiratory failure that required intubation and ICU admission. The thoracic ultrasound performed confirmed the presence of massive bilateral pleural effusion. It was drained using thoracic tubes that evacuated 3 l of white content with biochemical characteristics of parenteral nutrition (Fig. 1). The thoracic CT scan performed showed how the tip of the central venous catheter was impacting the innominate vein with adjacent collection (Fig. 2). Following instructions from Cardiovascular Surgery, the catheter was removed with close monitoring through the drainage tubes and the echocardiography to avoid cardiac tamponade. Forty-eight hours after admission the patient remained stable and was referred to the hospital floor unit.

[☆] Please cite this article as: Escudero-Acha P, González-Castro A, Blanco Huelga C. Perforación vascular por catéter venoso central. Med Intensiva. 2019;43:590.

^{*} Corresponding author.

E-mail address: patricia.escudero.acha@gmail.com (P. Escudero-Acha).