



IMAGES IN INTENSIVE MEDICINE

Lung overdistension monitorization by ultrasound in a patient with severe bronchopulmonary dysplasia[☆]



Utilidad de la ecografía pulmonar para monitorizar la sobredistensión grave en paciente con displasia broncopulmonar grave

A. Alonso-Ojembarrena

Unidad de Neonatología, Hospital Puerta del Mar, Cádiz, Spain

Available online 17 December 2019

A 4-month-old, ex-premature (24 weeks of pregnancy) patient with severe bronchopulmonary dysplasia on mechanical ventilation (pressure control mode with PIP 25 cmH₂O, PEEP 5.5 cmH₂O, respiratory frequency 35 rpm and FiO₂ 30%). On the reported day, the patient required FiO₂ of up to 50%, and the chest X-rays (Fig. 1) showed intense hyperinsufflation of the right hemithorax and the absence of the lung sliding sign at pulmonary ultrasound (Fig. 2). In view of the evolution of patients with bronchopulmonary dysplasia towards dynamic compression of the distal airway, we decided to progressively increase PEEP, without ultrasound improvement until PEEP 10 cmH₂O was reached; at this point pleural sliding was seen to reappear (Fig. 3) and the chest X-rays showed partial resolution of the overdistension (Fig. 4).

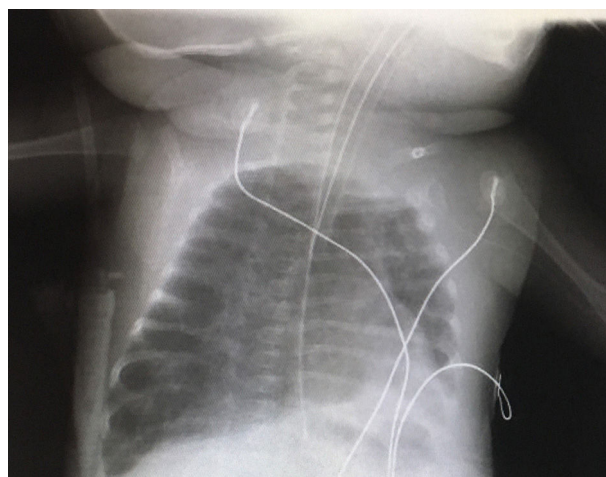


Figure 1

[☆] Please cite this article as: Alonso-Ojembarrena A. Utilidad de la ecografía pulmonar para monitorizar la sobredistensión grave en paciente con displasia broncopulmonar grave. Med Intensiva. 2020;44:131–132.

E-mail address: aaojemba@telefonica.net

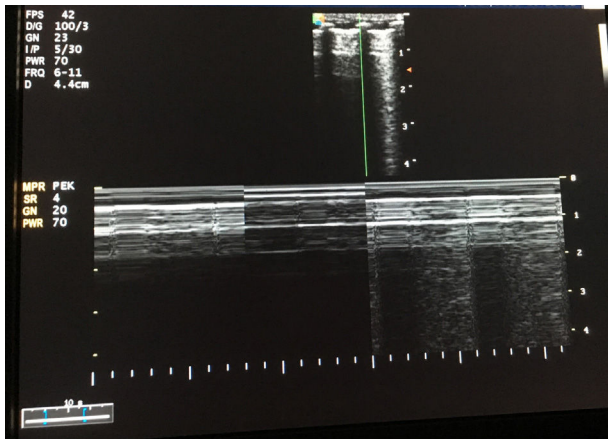


Figure 2

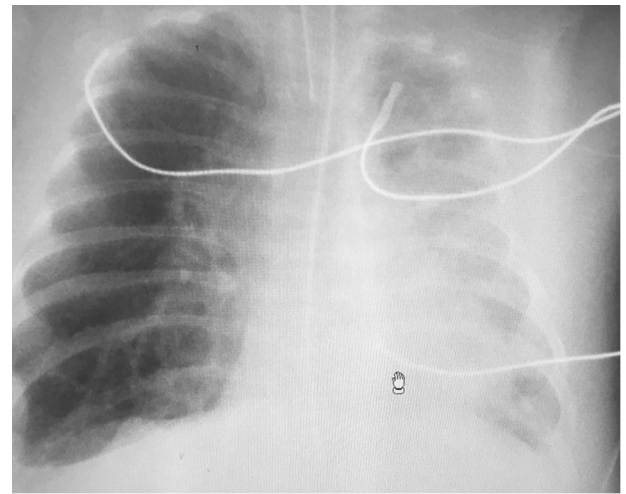


Figure 4

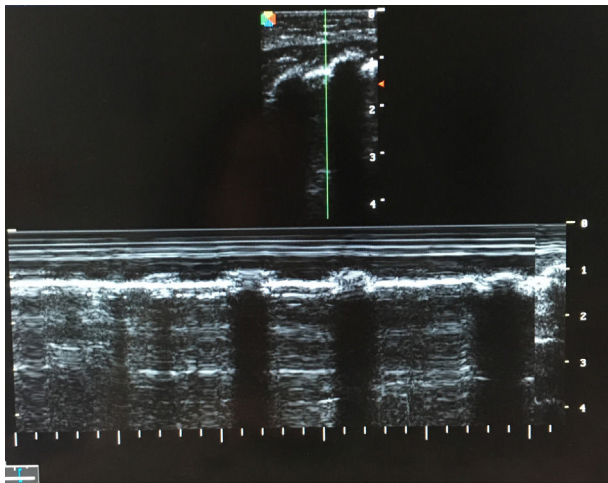


Figure 3

Funding

The author received no funding for the presentation of this clinical case.