



IMAGES IN INTENSIVE CARE MEDICINE

Gas embolism by central venous catheter[☆] Embolia gaseosa por catéter venoso central



R. Cantó Pérez*, M.L. Navarrete Rebollo, P.J. Fernández Arroyo

Servicio de Medicina Intensiva, Hospital Comarcal Marina Baja, Villajoyosa, Alicante, Spain

Available online 23 May 2020

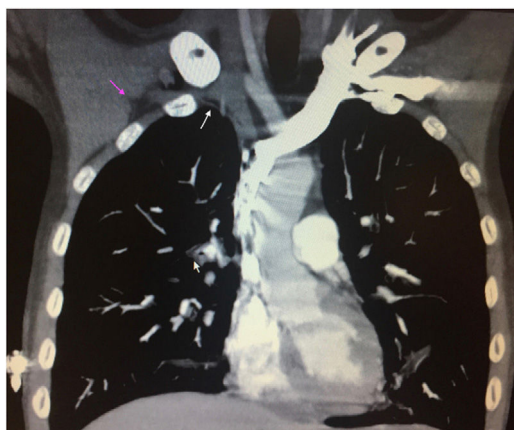

Figure 1

A 24-year-old male with a history of Crohn's disease was admitted due to pain in the right iliac fossa (RIF). The abdominal CAT scan revealed ileal perforation. Emergency right hemicolectomy and ileal resection were performed. On postoperative day 7, following withdrawal of the right subclavian central venous catheter (CVC), the patient suffered sudden onset dyspnea and right subcostal pain, desaturation and intense perspiration, with recovery following oxygen therapy. A few hours later, while walking, he experienced dizziness, sudden dyspnea with desaturation (to 50%) and tachypnea, Glasgow coma score: 6 (E: 4, M: 1 and V: 1), stiffness of the extremities and right conjugate deviation of the eyes. Pulmonary CAT angiography revealed subcutaneous emphysema at right infraclavicular level (purple arrow),

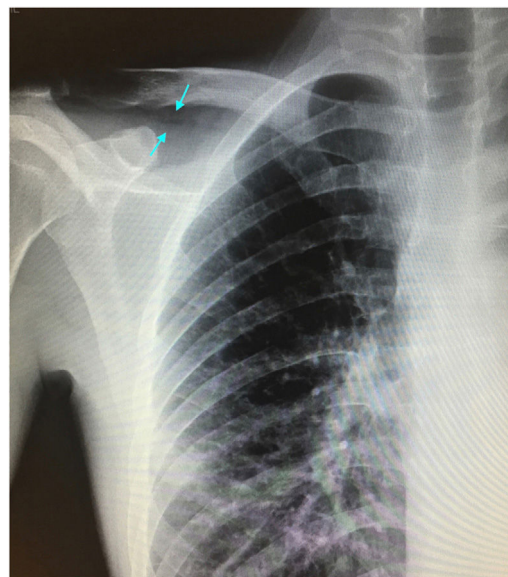


Figure 2

with air in the zone of the right subclavian vein, consistent with gas embolism (white arrow). No air was observed in the cardiac cavities or main pulmonary arteries (Fig. 1). The chest X-rays showed a radiolucent zone at right infraclavicular level (blue arrow) in the location of the right subclavian CVC (Fig. 2). The subsequent course proved favorable, with recovery of consciousness. Oxygen therapy with VMK reservoir was maintained, with the patient in the Trendelenburg position, and discharge to the ward took place after 48 h of ICU stay.

[☆] Please cite this article as: Cantó Pérez R, Navarrete Rebollo ML, Fernández Arroyo PJ. Embolia gaseosa por catéter venoso central. *Med Intensiva*. 2020;44:459.

* Corresponding author.

E-mail address: raquelcanto3@gmail.com (R. Cantó Pérez).

Acknowledgements

Thanks are due to all the staff members of the ICU of Villajoyosa (Alicante, Spain).