



IMAGES IN INTENSIVE MEDICINE

Coronary vasospasm: An infrequent cause of cardiopulmonary arrest[☆]

Vasoespasmo coronario: una causa infrecuente de parada cardiorrespiratoria

R. Ashbaugh Lavesiera^{a,*}, A.J. de Moneo González^a, I.T. Gómez Blazquez^b

^a Servicio de Medicina Intensiva, Hospital Universitario 12 Octubre, Madrid, Spain

^b Servicio de Cardiología, Unidad de Hemodinámica, Hospital Universitario 12 Octubre, Madrid, Spain

Available online 15 January 2021



This is the case of a 53-year-old male patient without any known cardiovascular risk factors who suffered a cardiopulmonary arrest at this working place. First asystole rhythm reported and electrical activity without a pulse. A total of 5 mg of adrenalin were administered. Pulse was recovered after 20 min performing advanced CPR maneuvers. The first ECG performed revealed the presence of ST-segment elevation on leads I, III, and aVF that resolved spontaneously.

At our hospital, a transient ST-segment elevation could be seen on leads V3, V4, and V5 (Fig. 1). The emergency coronary angiography performed showed diffuse spasm in the coronary arteries with subtotal stenosis (TIMI flow grade 1) in the proximal left anterior descending coronary artery (Fig. 2). The spasm resolved with intracoronary nitroglycerin (Fig. 3) with final TIMI flow grade 3 in the 3 major vessels. The patient progressed to severe hypoxic-ischemic encephalopathy.

[☆] Please cite this article as: Ashbaugh Lavesiera R, de Moneo González AJ, Gómez Blazquez IT. Vasoespasmo coronario: una causa infrecuente de parada cardiorrespiratoria. Med Clin (Barc). 2021;45:192–193.

* Corresponding author.

E-mail address: rosana.ashbaugh@salud.madrid.org (R. Ashbaugh Lavesiera).

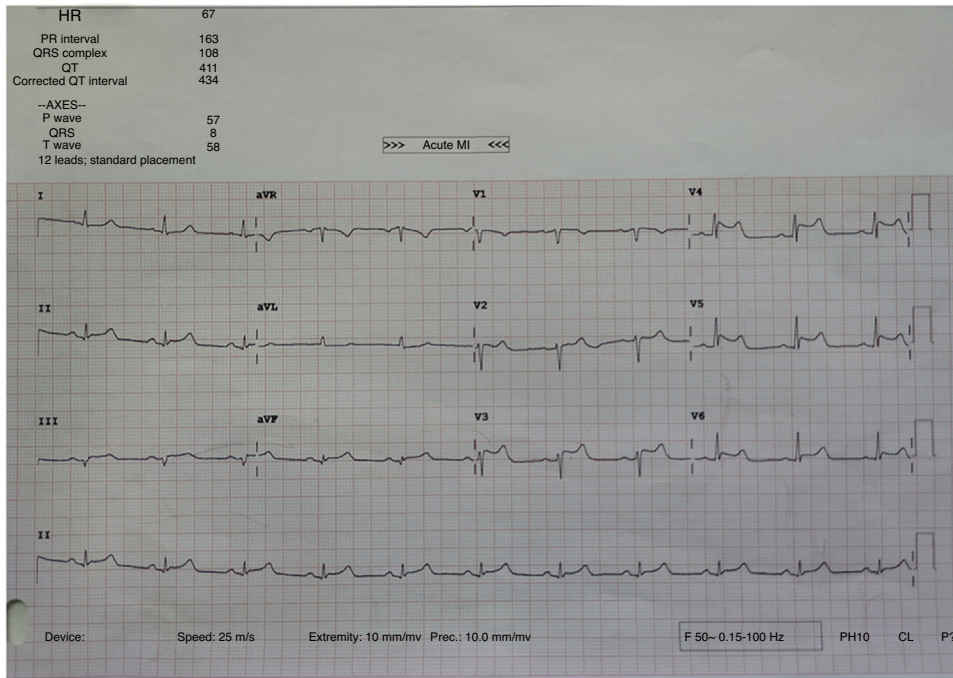


Fig. 1

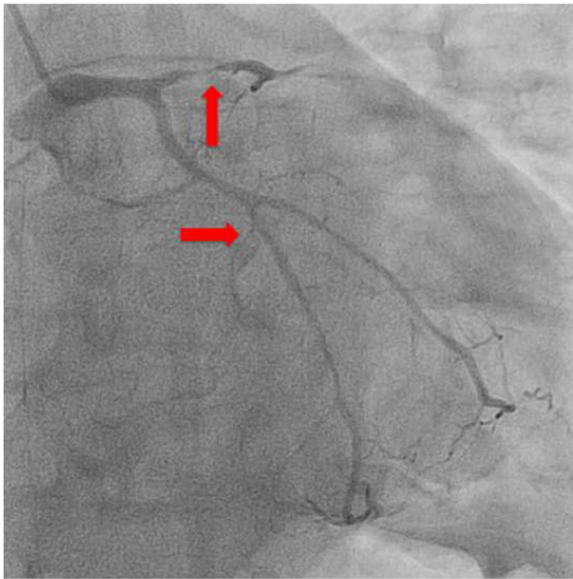


Fig. 2

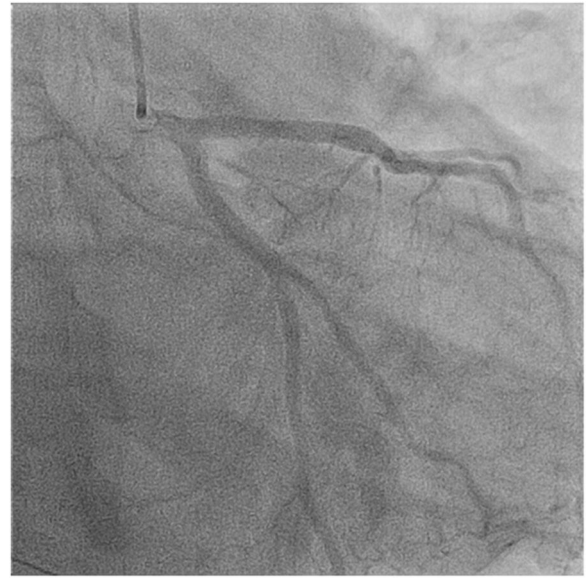

Fig. 3