



## IMAGES IN INTENSIVE MEDICINE

### Renobronchial abscess. Sepsis secondary to complicated renoureteral colic<sup>☆</sup>



### Absceso renobronquial. Sepsis secundaria a cólico renoureteral complicado

M. Pérez Torres\*, C. Arenas Mazarrota, M. Valdivia de la Fuente

Servicio de Medicina Intensiva, Hospital Universitario Puerta de Hierro-Majadahonda, Majadahonda, Madrid, Spain

Available online 4 March 2021

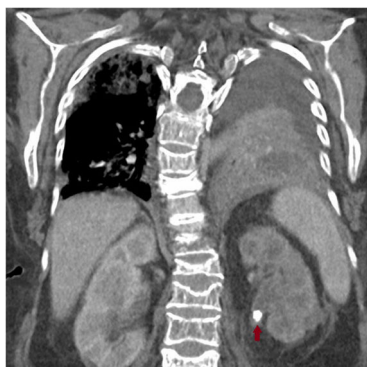

Figure 1 Left renoureteral colic.

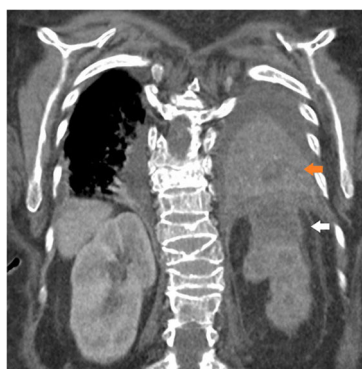

Figure 2 Renal abscess and abscessified pneumonia.

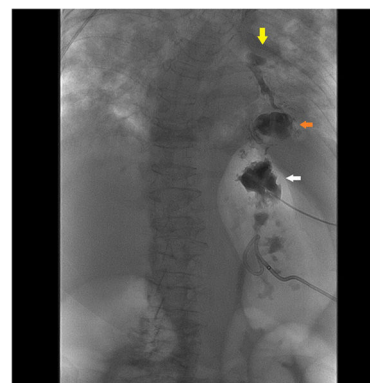


Figure 3 Computed tomography abscessogram.

We present the case of a 73-year-old woman transferred from the regional hospital with a diagnosis of urinary septic shock due to complicated renoureteral colic (Fig. 1, red arrow) with renal abscess (Fig. 2, white arrow) and abscessified pneumonia with left lower lobe affectation (Fig. 2, orange arrow) to control the focus of infection. After discussing the case with the interventional vascular radiology team, it was decided to perform a left percutaneous nephrostomy. Afterwards, the left upper renal pole abscess was drained through air content aspiration after the injection of contrast, the existence of a renobronchial fistula was confirmed. The computed tomography abscessogram performed (Fig. 3) revealed the presence

<sup>☆</sup> Please cite this article as: Pérez Torres M, Arenas Mazarrota C, Valdivia de la Fuente M. Absceso renobronquial. Sepsis secundaria a cólico renoureteral complicado. Med Intensiva. 2021;45:256–257.

\* Corresponding author.

E-mail address: [manupt07@gmail.com](mailto:manupt07@gmail.com) (M. Pérez Torres).

of contrast in the left upper renal pole (white arrow), left lower lung pole (orange arrow), bronchial tree, and left main bronchus (yellow arrow). Since the beginning the patient received broad-spectrum antibiotic therapy with negative microbial cultures.