



IMAGES IN INTENSIVE MEDICINE

Iatrogenic canalization of the right pulmonary artery after percutaneous chest tube insertion in a patient with pneumothorax[☆]

Canalización iatrogénica de la arteria pulmonar derecha con un drenaje pleural percutáneo en un paciente con neumotórax

M.T. Gómez Hernández^{a,*}, E.J. Martínez Santos^b, M.F. Jiménez López^a

^a Departamento de Cirugía Torácica, Hospital Universitario de Salamanca, Spain

^b Unidad de Cuidados Intensivos, Hospital Universitario de Salamanca, Spain

Received 28 February 2020; accepted 14 March 2020

Available online 17 June 2022

This is the case of a 78-year-old man treated with surgical aortic valve replacement. During the postoperative period, the patient developed right pneumothorax (Fig. 1A) that was treated with percutaneous pleural effusion using a 12-Fr chest tube. Right after insertion, the patient became hemodynamically unstable as confirmed by the leak of >500 mL of blood with pulsatile flow through the drainage within a few seconds. Immediate clamping was performed. An emergency thoracic x-ray confirmed the presence of drainage at right pulmonary artery level without associated hemothorax (Fig. 1B). Emergency surgery was planned to remove the drainage through direct visual control. The procedure

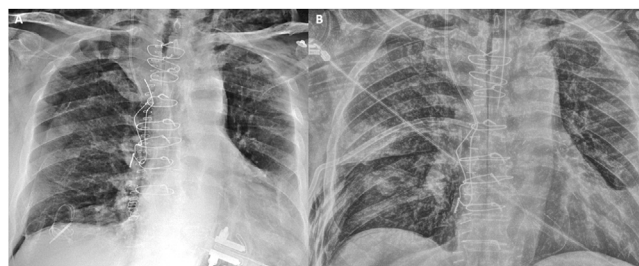


Figure 1

revealed no active bleeding after removing the drainage. However, suture was performed at arterial insertion level to prevent further bleeding.

[☆] Please cite this article as: Gómez Hernández MT, Martínez Santos EJ, Jiménez López MF. Canalización iatrogénica de la arteria pulmonar derecha con un drenaje pleural percutáneo en un paciente con neumotórax. *Med Intensiva*. 2022;46:486–487.

* Corresponding author.

E-mail address: mteresa.gomez.hernandez@gmail.com (M.T. Gómez Hernández).

Funding

None whatsoever.

Conflicts of interest

None reported.