



IMAGES IN INTENSIVE MEDICINE

Inferior vena cava obstruction due to complete thrombosis of the filtering device[☆]



Obstrucción de la vena cava inferior por trombosis completa del dispositivo de filtración

M. Iturbe-Rementería^{*}, J.M. Luciano-Sánchez, N. Ruiz-Cañas

Servicio de Medicina Intensiva, Hospital Santiago Apóstol, Vitoria-Gasteiz, Araba, Spain

Available online 23 June 2022

A 34-year-old male with no relevant disease history was admitted due to right subsegmental pulmonary thromboembolism, abdominal adenopathies suggestive of abdominal-peritoneal tuberculosis and necrotic-hemorrhagic pancreatitis. Orotracheal intubation proved necessary due to severe hypoxemic respiratory failure. An inferior vena cava filter was placed due to the contraindication of anticoagulation. Echo-doppler of the lower extremities evidenced bilateral deep vein thrombosis; intermittent pneumatic cuff compression was thus discarded. Targeted resuscitation with pulse contour analysis and transthoracic ultrasound was performed, though the clinical course proved catastrophic, with the development of refractory multiorgan dysfunction syndrome, obstructive shock, severe lactacidemia metabolic




Figure 1

[☆] Please cite this article as: Iturbe-Rementería M, Luciano-Sánchez JM, Ruiz-Cañas N. Obstrucción de la vena cava inferior por trombosis completa del dispositivo de filtración. *Med Intensiva*. 2022;46:542–543.

^{*} Corresponding author.

E-mail address: miguel.iturberementeria@osakidetza.eus (M. Iturbe-Rementería).

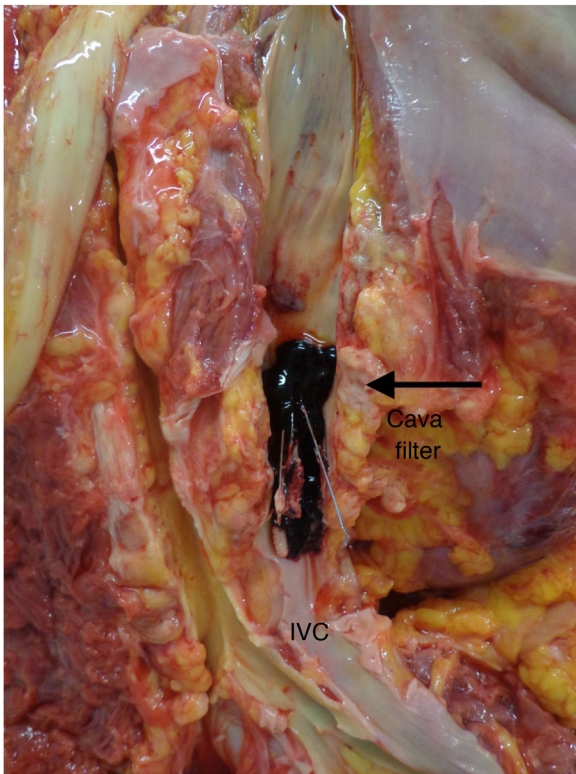


Figure 2

acidosis despite very high dose vasopressors, and oligoanuric renal failure. The necropsy study indicated “inferior vena cava obstruction secondary to complete thrombosis of the filtering device” (Figs. 1 and 2).